

# **Arthroscopic Rotator Cuff Repair – Evaluation and Surgical Technique Goals and Objectives**

## **Course Description**

“Arthroscopic Rotator Cuff Repair – Evaluation and Surgical Technique” is an online recorded video of a previously presented live CE webinar for rehabilitation professionals that examines surgical management of rotator cuff tears using arthroscopic techniques. This course includes a review of current literature relating to rotator cuff anatomy and pathophysiology, classification and diagnostics related to rotator cuff tears, management strategies, surgical techniques, and post-operative considerations.

## **Course Rationale**

The purpose of this course is to provide participants with contemporary information on arthroscopic rotator cuff repair with comparative analysis of pathogenesis and management techniques to understand rehabilitation implications and maximize outcomes based on current research.

## **Course Goals and Objectives**

Upon completion of this course, participants will be able to:

1. List and identify pertinent anatomical structures of the rotator cuff.
2. Recognize common pathologies related to the rotator cuff.
3. Define rotator cuff tear classification systems as they relate to location, size, shape, and tissue quality.
4. Distinguish clinical exam, imaging diagnostics, and conservative management for rotator cuff tears.
5. List the pre-operative and surgical preparation process for arthroscopic rotator cuff repair.
6. Recognize the common surgical instruments used during arthroscopic repair of a rotator cuff tear.
7. Outline the general steps of an arthroscopic rotator cuff tear repair procedure.
8. Identify some of the common variations in surgical technique for arthroscopic rotator cuff repair.
9. List surgical management alternatives to arthroscopic surgery for the treatment of rotator cuff tear.
10. Distinguish the surgical outcomes of arthroscopic rotator cuff repair including prognosis and surgical complications.

**Course Provider** – Innovative Educational Services

**Provider Contact Information** – [information@cheapceus.com](mailto:information@cheapceus.com)

**Course Instructor** - Sara Ziegele, PT, DPT, OCS

**Conflict of Interest** – No financial or non-financial conflict of interest exists for the presenter or provider of this course.

**Target Audience** – Athletic Trainers

**Course Educational Level** – This course is applicable for introductory learners.

**Course Prerequisites** – None

**Method of Instruction** – Distance Learning – Independent; Asynchronous online video-based home study

**Location** - [Cheapceus.com](http://Cheapceus.com)

**Date** – Continuously available on-demand

**Course Completion Requirements / Criteria for Issuance of CE Credits** – Completion of viewing of 3 hour recorded video, and a score of 70% correct or greater on the course post-test.

**Continuing Education Credits** – Three (3) contact hours / .3 AOTA CEUs

**Course Fee** - \$34.95

**Registration Information** –To register for this program, please go to: [Cheapceus.com](http://Cheapceus.com)

**Special Needs Requests** – Email: [information@cheapceus.com](mailto:information@cheapceus.com) or phone: 954-663-4101

**Cancellation by the Learner** – Learners may cancel their participation at any time and receive a full refund of all paid fees.

**Cancellation by the Provider** – Registrants will receive a full refund of all paid fees within 24 hours of provider cancellation.

**Complaint Resolution** – Please call 954-663-4101 (24 hours/day, 7 days/week) to speak with a live customer service agent. Our goal is to work with our customers to resolve all issues to the customer's satisfaction with just one phone call whenever possible.

**Refund Policy** - Unrestricted 100% refund upon request. The request for a refund by the learner shall be honored in full without penalty or other consideration of any kind. The request for a refund may be made by the learner at any time without limitations before, during, or after course participation.

## **Arthroscopic Rotator Cuff Repair – Evaluation and Surgical Technique Course Outline and Schedule**

Topic	Time
Anatomy of the rotator cuff	0:00-0:05
Epidemiology and pathophysiology of rotator cuff tears	0:06-0:15
Classification systems for rotator cuff tears	0:16-0:30
Clinical exam	0:31-0:35
Imaging	0:36-0:50
Clinical Applications	0:51-1:00
Conservative management strategies for rotator cuff tear	1:01-1:10
Arthroscopic rotator cuff repair indications and contraindications	1:11-1:20
Patient positioning	1:21-1:30
Anesthesia	1:31-1:35
Surgical instruments	1:36-1:45
Portal site placement	1:46-1:50
Clinical Applications	1:51-2:00
Exposing the rotator cuff	2:01-2:05
Mobilizing the rotator cuff	2:06-2:10
Placement of suture anchors	2:11-2:15
Passing and tying the sutures	2:16-2:20
Variations in surgical technique	2:21-2:30
Alternative surgical management strategies for rotator cuff tear	2:31-2:35
Surgical outcomes	2:36-2:50
Clinical Applications	2:51-3:00

# Arthroscopic Rotator Cuff Repair: Evaluation and Surgical Technique

Live Interactive Webinar

Presented By: Sara Ziegele, PT, DPT, OCS

Contact: sara@bepreemptive.com

1

2

## Course Rationale

- The purpose of this course is to provide participants with contemporary information on arthroscopic rotator cuff repair with comparative analysis of pathogenesis and management techniques to understand rehabilitation implications and maximize outcomes based on current research

Copyright Sara Ziegele

3

## Goals & Objectives

Upon completion of this course, participants will be able to:

1. List and identify pertinent anatomical structures of the rotator cuff.
2. Recognize common pathologies related to the rotator cuff.
3. Define rotator cuff tear classification systems as they relate to location, size, shape, and tissue quality.
4. Distinguish clinical exam, imaging diagnostics, and conservative management for rotator cuff tears.
5. List the pre-operative and surgical preparation process for arthroscopic rotator cuff repair.
6. Recognize the common surgical instruments used during arthroscopic repair of a rotator cuff tear.
7. Outline the general steps of an arthroscopic rotator cuff tear repair procedure.
8. Identify some of the common variations in surgical technique for arthroscopic rotator cuff repair.
9. List surgical management alternatives to arthroscopic surgery for the treatment of rotator cuff tear.
10. Distinguish the surgical outcomes of arthroscopic rotator cuff repair including prognosis and surgical complications.

Copyright Sara Ziegele

4

4

## Disclaimer

- Application of concepts presented in this webinar is at the discretion of the individual participant in accordance with federal, state, and professional regulations
- No conflict of interest exists for the presenter or provider of this course

Copyright Sara Ziegele

5

Topic	Time
Anatomy of the rotator cuff	0:00-0:05
Epidemiology and pathophysiology of rotator cuff tears	0:06-0:15
Classification systems for rotator cuff tears	0:16-0:30
Clinical exam	0:31-0:35
Imaging	0:36-0:50
<b>Interactive Discussion of Clinical Applications</b>	<b>0:51-1:00</b>
Conservative management strategies for rotator cuff tear	1:01-1:10
Arthroscopic rotator cuff repair indications and contraindications	1:11-1:20
Patient positioning	1:21-1:30
Anesthesia	1:31-1:35
Surgical instruments	1:36-1:45
Portal site placement	1:46-1:50
<b>Interactive Discussion of Clinical Applications</b>	<b>1:51-2:00</b>
Exposing the rotator cuff	2:01-2:05
Mobilizing the rotator cuff	2:06-2:10
Placement of suture anchors	2:11-2:15
Passing and tying the sutures	2:16-2:20
Variations in surgical technique	2:21-2:30
Alternative surgical management strategies for rotator cuff tear	2:31-2:35
Surgical outcomes	2:36-2:50
<b>Interactive Discussion of Clinical Applications</b>	<b>2:51-3:00</b>

Copyright Sara Ziegele

6

## Anatomy of the Glenohumeral Joint

- Glenohumeral joint has extensive multidirectional mobility
- Largely stabilized by rotator cuff (RTC)
- RTC is a continuous structure wrapping over the anterior, superior, and posterior regions of the humeral head

Image: [Creative Commons Attribution 4.0 International License](https://creativecommons.org/licenses/by-sa/4.0/) OpenStax College <https://openstax.org/books/anatomy-and-physiology-2e/pages/9-6-anatomy-of-selected-synovial-joints>  
Zoga, A. C., Kamel, S. I., Hynes, J. P., Kavanagh, E. C., O'Connor, P. J., & Forster, B. B. (2021). The evolving roles of MRI and ultrasound in first-line imaging of rotator cuff injuries. *American Journal of Roentgenology*, 217(6), 1360-1400.

Copyright Sara Ziegele

7

7

## Anatomy of the RTC

- Consists of 4 tendons:
  - Supraspinatus
  - Infraspinatus
  - Subscapularis
  - Teres minor

Image: [Creative Commons Attribution-ShareAlike 4.0 International License](https://creativecommons.org/licenses/by-sa/4.0/) InjuryMap <https://www.injurymap.com/free-human-anatomy-illustrations>  
Zoga, A. C., Kamel, S. I., Hynes, J. P., Kavanagh, E. C., O'Connor, P. J., & Forster, B. B. (2021). The evolving roles of MRI and ultrasound in first-line imaging of rotator cuff injuries. *American Journal of Roentgenology*, 217(6), 1360-1400.

Copyright Sara Ziegele

8

8

## Anatomy of the Scapula

- Origins for the RTC

Image: public domain T. W. P. Lawrence [https://commons.wikimedia.org/wiki/File:Quain%27s\\_elements\\_of\\_anatomy\\_\(1891\)\\_Vol2\\_Part1\\_Pic\\_088.png](https://commons.wikimedia.org/wiki/File:Quain%27s_elements_of_anatomy_(1891)_Vol2_Part1_Pic_088.png)  
Image: public domain T. W. P. Lawrence [https://commons.wikimedia.org/wiki/File:Quain%27s\\_elements\\_of\\_anatomy\\_\(1891\)\\_Vol2\\_Part1\\_Fig\\_087.png](https://commons.wikimedia.org/wiki/File:Quain%27s_elements_of_anatomy_(1891)_Vol2_Part1_Fig_087.png)

Copyright Sara Ziegele

9

9

## Anatomy of the Proximal Humerus

- Insertions of the RTC:
  - Greater tuberosity: supraspinatus, infraspinatus, and teres minor
  - Lesser tuberosity: subscapularis

Image: public domain BDB <https://commons.wikimedia.org/wiki/File:HumerusFront.png>

Copyright Sara Ziegele

10

10

## Anatomy of the RTC

- Supraspinatus
  - Function: initiates and assists deltoid with shoulder ABD, stabilization
  - Innervation: suprascapular nerve

Image: [Creative Commons Attribution-ShareAlike 4.0 International License](https://creativecommons.org/licenses/by-sa/4.0/) [https://commons.wikimedia.org/wiki/File:Supraspinatus\\_muscle\\_top.png](https://commons.wikimedia.org/wiki/File:Supraspinatus_muscle_top.png)

Copyright Sara Ziegele

11

11

## Anatomy of the RTC

- Infraspinatus
  - Function: primary ER of the shoulder, contributes to ext, stabilization
  - Innervation: suprascapular nerve

Image: [Creative Commons Attribution-ShareAlike 4.0 International License](https://creativecommons.org/licenses/by-sa/4.0/) [https://commons.wikimedia.org/wiki/File:Infraspinatus\\_muscle\\_back2.png](https://commons.wikimedia.org/wiki/File:Infraspinatus_muscle_back2.png)

Copyright Sara Ziegele

12

12

## Anatomy of the RTC

- Teres minor
  - Function: contributes to ER, extension, adduction, stabilization
  - Innervation: axillary nerve

Image: [Creative Commons Attribution-Share Alike 2.1 Japan](https://commons.wikimedia.org/wiki/File:Teres_minor_muscle_hack2.png) Anatomography [https://commons.wikimedia.org/wiki/File:Teres\\_minor\\_muscle\\_hack2.png](https://commons.wikimedia.org/wiki/File:Teres_minor_muscle_hack2.png)

Copyright Sara Ziegale

13

13

## Anatomy of the RTC

- Subscapularis
  - Function: primary IR, contributes to ADD, ext, stabilization
  - Innervation: upper and lower subscapular nerves

Image: [Creative Commons Attribution-Share Alike 2.1 Japan](https://commons.wikimedia.org/wiki/File:Subscapularis_muscle_frontal2.png) Anatomography [https://commons.wikimedia.org/wiki/File:Subscapularis\\_muscle\\_frontal2.png](https://commons.wikimedia.org/wiki/File:Subscapularis_muscle_frontal2.png)

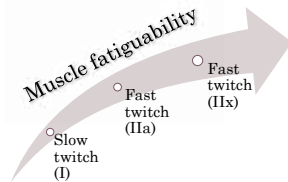
Copyright Sara Ziegale

14

14

## Anatomy of the RTC

- Muscle fiber type
  - RTC show heterogeneous makeup: 44% type I



Copyright Sara Ziegale

15

15

## Anatomy of the RTC

- Tendon composition
  - Water (55% of wet weight)
  - Type I collagen (85% of dry weight)
  - Other types of collagen, proteoglycans, cells

Image: [Creative Commons Attribution-Share Alike 3.0 Unported Nevit Dilmien](https://commons.wikimedia.org/wiki/File:18kv_collagen_02.png) [https://commons.wikimedia.org/wiki/File:18kv\\_collagen\\_02.png](https://commons.wikimedia.org/wiki/File:18kv_collagen_02.png)  
Image: public domain Lucius Howard [https://commons.wikimedia.org/wiki/File:Fibers\\_of\\_Collagen\\_Type\\_I\\_-\\_TEM.jpg](https://commons.wikimedia.org/wiki/File:Fibers_of_Collagen_Type_I_-_TEM.jpg)

Copyright Sara Ziegale

16

16

## Anatomy of the RTC

- Rotator interval: anatomic region of the anterosuperior shoulder
  - Important for stability and proper biomechanical function

Borders	Contents
<ul style="list-style-type: none"> <li>• Coracoid process</li> <li>• Supraspinatus tendon</li> <li>• Subscapularis tendon</li> </ul>	<ul style="list-style-type: none"> <li>• Long head biceps tendon</li> <li>• Coracohumeral lig</li> <li>• Superior glenohumeral lig</li> <li>• Rotator interval capsule</li> </ul>

Consider This

Copyright Sara Ziegale

17

17

## Anatomy of the RTC

- Subacromial/subdeltoid bursa
  - Largest bursa in the body
  - Synovial fluid dissipates friction between RTC and acromion, deltoid

Image: [Creative Commons Attribution 3.0 Unported Zameer Hiji](https://commons.wikimedia.org/wiki/File:Bursae_shoulder_joint_normal.jpg) [https://commons.wikimedia.org/wiki/File:Bursae\\_shoulder\\_joint\\_normal.jpg](https://commons.wikimedia.org/wiki/File:Bursae_shoulder_joint_normal.jpg)

Copyright Sara Ziegale

18

18

## Epidemiology & Pathophysiology

- RTC tears affect 30-50% of people >50 years old
- Estimated 75,000 rotator cuff surgeries performed in the US each year
- Since 2001, there has been a 500% increase in the rate of repair

Image: Microsoft stock photo

Thangarajah, T., Lo, I. K., & Sabo, M. T. (2021). Rotator cuff repair techniques: current concepts. *Journal of Clinical Orthopaedics and Trauma*, 17, 149-156.

19

## Epidemiology & Pathophysiology

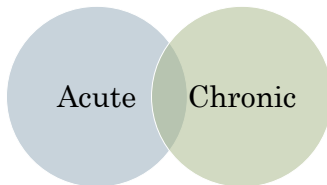
- Risk factors
  - Age >60 yr old
  - 5x more likely than someone under age 60
  - Dominant hand
  - >2x more likely than non-dominant arm
- Potential risk factors
  - High BMI
  - Diabetes mellitus
  - Smoking
  - Hypertension

Image: Creative Commons Attribution-Share Alike 3.0 Unported Oxfordian Kisauhi [https://commons.wikimedia.org/wiki/File:Woman\\_smoking\\_a\\_cigarette.jpg](https://commons.wikimedia.org/wiki/File:Woman_smoking_a_cigarette.jpg)

20

## Epidemiology & Pathophysiology

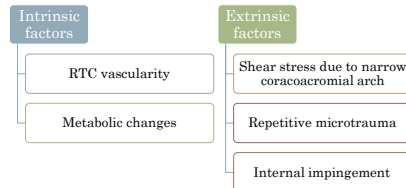
- Mechanism of injury



21

## Epidemiology & Pathophysiology

- Degenerative tears




Manoharan, A., Falgout, D., & Feldman, M. (2021). Arthroscopic Repair of a PKSTA of the Shoulder Using a Bursal Split Arthroscopy techniques. *10(5)*, e1403-e1408.

22

## Epidemiology & Pathophysiology

- Degenerative tears



23

## Epidemiology & Pathophysiology

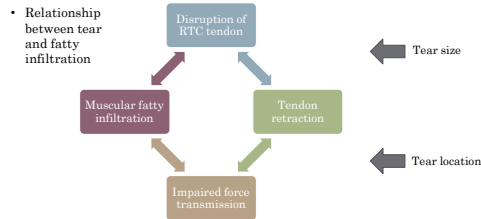
- Degenerative tear progression is common, but slow

	Risk of tear enlargement	
	2 years	5 years
Partial thickness tear	11%	35%
Full thickness tear	22%	50%

Keener, J. D., Patterson, B. M., Ovels, N., & Chamberlain, A. M. (2019). Degenerative rotator cuff tears: refining surgical indications based on natural history data. *The Journal of the American Academy of Orthopaedic Surgeons*, 27(5), 156.

24

## Epidemiology & Pathophysiology



Copyright Sara Ziegale

25

25

## Epidemiology & Pathophysiology

- Acute traumatic tears
  - More likely in relatively young patients
  - Fall or trauma to an abducted, externally rotated arm
  - Typically large tears
  - Often involve the subscapularis

Image: public domain <https://pixabay.com/vectors/falling-tripping-stickman-151819/>

Copyright Sara Ziegale

26

26

## Classification Systems for RTC Tears

- Anatomic classification

Location	Characteristics
Supraspinatus, infraspinatus, teres minor	<ul style="list-style-type: none"> <li>Most common site</li> <li>Subacromial impingement</li> <li>Mechanism: degenerative or dislocation</li> </ul>
Subscapularis	<ul style="list-style-type: none"> <li>More common than previously recognized</li> <li>Subcoracoid impingement</li> <li>Mechanism: acute avulsion or failed repair</li> </ul>

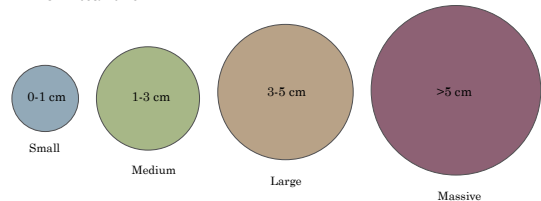
Copyright Sara Ziegale

27

27

## Classification Systems for RTC Tears

- Cuff tear size



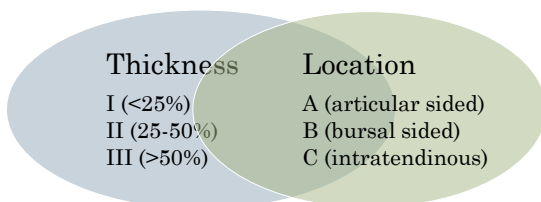
Copyright Sara Ziegale

28

28

## Classification Systems for RTC Tears

- Ellman Classification of Partial Thickness RTC Tears



Copyright Sara Ziegale

29

29

## Classification Systems for RTC Tears

- Goutallier Classification of RTC Atrophy

Classification	Fatty infiltration
0	Normal
1	Some fatty streaks
2	Muscle > fat
3	Fat = muscle
4	Fat > muscle

Copyright Sara Ziegale

30

30

## Classification Systems for RTC Tears

### • Cuff tear shape

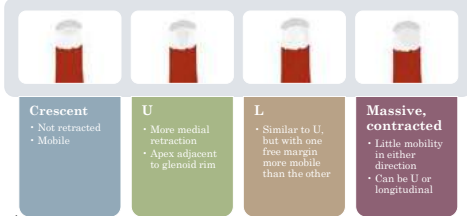


Image: original work

31

## Clinical Exam

- Patient presentation
  - Pain
    - At time of injury
    - At night
    - With overhead activity
  - Located at anterior shoulder or greater tuberosity
  - Radiating down the arm
- Positive painful arc sign
- Weakness
- Reduced range of motion

Image: Creative Commons Attribution-Share Alike 4.0 International InjuryMap [https://commons.wikimedia.org/wiki/File:Shoulder\\_making\\_noises.svg](https://commons.wikimedia.org/wiki/File:Shoulder_making_noises.svg)

32

## Clinical Exam

- Inspection for atrophy (deltoid, supraspinatus, infraspinatus)
- Palpation for tenderness (SC joint, AC joint, biceps)

Image: [Creative Commons Attribution-Share Alike 4.0 International Frank Liebig](https://commons.wikimedia.org/wiki/File:Infraspinatusatrophy.jpg) <https://commons.wikimedia.org/wiki/File:Infraspinatusatrophy.jpg>  
Modipalli, D., Hegde, A. S., & Shetty, C. B. (2019). Diagnostic accuracy in rotator cuff tears: clinical tests vs MRI. *Int J Res Orthop*, 5(4), 727-31.

33

## Clinical Exam

- Range of motion
  - Patterns of loss and pseudoparalysis associated with tear type
  - Adaptions of "normal" ROM in the overhead athlete

Image: Creative Commons Attribution-Share Alike 3.0 Unported Rick Dikeman [https://commons.wikimedia.org/wiki/File:Baseball\\_pitching\\_motion\\_2004.jpg](https://commons.wikimedia.org/wiki/File:Baseball_pitching_motion_2004.jpg)

34

## Clinical Exam

- Using strength as assessment tool
  - Good sensitivity
  - Somewhat lower specificity
- Using pain response as assessment tool
  - Less robust

35

## Clinical Exam

### • Special tests

Supraspinatus	Infraspinatus	Teres minor	Subscapularis
<ul style="list-style-type: none"> <li>• Jobe test (empty can)</li> <li>• Full can test</li> <li>• Drop arm test</li> </ul>	<ul style="list-style-type: none"> <li>• External rotation lag test</li> </ul>	<ul style="list-style-type: none"> <li>• Patte test (hornblowers)</li> </ul>	<ul style="list-style-type: none"> <li>• Lift off test</li> </ul>

36



## Clinical Exam

### • Differential diagnosis

- Glenoid labrum tear
- Biceps Tendonitis
- Shoulder Instability
- Subacromial Impingement
- Osteoarthritis, Rheumatoid Arthritis
- Acromioclavicular injury
- Adhesive Capsulitis
- Calcific Tendonitis
- Subscapular nerve entrapment
- Cervical pathology
- Parsonage Turner Syndrome
- Thoracic Outlet Syndrome

Copyright Sara Ziegale

37

37

## Imaging

### • Utilized to determine whether anatomic RTC repair is viable

- Tear size
- Fatty infiltration
- Retraction

Copyright Sara Ziegale

38

Sellers, T. R., Abdelmassah, A., & Frankie, M. A. (2018). Massive rotator cuff tear: when to consider reverse shoulder arthroplasty. Current reviews in musculoskeletal medicine, 11(1), 131-140.

38

## Imaging

### • MRI

- First line imaging modality
- Visualizes osseous fixation and RTC morphology
- Reimbursable by federal and private payers
- Often widely available appointments

Image: [Creative Commons Attribution-ShareAlike 3.0 RSatUSZ](https://commons.wikimedia.org/wiki/File:1MRI_Complesse_tear_and_rupture_of_the_supraspinatus_tendon_Wide_transmural_damage_(2.4x2.4cm).jpg)  
[https://commons.wikimedia.org/wiki/File:1MRI\\_Complesse\\_tear\\_and\\_rupture\\_of\\_the\\_supraspinatus\\_tendon\\_Wide\\_transmural\\_damage\\_\(2.4x2.4cm\).jpg](https://commons.wikimedia.org/wiki/File:1MRI_Complesse_tear_and_rupture_of_the_supraspinatus_tendon_Wide_transmural_damage_(2.4x2.4cm).jpg)  
 Zoga, A. C., Kamel, S. I., Hynes, J. P., Kavanagh, E. C., O'Connor, P. J., & Forster, B. B. (2021). The evolving roles of MRI and ultrasound in first-line imaging of rotator cuff injuries. American Journal of Roentgenology, 217(6), 1390-1400.

Copyright Sara Ziegale

39

39

## Imaging

### • MRA

- Higher sensitivity and specificity than MRI
- Has not replaced MRI as first line due to practicality
- May be preferred:
  - After RTC repair
  - Younger, athletic patients

Copyright Sara Ziegale

40

Zoga, A. C., Kamel, S. I., Hynes, J. P., Kavanagh, E. C., O'Connor, P. J., & Forster, B. B. (2021). The evolving roles of MRI and ultrasound in first-line imaging of rotator cuff injuries. American Journal of Roentgenology, 217(6), 1390-1400.

40

## Imaging

### • Ultrasound

- Visualizes RTC morphology
- Limited evaluation of osseous repair site
- May have less technologists available

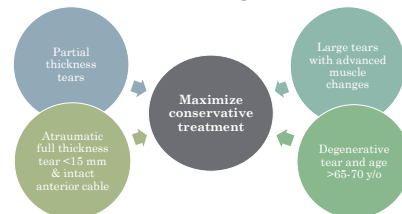
Image: [Creative Commons Attribution-ShareAlike 3.0 RSatUSZ](https://commons.wikimedia.org/wiki/File:US_Infraspinatus_tendon_without_any_pathological_echoogenicity.jpg)  
[https://commons.wikimedia.org/wiki/File:US\\_Infraspinatus\\_tendon\\_without\\_any\\_pathological\\_echoogenicity.jpg](https://commons.wikimedia.org/wiki/File:US_Infraspinatus_tendon_without_any_pathological_echoogenicity.jpg)  
 Zoga, A. C., Kamel, S. I., Hynes, J. P., Kavanagh, E. C., O'Connor, P. J., & Forster, B. B. (2021). The evolving roles of MRI and ultrasound in first-line imaging of rotator cuff injuries. American Journal of Roentgenology, 217(6), 1390-1400.

Copyright Sara Ziegale

41

41

## Conservative Management Strategies



Keener, J. D., Patterson, B. M., Oneto, N., & Chamberlain, A. M. (2019). Degenerative rotator cuff tears: refining surgical indications based on natural history data. The Journal of the American Academy of Orthopaedic Surgeons, 27(5), 156.

Copyright Sara Ziegale

42

42

## Conservative Management Strategies

- NSAIDS
  - Pain management
  - Little research on the use of analgesics specifically for the treatment of RTC tears

Image: Stock Microsoft photo

43

Copyright Sara Ziegale

43

## Conservative Management Strategies

- NSAIDS
  - Mechanism
    - ↓ activity of cyclo-oxygenase (or COX) enzymes
    - Inhibit prostaglandin synthesis
  - Older, non-selective NSAIDs (ibuprofen, diclofenac/Voltaren and naproxen)
    - Inhibit both COX-1 and COX-2 enzymes
  - Newer, selective NSAIDs (celecoxib/Celebrex, etoricoxib)
    - Inhibit COX-2
    - Plays a greater role in prostaglandin mediated pain and inflammation

Machado, G. C., Abdel-Shahed, C., Underwood, M., & Day, R. O. (2021). Non-steroidal anti-inflammatory drugs (NSAIDs) for musculoskeletal pain. *bmj*, 372

44

Copyright Sara Ziegale

44

## Conservative Management Strategies

- NSAIDS
  - Gastrointestinal (perforation, ulcers, bleeding)
  - Cardiovascular (myocardial infarction, heart failure, hypertension)
  - Renal adverse events

GI Risk Factors			
Age >65 y/o	High dose NSAID therapy	Previous hx of uncomplicated ulcer	Concurrent use of aspirin, corticosteroids, or anticoagulants
Low: no risk factors Moderate: 1-3 High: >2 (or hx of complicated ulcer)			

Image: Stock Microsoft photo

45

Copyright Sara Ziegale

45

## Conservative Management Strategies

- Physical therapy
  - Most likely to respond well
    - No impingement signs
    - Good active external rotation
    - Integrity of the intramuscular tendon of supraspinatus
    - Little to no atrophy of supraspinatus muscle

46

Copyright Sara Ziegale

46

## Conservative Management Strategies

- Physical Therapy – MOON group study
  - Subjects (422 patients): MRI-confirmed, atraumatic, full thickness RTC tears
  - Program
    - Daily **ROM** (postural exercises, AAROM, scapular training, AROM)
    - Daily **flexibility** (anterior and posterior shoulder stretching)
    - **Strengthening** 3x/wk (RTC and scapula)
    - PT's provided **manual** mobilization prn
    - Progressed to **HEP** as ready
    - **Heat and cold** recommended (ultrasound was not)
  - Avg visit frequency
    - First 6 weeks: 8 total visits
    - Second 6 weeks: 7 total visits

Kuhn, J. E., Dunn, W. R., Sanders, R., An, Q., Baumgarten, K. M., Bishop, J. Y., ... & MOON Shoulder Group. (2013). Effectiveness of physical therapy in treating atraumatic full-thickness rotator cuff tears: a multicenter prospective cohort study. *Journal of shoulder and elbow surgery*, 22(10), 1371-1379.

47

Copyright Sara Ziegale

47

## Conservative Management Strategies

- Physical Therapy – MOON group study
  - After 2 years, only 26% of participants converted to surgery
    - Most who had surgery, opted to do so within first 12 weeks
  - Estimated that 73-80% of patients with full thickness atraumatic RTC tears could be managed with PT

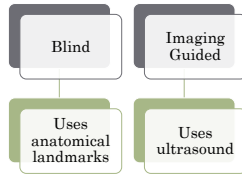
48

Copyright Sara Ziegale

48

## Conservative Management Strategies

- Injections
  - Corticosteroids "cortisone"
    - Dexamethasone
    - Triamcinolone (Kenalog)
    - Methylprednisolone (Medrol)
  - Effects often wear after 6-8 weeks



Bloom, J. E., Bachin, A., Johnston, R. V., & Buchbinder, R. (2012). Image-guided versus blind glucocorticoid injection for shoulder pain. *Cochrane Database of Systematic Reviews*, (5).

49

49

## Conservative Management Strategies

- Injections
  - Having  $\geq 2$  cortisone injections in the year leading up to RTC repair may increase the risk of complications and revision post-op

Desai, V. S., Camp, C. L., Bodapati, V., Dines, J. S., Brockmeier, S. F., & Werner, B. C. (2019). Increasing numbers of shoulder corticosteroid injections within a year preoperatively may be associated with a higher rate of subsequent revision rotator cuff surgery. *Arthroscopy: The Journal of Arthroscopic & Related Surgery*, 35(1), 45-50.

Copyright Sara Ziegale

50

50

## Conservative Management Strategies

- Injections
  - Sodium hyaluronate (hyaluronic acid derivative)
  - Study comparing patient satisfaction between the HA and corticosteroid injection
    - At one month
      - 42% were satisfied after HA
      - 37.5% were satisfied after cortisone
    - Similar outcome at six months

Image: Stock Microsoft photo

Copyright Sara Ziegale

51

51

## Conservative Management Strategies

- Injections
  - Platelet rich plasma
    - Growth factors released by platelets enhance tissue repair
  - Systematic review comparing outcomes to corticosteroid
    - Similar impact on pain in short term
    - May have greater impact on function long term

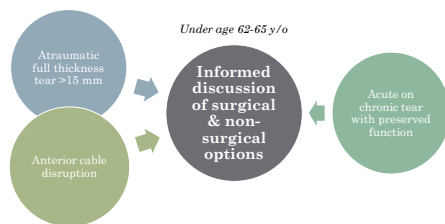
Image: Stock Microsoft photo  
Giovannetti de Sanctis, E., Franceschetti, E., De Dona, F., Palumbo, A., Paciotti, M., & Franceschi, F. (2020). The efficacy of injections for partial rotator cuff tears: a systematic review. *Journal of Clinical Medicine*, 10(1), 51.

Copyright Sara Ziegale

52

52

## Arthroscopic RTC Repair: Indications/Contraindications



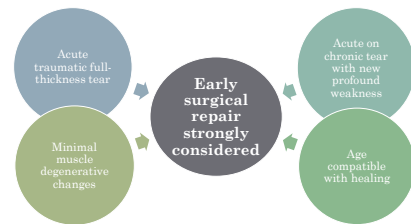
Keener, J. D., Patterson, B. M., Orella, N., & Chamberlain, A. M. (2019). Degenerative rotator cuff tears: refining surgical indications based on natural history data. *The Journal of the American Academy of Orthopaedic Surgeons*, 27(5), 156.

Copyright Sara Ziegale

53

53

## Arthroscopic RTC Repair: Indications/Contraindications



Keener, J. D., Patterson, B. M., Orella, N., & Chamberlain, A. M. (2019). Degenerative rotator cuff tears: refining surgical indications based on natural history data. *The Journal of the American Academy of Orthopaedic Surgeons*, 27(5), 156.

Copyright Sara Ziegale

54

54

## Arthroscopic RTC Repair: Indications/Contraindications

- Contraindications
  - Active infection, especially on skin in surgical field
  - Acne as relative contraindication

Copyright Sara Ziegele

55

55

## Pre-operative Preparation

- Pre-operative physical
  - Physical examination
  - Cardiac evaluation
    - EKG
    - Chest xray
  - Lung function assessment
    - Respiratory/lung function (in the case of breathing abnormalities or obesity)
- Lab tests
  - Blood panel
  - Pregnancy test
  - Cross-match blood testing if blood type is not known
  - Gastrointestinal testing (in the case of chronic inflammation, constipation, etc)

Copyright Sara Ziegele

56

56

## Pre-operative Preparation

- 14 days before surgery
  - Avoid dental work (emergencies require antibiotics) – also for 3 months after
  - Flu shots – also for 6 weeks after

Copyright Sara Ziegele

57

57

## Pre-operative Preparation

- 7 days before surgery
  - Stop anti-coagulants/blood thinners
  - Stop all over the counter herbals and supplements

Copyright Sara Ziegele

58

58

## Pre-operative Preparation

- Night before surgery
  - No eating or drinking after midnight (anesthesia)

Copyright Sara Ziegele

59

59

## Surgical Team

- Surgeon – orthopedist (fellowship in sports or upper extremity)
- 1<sup>st</sup> assist – PA, NP, surgical assist, resident, fellow
- Scrub tech – runs back table, hands instruments
- OR nurse
- Anesthesiologist/CRNA
- Device rep

Image: stock Microsoft photo

Copyright Sara Ziegele

60

60

Consider  
This

## Patient Positioning

- Beach chair position
  - Patient is sitting with hips flexed ~30 degrees
  - Arm is at patient's side
    - Arm holder puts traction on arm and opens subacromial space
  - Head positioned in neutral and strapped in
  - Surgeon stands behind the patient

Image: original work

Gowd, A. K., Liu, J. N., Garcia, G. H., Cabarcas, B. C., & Verma, N. N. (2018). Arthroscopic massive rotator cuff repair and techniques for mobilization. Arthroscopy techniques, 7(6), e633-e638.

Copyright Sara Ziegale

61

61

## Patient Positioning

### Beach chair position

#### Advantages

- Easier orientation and instruction for surgeon
- Position reduces risk of over-tensioning the repair
- Can transition to open procedure without repositioning

#### Disadvantages

- Risk of inadequate cerebral perfusion
- Difficult to perform some labral repairs

Copyright Sara Ziegale

62

62

## Patient Positioning

- Lateral decubitus position
  - Patient is sidelying with contralateral side down
    - Contralateral shoulder flexed 90 deg and padded
  - Surgical arm has traction applied
    - Shoulder flexed 20 deg and ABD 20-45 deg

Image: public domain Defense Visual Information Distribution Service <https://naara.getarchive.net/media/maj-worth-brotherton-51st-medical-group-orthopedic-086224>.

Copyright Sara Ziegale

63

63

## Patient Positioning

### Lateral decubitus position

#### Advantages

- Less risk of inadequate cerebral perfusion
- Better access to aspects of the labrum

#### Disadvantages

- Non-anatomic orientation
- Difficult to assess repair tension due to abducted position

Copyright Sara Ziegale

64

64

## Anesthesia

- Most surgeons prefer general anesthesia
  - Intravenous anesthetic
  - Patient intubated
  - Render a patient unconscious
    - Unable to feel painful stimuli
    - Control autonomic reflexes

Smith, G., D'Cruz, J. R., Rondreau, B., & Goldman, J. (2018). General anesthesia for surgeons.

Copyright Sara Ziegale

65

65

## Anesthesia

- Most surgeons prefer general anesthesia

#### Advantages

- Better pain control
- Better relaxation

#### Disadvantages

- Decreased mean arterial pressure
- Cerebral hypoperfusion in beach chair position

Copyright Sara Ziegale

66

66

## Anesthesia

- General anesthesia PLUS regional anesthesia
  - Interscalene block
  - Indwelling nerve anesthetic catheter

### Advantages

- Decreased need for intraoperative narcotics
- Decreased cerebral deoxygenation events in beach chair position

### Disadvantages

- Inability to perform post-op neuro check

67

## Surgical Instruments

### Basic instruments



30 deg arthroscope



Motorized shaver



Radiofrequency tissue ablation device



Burr



Arthroscopic pump for fluid management



Arthroscopic probe



Graspers



Switching sticks



Tissue punches

Image: original work

68

## Surgical Instruments: Closer look

- 30 degree arthroscope (camera)
  - Used for visualization
  - Angled scopes allow the surgeon to “look around the corner”

Image: original work

69

## Surgical Instruments: Closer look

- Motorized shaver
  - Used to smooth frayed/degenerative tissue

Image: original work

70

## Surgical Instruments: Closer look

- Radiofrequency tissue ablation device
  - Used to reduce bleeding and excise tissue with heat

Image: original work

71

## Surgical Instruments: Closer look

- Burr
  - Used to resect bone and prepare anchor site

Image: original work

72

## Surgical Instruments: Closer look

- Arthroscopic pump for fluid management
  - Used to fill the joint with continuously moving fluid

Image: original work

73

Copyright Sara Ziegale

73

## Surgical Instruments: Closer look

- Arthroscopic probe
  - Used to assess tissue, a surgeon's way to "palpate" during arthroscopy

Image: original work

74

Copyright Sara Ziegale

74

## Surgical Instruments: Closer look

- Graspers
  - Used to hold and move tissue, assess mobility

Image: original work

75

Copyright Sara Ziegale

75

## Surgical Instruments: Closer look

- Switching sticks
  - Used to maintain portal access when moving instruments between sites

Image: original work

76

Copyright Sara Ziegale

76

## Surgical Instruments: Closer look

- Tissue punches
  - Used to create a pilot hole for the anchor

Image: original work

77

Copyright Sara Ziegale

77

## Surgical Instruments

- Procedure specific instruments



Suture retrievers



Elevators



Guillotine knot cutters



Penetrating direct suture passers

(Knot pushers)

Image: original work  
Image: Microsoft stock photo

78

Copyright Sara Ziegale

78

## Surgical Instruments: Closer look

- Suture retrievers
- Used to manipulate suture

Image: original work

79

Copyright Sara Ziegale

79

## Surgical Instruments: Closer look

- Elevators
- Used like a surgical "spatula" to release tissue

Image: Microsoft stock photo

80

Copyright Sara Ziegale

80

## Surgical Instruments: Closer look

- Knot pushers
- Used to deliver a sliding knot to the repair site

Copyright Sara Ziegale

81

81

## Surgical Instruments: Closer look

- Guillotine knot cutter or scissors
- Used to trim the suture

Image: original work

82

Copyright Sara Ziegale

82

## Surgical Instruments: Closer look

- Penetrating direct suture passers or shuttle
- Used to feed the suture through repair site tissue

Image: original work

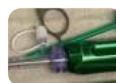83

Copyright Sara Ziegale

83

## Surgical Instruments

- Disposables



Clear cannulae



Suture



Anchors

Image: original work  
Martin Clark, J., & Millett, P. J. (2007). Arthroscopic rotator cuff repair instruments and equipment: setting yourself up for success. Minimally Invasive Shoulder and Elbow Surgery. Informa Healthcare.

84

Copyright Sara Ziegale

84



## Surgical Instruments: Closer look

- Clear cannula
  - Used as a small tunnel to pass instruments into/out of the repair site

Image: original work

85

Copyright Sara Ziegale

85

## Surgical Instruments: Closer look

- Free sutures (wire or tape)
  - Used to approximate the tissue tear site

Image: original work

86

Copyright Sara Ziegale

86

## Surgical Instruments: Closer look

- Anchors
  - Used to secure the sutures to bony attachment site

Image: original work

87

Copyright Sara Ziegale

87

## Portal Site Placement

- Common to have 4 portal sites
  - Posterior – arthroscope
  - Lateral – instrumentation
  - Anterolateral – instrumentation
  - Anterior – instrumentation
- May have more for massive repair

Image: original work

88

Copyright Sara Ziegale

88

## Portal Site Placement

- Important anatomical landmarks during portal placement
  - Acromion
  - AC joint
  - Lateral aspect of clavicle
  - Coracoid

Image: [Creative Commons Attribution 3.0 Unported OpenStax College https://commons.wikimedia.org/wiki/File:903\\_The\\_Scapula.jpg](https://commons.wikimedia.org/wiki/File:903_The_Scapula.jpg)

89

Copyright Sara Ziegale

89

## Portal Site Placement

- Anatomical structures at risk
  - Neurologic
    - Axillary nerve
    - Musculocutaneous nerve
    - Suprascapular nerve
  - Vascular
    - Cephalic vein



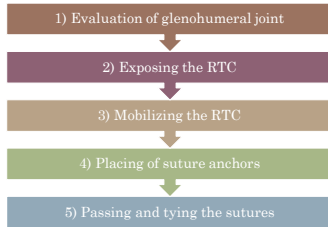
Image: public domain Henry Vandyke Carter <https://commons.wikimedia.org/wiki/File:1744-010.jpg>  
Image: [Creative Commons Attribution 3.0 Unported OpenStax College https://commons.wikimedia.org/wiki/File:2134\\_Thoracic\\_Upper\\_Limb\\_Veins\\_cropped.jpg](https://commons.wikimedia.org/wiki/File:2134_Thoracic_Upper_Limb_Veins_cropped.jpg)

90

Copyright Sara Ziegale

90

## RTC Repair Steps



Copyright Sara Ziegale

91

91

## Evaluation of Glenohumeral Joint

- Prior to completing a rotator cuff repair, the glenohumeral joint needs to be evaluated
  - Ligaments and capsule integrity
  - Cartilage health
  - Bone status

Copyright Sara Ziegale

92

92

## Evaluation of Glenohumeral Joint

- Intra-articular findings often associated with partial rotator cuff tears
  - Hill-Sachs defects
  - Labral lesions
  - Other features of anterior glenohumeral instability

Copyright Sara Ziegale

93

93

## Exposing the RTC

- Debridement with radiofrequency ablation
- Thorough subacromial decompression
  - Soft tissue = bursa resection
  - Bony = acromioplasty

Consider This

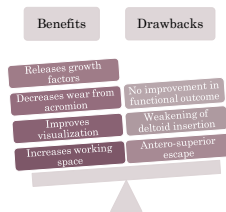
Copyright Sara Ziegale

94

94

## Exposing the RTC

- Risk-benefit of including subacromial decompression



Thangarajah, T., Lo, I. K., & Sabo, M. T. (2021). Rotator cuff repair techniques: current concepts. *Journal of Clinical Orthopaedics and Trauma*, 17, 149-156.

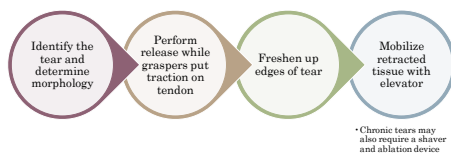
Copyright Sara Ziegale

95

95

## Mobilizing the RTC

- Creating the rotator cuff tendon mobility required to reattach the tendon to the bony footprint



• Chronic tears may also require a shaver and ablation device

Copyright Sara Ziegale

96

96

## Placement of Suture Anchors

- Setting the bony attachment site for the repair
  - Most come pre-loaded with sutures
- Anchor material
  - Metal
  - Bioabsorbable
  - Non-absorbable plastic
  - Soft anchor made only of suture material

Copyright Sara Ziegler

97

97

## Placement of Suture Anchors

- Bioabsorbable anchors
  - Degradation takes approximately two years
  - Replaced by calcified fibrous tissue

Copyright Sara Ziegler

98

98

## Passing and Tying the Sutures

- Technique depends on the shape of the tear
- Crescent
  - Regardless of tear size, this type often has excellent mobility and can be repaired directly to bone with minimal tension

Image: original work  
Thangarajah, T., Lo, I. K., & Sabo, M. T. (2021). Rotator cuff repair techniques: current concepts. *Journal of Clinical Orthopaedics and Trauma*, 17, 149-156.

Copyright Sara Ziegler

99

99

## Passing and Tying the Sutures

- Technique depends on the shape of the tear
- U Shape
  - Need to use margin convergence (side to side sutures) first, then the lateral margin can be reattached to the bone – resulting in a “T” shape repair

Image: original work  
Thangarajah, T., Lo, I. K., & Sabo, M. T. (2021). Rotator cuff repair techniques: current concepts. *Journal of Clinical Orthopaedics and Trauma*, 17, 149-156.

Copyright Sara Ziegler

100

100

## Passing and Tying the Sutures

- Technique depends on the shape of the tear
- L Shape
  - Need to determine the direction of greatest mobility and use a traction suture to secure the tendon in this direction, then reattach to the bone

Image: original work  
Thangarajah, T., Lo, I. K., & Sabo, M. T. (2021). Rotator cuff repair techniques: current concepts. *Journal of Clinical Orthopaedics and Trauma*, 17, 149-156.

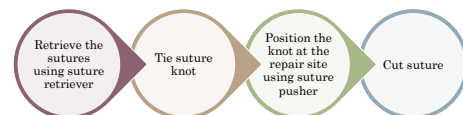
Copyright Sara Ziegler

101

101

## Passing and Tying the Sutures

- Tying the suture



Copyright Sara Ziegler

102

102

## Variations in Surgical Technique

- Use of subacromial decompression
- Anchor and suture selection
- Knot vs. knotless

Copyright Sara Ziegale

103

103

## Variations in Surgical Technique

- Repair constructs
  - Single row
    - Easy, quick, requires less tendon length
    - Better suited for small tears
  - Double row
    - Biomechanically superior, improved footprint restoration
    - Better suited for large and massive tears with adequate tendon length
- Transosseous equivalent (suture bridge)
  - Provides broader surface area of contact

Image: original work

Copyright Sara Ziegale

104

104

## Variations in Surgical Technique

- Use of interval slide
  - Release of the rotator interval from a retracted supraspinatus tendon
  - Large, chronic RTC tears

Consider This

Copyright Sam Ziegale

105

105

## Variations in Surgical Technique

- Management of biceps
  - Tenodesis
    - Long head released from labrum and reattached at the humerus
  - Tenotomy
    - Long head released and not reattached
- Outcomes
  - Both procedures show significant improvement in shoulder pain and function

Image: public domain Henry Vandyke Carter [https://commons.wikimedia.org/wiki/File:Gray\\_NA27087694\\_musculos\\_biceps\\_brachii.png](https://commons.wikimedia.org/wiki/File:Gray_NA27087694_musculos_biceps_brachii.png)  
 Srivastava, R. C., Han, K. A., Wright, T. W., Farmer, K. W., Wright, J. O., Busch, R. P., ... & King, J. J. (2022). Outcomes of Biceps Tenotomy Versus Tenodesis During Arthroscopic Rotator Cuff Repair: An Analysis of Patients From a Large Multicenter Database. *Orthopaedic Journal of Sports Medicine*, 10(7), 23259671221110851.

Copyright Sam Ziegale

106

106

## Post Operative Management

- Arm positioned in sling/abduction immobilizer
  - Improved vascularization
  - Tension on repaired tendons minimized
  - Often used for about 6 weeks

Image: [Creative Commons Attribution-Share Alike 3.0 Unported](https://creativecommons.org/licenses/by-sa/4.0/) Laboratories Server <https://samart.servier.com>

Copyright Sara Ziegale

107

107

## Post Operative Management

- Pain control
  - In the past, opioids as primary analgesic
  - Avg 60-80 pills prescribed → often refilled
  - Studies suggest that 8.5%-15% of RTC repair patients are still on opioids 180 days after surgery
- Side effects:
  - Constipation
  - Nausea
  - Vomiting
  - Respiratory distress
  - Somnolence
  - Sleep disturbance
  - Urinary retention
  - Dependence
  - Addiction

Patel, M. S., Abboud, J. A., & Sethi, P. M. (2020). Perioperative pain management for shoulder surgery: evolving techniques. *Journal of Shoulder and Elbow Surgery*, 29(11), e416-e433.

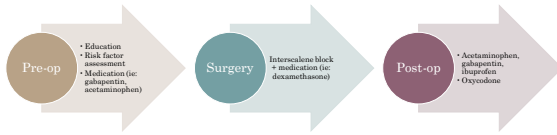Copyright Sara Ziegale

108

108

## Post Operative Management

- Pain control – current recommendation
- Multi-modal



Patel, M. S., Abboud, J. A., & Sethi, P. M. (2020). Perioperative pain management for shoulder surgery: evolving techniques. *Journal of Shoulder and Elbow Surgery*, 29(11), e416-e423.

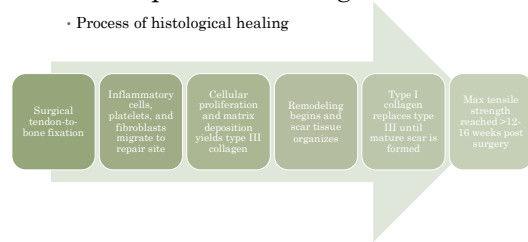
Copyright Sara Ziegler

109

109

## Post Operative Management

- Process of histological healing



Copyright Sara Ziegler

110

110

## Post Operative Management

- Rate limiting step for functional recovery: healing of the RTC to the greater tuberosity
- Believed to take 8-12 weeks



Copyright Sara Ziegler

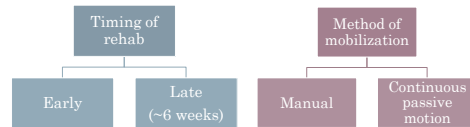111

Image: Stock Microsoft photo

111

## Post Operative Management

- Physical therapy
- Approaches compared in terms of functional scores, pain, ROM, strength, retear rates



Copyright Sara Ziegler

112

112

## Post Operative Management

### Phase I (inflammatory and repair)

- Passive range of motion begins as soon as surgeon clears as "safe"
- AROM at the elbow, wrist, hand, cervical spine
- Postural education

Copyright Sara Ziegler

113

113

## Post Operative Management

### Phase II (remodeling)

- Active assisted range of motion → active range of motion
- Scapular proprioception
- Submax isometrics

Copyright Sara Ziegler

114

114

## Post Operative Management

### Phase III (RTC strengthening)

Isotonic and light closed chain stability exercise

Scapular strengthening

Copyright Sara Ziegale

115

115

## Post Operative Management

### Phase IV (advanced RTC strengthening)

Sport specific rehab activities

Endurance of maximum tensile strength

Plyometrics

Copyright Sara Ziegale

116

116

## Alternative Surgical Management for RTC Tear

- Subacromial decompression and RTC debridement alone
  - For select patients with low-grade partial articular sided RTC tear
- Tendon transfer
  - For some massive RTC tears
- Superior capsular reconstruction
  - For some massive irreparable RTC tears with intact subscapularis
- Reverse total shoulder arthroplasty
  - For some massive tears in patients >65 y/o or with glenohumeral arthritis and intact deltoid

Willis, A., Levine, W., & Sharareh, B. (2023, January 19). Rotator cuff tears. Orthobullets. Retrieved January 23, 2023, from <https://www.orthobullets.com/shoulder-and-elbow/3643/rotator-cuff-tears>

Copyright Sara Ziegale

117

117

## Surgical Outcomes

- Complications
  - Stiffness
  - Persistent pain: chronic regional pain syndrome, incorrect pre-operative diagnosis
  - Cerebral hypoperfusion (due to positioning): stroke, blindness
  - Nerve injuries due to excessive pressure or traction (most self limiting and will improve with time)
  - Very rare: infection, thromboembolic events

Consider This

Copyright Sara Ziegale

118

118

## Surgical Outcomes

- Recovery metrics
  - Impairments (ROM, strength)
  - Function (self-report questionnaires)
  - Quality-of-life (QoL questionnaires)
  - Pain
  - Satisfaction
  - Tendon healing

Copyright Sara Ziegale

119

119

## Surgical Outcomes

- Tendon healing
  - Studies show structural defect rates between 13-94%
  - Most common mechanism of repair failure (identified during revision surgery)
    - Failed fixation at the suture-tendon interface
    - Most retears occur in the first 6 months post-op

Consider This

Copyright Sara Ziegale

120

120

Thangarajah, T., Lo, I. K., & Sabo, M. T. (2021). Rotator cuff repair techniques: current concepts. Journal of Clinical Orthopaedics and Trauma, 17, 149-156.

## Surgical Outcomes

- Impairments in the case of retear
  - Range of motion
    - Maintained!
  - Strength
    - Forward flexion 45% reduced
    - External rotation 42% reduced

121

Copyright Sara Ziegale

121

## Surgical Outcomes

- Function/patient reported outcomes in the case of retear
  - Maintained!

Greer, A., Loyt, K., Molino, J., Evangelista, P., Gallacher, S., & Atkins, J. (2023). Long-term functional and structural outcome of rotator cuff repair in patients 60 years old or less. *JSES International*, 7(1), 58-66.

122

Copyright Sara Ziegale

122

## Surgical Outcomes

- Positive prognostic factors: **demographic**
  - Younger age
  - Male gender

Image: Stock Microsoft photo

123

Copyright Sara Ziegale

123

## Surgical Outcomes

- Positive prognostic factors: **clinical factors**
  - Higher bone mineral density
  - Absence of diabetes mellitus
  - Higher level of sports activity
  - Greater preoperative range of motion
  - Absence of obesity

Stock Microsoft photo

124

Copyright Sara Ziegale

124

## Surgical Outcomes

- Positive prognostic factors: **factors related to cuff integrity**
  - Smaller sagittal size of the cuff lesion
  - Less retraction of the cuff
  - Less fatty infiltration
  - No multiple tendon involvement

125

Copyright Sara Ziegale

125

## Surgical Outcomes

- Positive prognostic factors: **factors related to surgical procedure**
  - No concomitant biceps or acromioclavicular joint procedures

126

Copyright Sara Ziegale

126

## Conclusion

· Arthroscopic rotator cuff tear is a commonly utilized procedure in the surgical management of rotator cuff tear. By better understanding rotator cuff tear evaluation and the subsequent arthroscopic repair, rehabilitation professionals can provide more informed, quality care to their patients.

127

Copyright Sara Ziegale

127

## Q1

The rotator interval is bordered by which of the following structures?

- A. Biceps tendon, acromion, infraspinatus
- B. Teres major, pec minor, coracohumeral ligament
- C. Head of the humerus, supraspinatus, first rib
- D. Coracoid process, supraspinatus tendon, subscapularis tendon

128

Copyright Sara Ziegale

128

## Q2

Which of the following is a rotator cuff tear classification referring to tear shape?

- A. Crescent
- B. Bursal
- C. Zig zag
- D. Articular

129

Copyright Sara Ziegale

129

## Q3

Which of the following is a common indication for arthroscopic rotator cuff repair?

- A. Acute full-thickness tear
- B. Bursal-sided tear <2 mm in depth
- C. Partial articular-sided tears <25%
- D. None of the above

130

Copyright Sara Ziegale

130

## Q4

Arthroscopic rotator cuff repair is commonly performed with the patient in which of the following positions?

- A. Lithotomy position
- B. Prone decubitus position
- C. Beach chair position
- D. Standing

131

Copyright Sara Ziegale

131

## Q5

Which of the following surgical instruments is commonly utilized during arthroscopic repair of the rotator cuff?

- A. Retractor
- B. Rongeur
- C. Balloon
- D. Motorized shaver

132

Copyright Sara Ziegale

132



Q6

Which of the following surgical steps takes place BEFORE mobilizing the rotator cuff during an arthroscopic rotator cuff repair?

- A.Placement of suture anchors
- B.Passing the sutures
- C.Exposing the rotator cuff
- D.Tying the sutures

133

Copyright Sara Ziegale

133

Q7

An interval slide is most likely to be performed during arthroscopic repair of which type of rotator cuff tear?

- A.Acute traumatic tear
- B.Large chronic tear
- C.Small partial tear
- D.Mobile partial tear

134

Copyright Sara Ziegale

134

Q8

Following arthroscopic repair of the rotator cuff, how long does it take for biologic healing of the rotator cuff tendon to the greater tuberosity?

- A.2-4 weeks
- B.4-6 weeks
- C.6-8 weeks
- D.8-12 weeks

135

Copyright Sara Ziegale

135

Q9

Which of the following surgical complications is associated with arthroscopic rotator cuff repair?

- A.Shoulder stiffness
- B.Persistent pain
- C.Peripheral nerve injury
- D.All of the above

136

Copyright Sara Ziegale

136

Q10

Revision surgery has identified which of the following as the most common mechanism of rotator cuff repair failure?

- A.Failure of fixation at the suture-tendon interface
- B.Loosening of anchor
- C.Fraying of suture
- D.Fracture of the humerus

137

Copyright Sara Ziegale

137

## References

- Abdul-Wahab, T. A., Belarouci, J. P., Hassan, F., Thani, S. A., Chouli, H., Jain, N. B., ... & Verborgt, O. (2016). Initial treatment of complete rotator cuff tear and transition to surgical treatment: systematic review of the evidence. *Muscles, Ligaments and Tendon Journal*, 6(1), 35.
- Barber, F. A., Herbert, M. A., & Richards, D. P. (2003). Sutures and suture anchors: update 2003. *Arthroscopy: The Journal of Arthroscopic & Related Surgery*, 19(9), 985-990.
- Beaudouin, J., Nizard, R., Thomas, T., Payet, M., Lataste, J. P., Dubois, P., ... & Walsh, G. (2008). Contribution of clinical tests to the diagnosis of rotator cuff disease: a systematic literature review. *Joint Bone Spine*, 75(1), 15-19.
- Berthoin, R., Thurlack, J. N., Nakorn, A. A., Schner, S., More, K. D., Wong, B., ... & Lu, L. K. (2015). Arthroscopic repair of massive, contracted, irreparable tears using interval slides: clinical and MRI structural follow-up. *Knee Surgery, Sports Traumatology, Arthroscopy*, 25(2), 352-357.
- Bevilacqua, F. T., Quaresima, M., Flato, E. L., & Vogel, K. G. (1997). Biology of the rotator cuff tendon. *Orthopaedic Clinics*, 28(1), 1-16.
- Bloom, J. E., Ruchter, A., Johnston, R. V., & Buckleider, R. (2012). Image-guided versus blind glucocorticoid injection for shoulder pain. *Cochrane Database of Systematic Reviews*, (8).
- Boush, K., Hsiao, A., Sharma, A., Dwyer, P., & Singh, H. (2022). Use of suture tapes versus conventional sutures for arthroscopic rotator cuff repairs: a systematic review and meta-analysis. *The American Journal of Sports Medicine*, 50(1), 244-272.
- Burkhart, S. S., & Lo, I. K. (2006). Arthroscopic rotator cuff repair. *JAAOS-Journal of the American Academy of Orthopaedic Surgeons*, 14(8), 333-346.
- Canale, L. K., Rao, A., & Battaman, B. M. (2022). Clinical Faceoff: Management of Massive Rotator Cuff Tears in Patients Younger than 65 Years of Age. *Clinical Orthopaedics and Related Research*, 480(3), 674-678.
- Chen, M., Xu, W., Dong, Q., Huang, Q., Xia, Z., & Mao, Y. (2013). Outcomes of single-row versus double-row arthroscopic rotator cuff repair: a systematic review and meta-analysis of current evidence. *Arthroscopy: The Journal of Arthroscopic & Related Surgery*, 29(8), 1437-1449.
- Collin, P., Matsumura, N., Lidenmann, A., Denard, P. J., & Walsh, G. (2014). Relationship between massive chronic rotator cuff tear pattern and loss of active shoulder range of motion. *Journal of shoulder and elbow surgery*, 23(8), 1195-1202.
- Corakos, J. A., Barker, M., Craig, E. Y., Klein, D., & Warren, R. F. (2002). The partial-thickness rotator cuff tear: is acromioplasty without repair sufficient? *The American journal of sports medicine*, 30(2), 257-263.
- Cummins, C. A., & Murrell, G. A. (2003). Mode of failure for rotator cuff repair with suture anchors identified at revision surgery. *Journal of shoulder and elbow surgery*, 12(2), 128-133.

138

Copyright Sara Ziegale

138

## References

- Dehnen, A. M., Aeshel, T. W., Kaya, D., Schmitt, L., Puckett, B., & Foster, T. E. (2012). Does double-row rotator cuff repair improve functional outcome of patients compared with single-row technique? A systematic review. *The American journal of sports medicine*, 40(5), 1170-1185.
- Dines, V. S., Carey, C. L., Boddipati, V., Dines, J. S., Beutner, S. F., & Warner, J. C. (2019). Increasing numbers of shoulder arthroscopic injections within a year prospectively may be associated with a higher rate of subsequent revision rotator cuff surgery. *Arthroscopy: The Journal of Arthroscopic & Related Surgery*, 35(1), 46-50.
- Distad, C. C., Kiley, A., Varma, N. N., Adler, R. S., Nguyen, J., Cordasco, F. A., & Altchek, D. W. (2010). The long-term outcome of recurrent defects after rotator cuff repair. *The American Journal of Sports Medicine*, 38(1), 30-36.
- Duncan, N. S., Boker, S. J., Gossling, B. W., Geishegen, J., Wilkerson, W. A., & Manning, P. A. (2015). Surgery within 6 months of an acute rotator cuff tear significantly improves outcome. *Journal of Shoulder and Elbow Surgery*, 24(12), 1976-1980.
- Farmer, K. W., & Wright, T. W. (2015). Shoulder arthroscopy: the basics. *The Journal of Hand Surgery*, 40A, 817-821.
- Farmer, A. J., Wolfswinkel, N., Waseel, R. N., Bassam, J. P., & De Bie, R. A. (2014). Prognostic factors for successful recovery after arthroscopic rotator cuff repair: a systematic literature review of orthopaedic & sports physical therapy. 44(3), 170-182.
- Fukuda, H. (2022). The management of partial-thickness tears of the rotator cuff. *The Journal of bone and joint surgery*, British volume, 104(1), 91-111.
- Giannakidis, B., & Bartolacci, M. (2013). Corticosteroid injection in rotator cuff tears in elderly patient: pain outcome prediction. *Geriatrics & gerontology international*, 13(4), 993-1001.
- Gouvernement du Québec, E., Franceschetti, E., Du Dene, F., Palumbo, A., Piacitelli, M., & Franceschi, F. (2020). The efficacy of injections for partial rotator cuff tears: a systematic review. *Journal of Clinical Medicine*, 10(1), 51.
- Goldberg, B. A., Nowinski, R. J., & Matian, B. F. A. (2001). Outcome of nonoperative management of full-thickness rotator cuff tears. *Clinical Orthopaedics and Related Research* (1976-2007), 382, 99-107.
- Gornal, A. K., Liu, J. N., Garcia, G. H., Cabezas, B. C., & Varma, N. N. (2018). Arthroscopic massive rotator cuff repair and techniques for mobilization. *Arthroscopy techniques*, 7(6), e423-e438.
- Green, A., Loyd, K., Reddy, J., Evangelista, P., Gallacher, S., & Adkins, J. (2022). Long-term functional and structural outcome of rotator cuff repair in patients 60 years old or less. *JSES International*, 7(1), 26-35.
- Grossmann, J. A., Patel, M., Wirth, R. J., & Minkoff, P. J. (2015). Massive rotator cuff tears: pathomechanics, current treatment options, and clinical outcomes. *Journal of shoulder and elbow surgery*, 24(9), 1492-1508.
- Hansen, A., Strödel, M., Schöley, R., & Dahm, D. (2019). Review of shoulder range of motion in the throwing athlete: Distinguishing normal adaptations from pathologic deficits. Current reviews in musculoskeletal medicine, 12, 249-255.

Copyright Sara Ziegale

139

## References

- Hopperfield, S., DeBarr, P., & Buckley, R. (2012). Surgical approaches in arthroscopy: the anatomic approach. Lippincott Williams & Wilkins.
- Kessler, J. D., Galatz, L. M., Teasley, S. A., Middleton, W. D., Steger-May, K., Bobbs-Cochran, G., ... & Yamaguchi, K. (2016). A prospective evaluation of survivorship of asymptomatic degenerative rotator cuff tears. *JBJS*, 97(2), 89-98.
- Kessler, J. D., Patterson, B. M., Chavis, N., & Charnakian, A. M. (2015). Degenerative rotator cuff tears: refining surgical indications based on natural history data. *The Journal of the American Academy of Orthopaedic Surgeons*, 27(5), 158.
- Kim, H. M., Dalrym, N., Teasley, S. A., Kessler, J. D., Galatz, L. M., & Yamaguchi, K. (2016). Relationship of tear size and location to fatty degeneration of the rotator cuff. *The Journal of Bone and Joint Surgery*, American volume, 98A, 829.
- Kim, S. H., Ha, K. I., Ahn, J. H., & Park, J. H. (2002). Differential arthroscopic portal placement for rotator cuff repair. *Arthroscopy: The Journal of Arthroscopic & Related Surgery*, 18(6), 1-4.
- Kohn, J. L., Levin, S. D., Chahal, E. L., & Murphy, G. S. (2013). Near Avoid 2012: central oxygenation in the beach chair position: a prospective study on the effect of general anesthesia compared with regional anesthesia and sedation. *Journal of shoulder and elbow surgery*, 22(10), 1325-1331.
- Kuhn, J. E., Dahn, W. R., Sanders, R., An, Q., Baumgarten, K. M., Bishop, J. Y., ... & MOON Shoulder Group. (2013). Effectiveness of physical therapy in treating traumatic full-thickness rotator cuff tears: a multicenter prospective cohort study. *Journal of shoulder and elbow surgery*, 22(10), 1371-1378.
- Lidemann, A., Denard, P. J., & Collin, P. (2015). Massive rotator cuff tears: definition and treatment. *International orthopaedics*, 39, 2463-2474.
- Liu, F., Cheng, X., Dong, J., Zhou, D., Han, S., & Yang, Y. (2020). Comparison of MRI and MRA for the diagnosis of rotator cuff tears: a meta-analysis. *Medicine*, 99(12).
- Lomatch, O., Bachiler, F., Vase, J., Kahn, D., & Page, D. (2008). Cyclic loading of rotator cuff reconstructions: single-row repair with modified suture configurations versus double-row repair. *The American Journal of Sports Medicine*, 36(8), 1564-1570.
- Lowring, R. M., & Russ, D. W. (2008). Fiber type composition of cadaveric human rotator cuff muscles. *Journal of orthopaedic & sports physical therapy*, 38(11), 674-680.
- Machado, G. C., Abdel-Shahel, C., Underwood, M., & Day, R. O. (2021). Non-steroidal anti-inflammatory drugs (NSAIDs) for musculoskeletal pain. *bmj*, 372.
- Mall, N. A., Lee, A., Chahal, J., Sherman, S. L., Romeo, A. A., Varma, N. N., & Cole, B. J. (2013). An evidence-based examination of the epidemiology and outcomes of traumatic rotator cuff tears. *Arthroscopy: The Journal of Arthroscopic & Related Surgery*, 29(2), 388-378.

Copyright Sara Ziegale

140

## References

- Meneshian, A., Falgaud, D., & Feldman, M. (2021). Arthroscopic Repair of a PATEA of the Shoulder Using a Bursal Split. *Arthroscopy techniques*, 10(5), e1403-e1408.
- Moini Clark, J., & Minkoff, P. J. (2007). Arthroscopic rotator cuff repair: instruments and equipment: setting yourself up for success. *Minimally Invasive Shoulder and Elbow Surgery*. Informa Healthcare.
- Mout, P. J., & Hirth, R. J. (2014). Postoperative rotator cuff tear classification, pattern recognition, and treatment. *JBJS: Journal of the American Academy of Orthopaedic Surgeons*, 32(9), 161-164.
- Moudgil, D., Hsieh, A. S., & Shetty, C. S. (2019). Diagnostic accuracy in rotator cuff tears: clinical tests vs MRI. *Int J Res Orthop*, 5(4), 727-731.
- Moon, T. C., Rudolph, G. H., Casswell, K., Espinoza, C., Burkhead Jr, W. Z., & Krishnan, S. G. (2014). Complications of shoulder arthroscopy. *JBJS: Journal of the American Academy of Orthopaedic Surgeons*, 32(7), 410-415.
- Nelson, C. O., Siles, M. J., Grossman, M. G., & Serna-Hay, J. (2008). Single-row modified mason-lee versus double-row arthroscopic rotator cuff repair: a biomechanical and surface area comparison. *Arthroscopy: The Journal of Arthroscopic & Related Surgery*, 24(5), 941-948.
- Patel, M. S., Reddy, J. A., & Saha, P. K. (2020). Postoperative pain management for shoulder surgery: working techniques. *Journal of Shoulder and Elbow Surgery*, 29(11), e115-e122.
- Pothigian, C. N., Behn, L. S., Jazrawi, L. M., Klein, Y. W., Bello, J. S., & React, M. P. (2010). The rotator interval: a review of anatomy, function, and normal and abnormal MRI appearance. *American Journal of Roentgenology*, 195(3), 587-595.
- Powers, M. (2016). NSAIDs: Isolating the risks and benefits. *US Pharm*, 41(2), 24-26.
- Puckett, D. L., Roberts, M. A., & Andrews, T. H. C. (2021). Muscle fiber type transitions with exercise training: Shifting perspectives. *Sports*, 9(9), 127.
- Sayermanshah, A. A., & Andrews, T. H. C. (2017). Systematic review on risk factors of rotator cuff tears. *Journal of Orthopaedic Surgery*, 25(1), 233-240/15584316.
- Sellers, T. R., Abdelkader, A., & Frenkel, M. A. (2018). Massive rotator cuff tear: when to consider revision shoulder arthroplasty. Current reviews in musculoskeletal medicine, 11(1), 131-143.
- Sheth, V., Mohankumar, K., Erenli, G., & Hirth, M. (2001). Clinical evaluation of sodium hyaluronate for the treatment of patients with rotator cuff tear. *Journal of Shoulder and Elbow Surgery*, 10(5), 209-216.
- Smith, G., D'Onofrio, J. R., Rindfleisch, B., & Goldman, J. (2018). General anesthesia for surgery.
- Spangoli, G. (2016). Partial arthroscopic acromioclavicular (PACAT) lesion. Current concepts in rehabilitation. *International Journal of Sports Physical Therapy*, 11(2), 452.

Copyright Sara Ziegale

141

## References

- Strickland, R. C., Hsu, K. A., Wright, T. W., Farmer, K. W., Wright, J. D., Roach, R. P., ... & King, J. J. (2022). Outcomes of Biceps Tenotomy Versus Tenodesis During Arthroscopic Rotator Cuff Repair: An Analysis of Patients From a Large Multicenter Database. *Orthopaedic Journal of Sports Medicine*, 10(7), 235568722110381.
- Sugita, H., Maeda, K., Matsui, K., & Morioka, J. (2007). Repair integrity and functional outcome after arthroscopic double-row rotator cuff repair: a prospective outcome study. *JBJS*, 89(5), 953-961.
- Tanno, J. C. (2004). Arthroscopic repair of large rotator cuff tears using the internal suture technique. *Arthroscopy: The Journal of Arthroscopic & Related Surgery*, 20(1), 13-21.
- Thompson, T., & Lo, I. K. (2022). Optimal Management of Partial Thickness Rotator Cuff Tears: Clinical Considerations and Practical Management. *Orthopaedic Research and Reviews*, 14, 59.
- Thompson, T., Lo, I. K., & Sabo, M. T. (2021). Rotator cuff repair techniques: current concepts. *Journal of Clinical Orthopaedics and Trauma*, 17, 149-156.
- Thigpen, C. A., Shaffer, M. A., Grant, S. W., Leggin, B. G., Williams, G. R., & Wilton III, B. B. (2019). The American Society of Shoulder and Elbow Therapists' consensus statement on rehabilitation following arthroscopic rotator cuff repair. *Journal of shoulder and elbow surgery*, 29(4), 521-535.
- Thompson, J. C. (2009). *Hatter's concise orthopaedic anatomy*. Elsevier Health Sciences.
- van der Walpaas, D. A., Weigand, P., Charney, Z., Gansel, T. R., Kellmeyer, D., & Minkoff, P. J. (2012). Rehabilitation after arthroscopic rotator cuff repair: current concepts review and evidence-based guidelines. *International journal of sports physical therapy*, 7(2), 197.
- van Holsbeeck, M., & Strouas, P. J. (1993). Sonography of the shoulder: evaluation of the subacromial-subdeltoid bursa. *AJR: American journal of roentgenology*, 160(3), 561-564.
- Vardoulakis, N. J., Dineen, T., Lee, T. G., & Lippswald, O. (2022). Shoulder surgery techniques and preferences in treatment of massive rotator cuff tears: current practices for rotator cuff repair and superior capsule reconstruction. *JSES International*, 6(6), 378-383.
- Villa, A., Levine, W., & Sharavish, B. (2022, January 19). Rotator cuff tears. *Orthobullets*. Retrieved January 21, 2023, from <https://www.orthobullets.com/shoulder-and-elbow/3043/rotator-cuff-tears>.
- Yi, A., Villacis, D., Valamanchi, R., & Hatch III, G. F. R. (2015). A comparison of rehabilitation methods after arthroscopic rotator cuff repair: a systematic review. *Sports Health*, 7(4), 326-334.
- Ziegler, A. C., Kandel, E. L., Hayes, J. P., Kneibler, E. C., O'Connor, P. J., & Foster, S. B. (2021). The evolving roles of MRI and ultrasound in first-line imaging of rotator cuff injuries. *American Journal of Roentgenology*, 217(6), 1300-1400.

Copyright Sara Ziegale

142