

Wrist and Hand Disorders

Goals and Objectives

Course Description

"Wrist and Hand Disorders" is an online recorded video of a previously presented live CE webinar for physical therapists and physical therapist assistants that examines common orthopedic and neurologic wrist and hand pathologies. This course includes a review of current literature relating to pathophysiology, arthrokinematics, diagnostic procedures, and clinical presentation for pathologies of the wrist and hand.

Course Rationale

The purpose of this course is to provide an understanding of the pathophysiology of wrist and hand pathologies with comparative analysis of pathogenesis and clinical presentation to understand rehabilitation considerations and maximize outcomes based on current research.

Course Goals and Objectives

Upon completion of this course, participants will be able to:

1. Identify common anatomical structures of the wrist and hand.
2. Identify normal and abnormal wrist and hand arthrokinematics.
3. Recognize imaging and neurodiagnostic studies utilized to diagnose wrist and hand pathologies.
4. Recognize and define common pathologies involving the joints, bones, ligaments, tendons, nerves, and fascia of the wrist and hand.
5. Identify the mechanism of injury and pathogenesis for common wrist and hand disorders.
6. Define adult and pediatric fracture classifications.
7. Recognize the clinical presentation of common wrist and hand pathologies.
8. Identify provocative tests utilized to assess pathologies of the wrist and hand.
9. Identify patient-reported outcome measures utilized for wrist and hand disorders

Course Provider – Innovative Educational Services

Provider Contact Information – information@cheapceus.com

Course Instructor – Jodi Gootkin, PT, Med, CEAS

Financial/Non-financial Disclosure - Neither the Provider nor the instructor have any financial or non-financial conflict of interest related to the presentation of this CE program.

Target Audience – Physical Therapists, Physical Therapist Assistants

Course Educational Level – This course is applicable for introductory learners.

Course Prerequisites – None

Instructional Method – Distance Learning – Independent; Asynchronous online video-based home study

Location - Cheapceus.com

Date – Continuously available on-demand

PD Activity Completion Requirements / Criteria for Issuance of CE Credits – Completion of viewing of 1 hour recorded video, and a score of 70% correct or greater on the course post-test.

Continuing Education Credits – Three (3) contact hours

Course Fee - \$34.95

Registration Information – No pre-registration required; available on-demand at Cheapceus.com

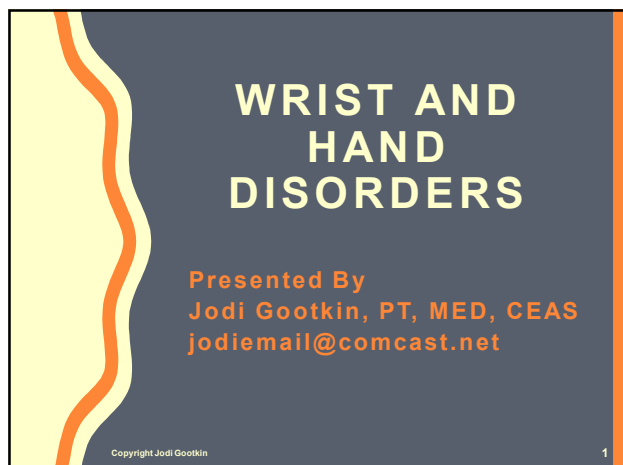Special Needs Requests – Email: information@cheapceus.com or phone: 954-663-4101

Cancellation by the Learner – Learners may cancel their participation at any time and receive a full refund of all paid fees.

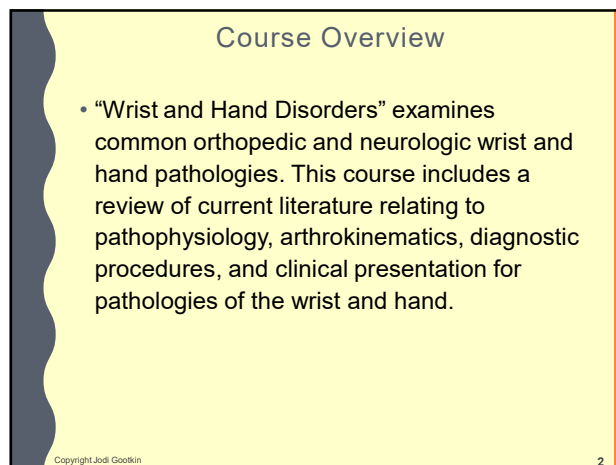
Cancellation by the Provider – Registrants for the cancelled activity will be contacted by an IES staff member via phone call or email within 12 hours of the cancellation decision. If the decision to cancel is made less than 14 hours prior to the event, each participant will be contacted no later than 2 hours prior to the scheduled start time of the activity. Registrants will receive a full refund if an activity is cancelled by the Provider. The refund will be processed back to the Registrant within 12 hours of the cancellation.

Complaint Resolution – Please call 954-663-4101 (24 hours/day, 7 days/week) to speak with a live customer service agent. Our goal is to work with our customers to resolve all issues to the customer's satisfaction with just one phone call whenever possible.

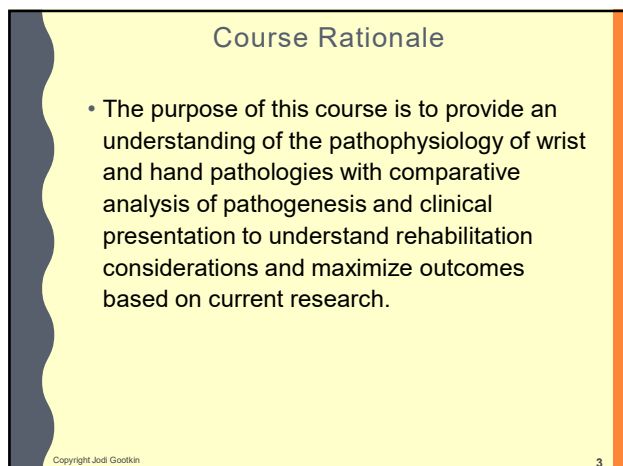
Refund Policy - Unrestricted 100% refund upon request. The request for a refund by the learner shall be honored in full without penalty or other consideration of any kind. The request for a refund may be made by the learner at any time without limitations before, during, or after course participation.



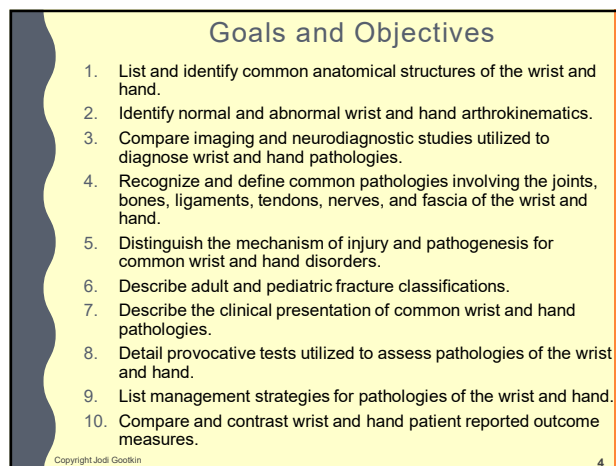
1



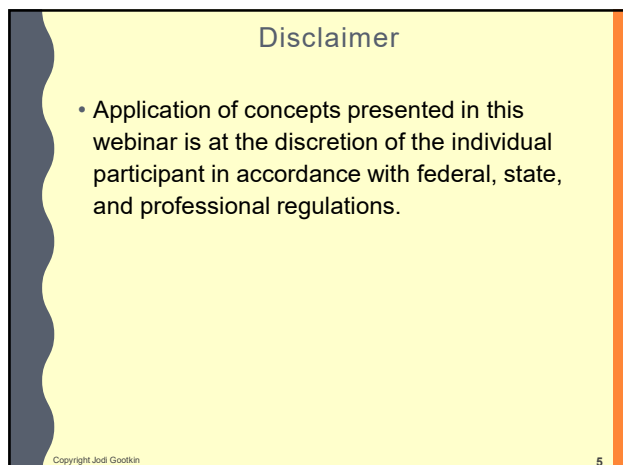
2



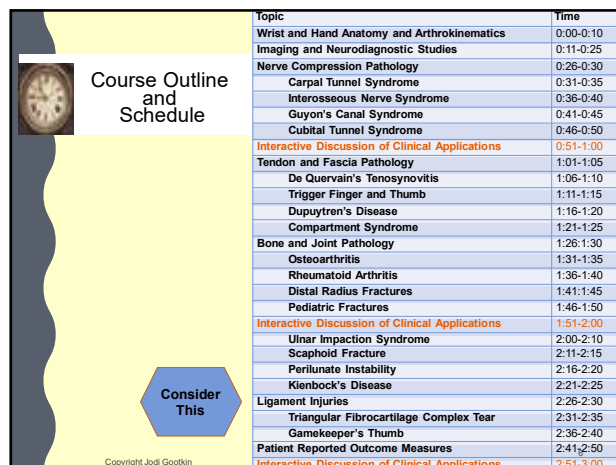
3



4



5



6

Wrist and Hand Disorders

Copyright Innovative Educational Services and Jodi Gootkin. All rights reserved.
 Reproduction, reuse, or republication of all or any part of this presentation is strictly prohibited
 without prior written consent of both Innovative Educational Services and Jodi Gootkin.

How To Obtain CEUs For This Course

- After watching the video go to www.cheapceus.com
- Complete the post test with score of at least 70%
 - May be retaken multiple times
- Submit online payment for course
- Print certificate
- **Course review and summary for post test at the end of the webinar.**



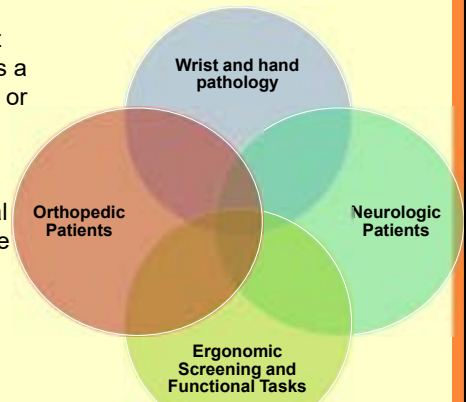
Consider This

Copyright Jodi Gootkin

7

Wrist and Hand Function

- The wrist serves as a stabilizer or moving segment for functional use of the hand to occur.



Copyright Jodi Gootkin

8

Wrist and Hand Anatomy

• Proximal to Distal

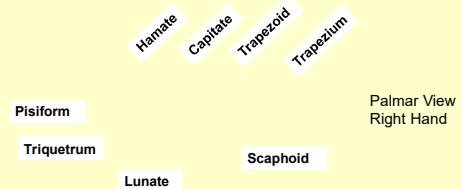
Radius and Ulna	Radiocarpal Joint (Wrist)	Proximal and Distal Radioulnar Joints (PRUJ, DRUJ)
Carpals	Midcarpal Joint	Intercarpal Joints
Metacarpals	Metacarpal Phalangeal Joint (MCP)	
Phalanges	Proximal and Distal Interphalangeal Joint (PIP, DIP)	Thumb Interphalangeal Joint (IP)

Copyright Jodi Gootkin

9

Carpal Bones

- The 8 small bones are arranged into a proximal and distal row.
- Clockwise from Thumb:
 - Straight Line To Pinky, Here Comes The Thumb
- Counter clockwise from Pinky:
 - PTs Love Sundaes, Ten Toppings Can't Hurt



Copyright Jodi Gootkin

10

Radiocarpal Joint

- Articulation between biconcave surface of radius with scaphoid and lunate.

Distal Radioulnar Joint (DRUJ)

- Articular cartilage covered ulnar head and radial sigmoid notch glide with minimal intrinsic stability from bony architecture.

Copyright Jodi Gootkin

11

Normal Arthrokinematics

- Three dimensional movements between the carpals contribute to global wrist motion.
 - Flexion and Extension
 - Radial and Ulnar Deviation
 - Pronation and Supination
- Research varies on whether the proximal or distal row of carpals contributes more to wrist ROM.
 - Consider goniometry measurement using dorsal versus lateral hand placement.

Copyright Jodi Gootkin

12

Wrist and Hand Disorders

Copyright Innovative Educational Services and Jodi Gootkin. All rights reserved.

Reproduction, reuse, or republication of all or any part of this presentation is strictly prohibited without prior written consent of both Innovative Educational Services and Jodi Gootkin.

Functional Task Analysis

- Wrist range of motion (ROM) required for functional tasks varies by individual.
 - Personal Hygiene
 - 50 degrees flexion to 40 degrees extension
 - Feeding
 - 35 – 40 degrees extension
 - Typing
 - 10 degrees extension
 - Sit to stand
 - 50-60 degrees extension
 - Wheelchair propulsion and assistive devices
 - Excessive compressive force and altered wrist mechanics

Copyright Jodi Gootkin

13

13

Structure Allows Function

- Proposed that morphological changes during evolution permitted Homo sapien performance of improved hunting, gathering, and protection.
- MCP/CMC rotation
 - Three jaw chuck
- Shorter and mobile 5th metacarpal
 - Power grip

Copyright Jodi Gootkin

14

14

Dart Throwers Motion (DTM)

- Movement of the wrist in an oblique motion to the anatomical axis from radial extension to ulnar flexion similar to the movement performed when throwing a dart.
- Biomechanically the proximal row of carpals form a stable base allowing motion primarily at the midcarpal joint.
- Utilized in tasks requiring forceful upper extremity demands and many activities of daily living (ADL).

Copyright Jodi Gootkin

15

15

Goniometry DTM

- Goniometric alignment of this composite motion is challenging.
- Proposed alignment:
 - Position: elbow flexion and forearm neutral
 - Axis: radiocarpal joint
 - Stationary arm: lateral border of radius
 - Moving arm: dorsal second metacarpal

Vardakastani, V., Bell, H., Mee, S., Brigstocke, G., & Kedgley, A. E. (2018). Clinical measurement of the dart throwing motion of the wrist: variability, accuracy and correction. *The Journal of hand surgery, European volume*, 43(7), 723–731.

Copyright Jodi Gootkin

16

16

Wrist and Hand Musculature

Forearm

- Pronator Teres and Quadratus
- Supinator

Wrist

- Palmaris Longus, Flexor Carpi Radialis and Ulnaris
- Extensor Carpi Ulnaris, Radialis Longus and Brevis

Extrinsic Hand

- Extensor Digitorum, Indicus, Digiti Minimi
- Flexor Digitorum Superficialis and Profundus
- Extensor Pollicis Longus and Brevis, Flexor, Abductor Pollicis Longus

Intrinsic Hand

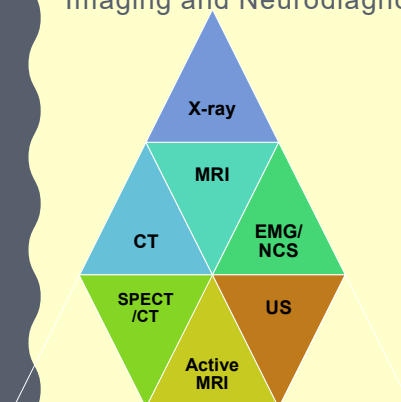
- Thenar and Hypothenar Eminence
- Lumbricals, Dorsal and Palmar Interossei

Copyright Jodi Gootkin

17

17
Wrist and Hand Disorders

Imaging and Neurodiagnostic Studies



Copyright Jodi Gootkin

18

18

Copyright Innovative Educational Services and Jodi Gootkin. All rights reserved.

Reproduction, reuse, or republication of all or any part of this presentation is strictly prohibited without prior written consent of both Innovative Educational Services and Jodi Gootkin.

Skeletal Age Assessment

- Determination of skeletal maturity based on radiographic assessment of hand bone ossification.
- Several scoring systems are utilized
 - Greulich and Pyle (GP) utilizes a single standardized image for a range of age of each gender for comparison and determination.
 - Tanner-Whitehouse (TW) scores each carpal, radius and ulna for a total score to estimate age.
 - Computer automated assessment tools are being developed.

Copyright Jodi Gootkin

19

19

Skeletal Age Implications

- Delayed or advanced bone age compared to chronological age is correlated with clinical presentation and other diagnostic tests.

Endocrine conditions

- Constitutional delay, hypothyroidism, growth hormone deficiency, Cushing disease

Nutritional disorders

- Malnutrition

Genetic syndromes

- Trisomies, Turner syndrome, Klinefelter syndrome

Nonendocrine chronic disease

- Inflammatory bowel disease, cystic fibrosis, chronic kidney disease, neglect and abuse

Chronologic age estimation

- When birth records unavailable

Orthodontics

- Dental implants

20

20

Radiography (X-ray) vs. Computed Tomography (CT)

- Radiography is the first screening tool utilized to assess acute traumatic and hand injuries.
- Some research suggests it may underestimate intra-articular distal radius fracture severity or leave carpal fractures unnoticed.

Copyright Jodi Gootkin

21

21

Radiography vs. Multiple Detector Computer Tomography (MDCT)

- Assembles multiple CT images into a more 3D image for detection of the complex hand anatomy.

Copyright Jodi Gootkin

22

22

Single Photon Emission Computed Tomography/Computed Tomography SPECT/CT

- Combining two imaging studies during one scan provides information on morphological structure, metabolic activity, and precise location of lesions.

Copyright Jodi Gootkin

23

23
Wrist and Hand Disorders

MRI

- Correlation of clinical presentation and radiographs can aid physician in determination of the need for MRI to identify soft tissue pathology.
- Considered to be more precise in identifying occult fractures when x-ray is negative.

Copyright Jodi Gootkin

24

24

Copyright Innovative Educational Services and Jodi Gootkin. All rights reserved.

Reproduction, reuse, or republication of all or any part of this presentation is strictly prohibited without prior written consent of both Innovative Educational Services and Jodi Gootkin.

Active MRI

- This dynamic imaging technique permits movement during scanning.
- The multiple images captured each second are strung together to create a movie of the wrist motion performed.
- Allows closer analysis of complex wrist and hand motions particularly instability.

Copyright Jodi Gootkin 25

25

Electrophysiologic Studies

- In some states, physical therapists may perform these studies with varying restrictions.
 - Specific education training is required
 - Cannot diagnose based on results

NCS
Nerve Conduction Study

- Speed of nerve signal transmission.
- Electrodes applied superficially to skin.

EMG
Electromyography

- Electrical activity at rest and during contraction.
- Small needles inserted into muscle.

Copyright Jodi Gootkin 26

26

Ultrasound

- Allows visualization of the entire course of a peripheral nerve in the extremity in a short time.
- Tendon thickening, effusion, and calcification can be identified.
- Diagnostic accuracy is increased as pressure from transducer may elicit patient feedback on clinical symptoms that are elicited.

Consider This

Copyright Jodi Gootkin 27

27

Nerve Ultrasound

- Dynamic imaging permits observation of nerve deformation and displacement during range of motion.

Copyright Jodi Gootkin 28

28

Provocative Tests

- Selectively manipulating tissues to evoke characteristics of different neurologic or musculoskeletal conditions to determine their presence.

Copyright Jodi Gootkin 29

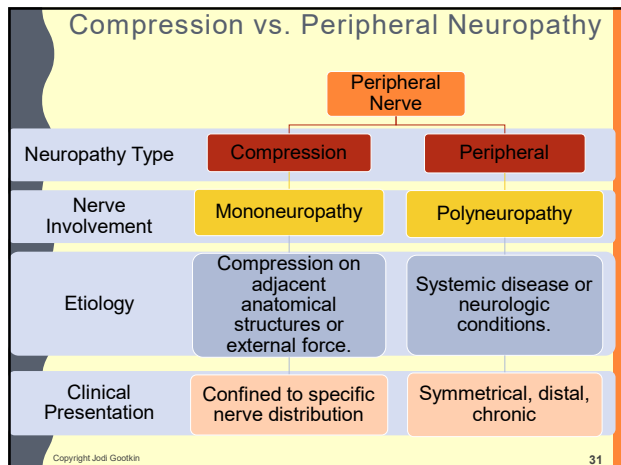
29
Wrist and Hand Disorders

Common Pathologies

Nerve	<ul style="list-style-type: none"> • Carpal Tunnel Syndrome • Interosseous Nerve Syndrome • Guyon's Canal Syndrome • Cubital Tunnel Syndrome
Tendon	<ul style="list-style-type: none"> • DeQuervain's Tenosynovitis • Trigger Finger or Thumb
Fascia	<ul style="list-style-type: none"> • Dupuytren's Disease • Compartment Syndrome
Bone/Joint	<ul style="list-style-type: none"> • Osteoarthritis and Rheumatoid Arthritis • Distal Radius Fracture • Pediatric Fractures • Ulnar Impaction Syndrome • Scaphoid Fracture • Perilunate Instability • Kienbock's Disease
Ligament	<ul style="list-style-type: none"> • Triangular Fibrocartilage Complex Tear • Gamekeeper's Thumb

Copyright Jodi Gootkin 30

30



31

Compression Neuropathy

- Entrapment of the peripheral nerve can occur at various intervals down the extraspinal path of the nerve.
- Differential diagnosis based on motor and sensory impairments isolates the location of the compression.

Copyright Jodi Gootkin 32

32

Space Occupying Lesion

- Ganglion cysts are benign fluid filled soft tissue swellings that form near tendons and joint capsules which can encroach on local nerves.

Copyright Jodi Gootkin 33

33

Flexor Retinaculum

- Supports the carpal arch attaching medially to the pisiform and hook of the hamate bridging to the trapezium and scaphoid.
- The carpal tunnel created is encased with the visceral and parietal synovial layers and contains:
 - ✓ Median Nerve
 - ✓ Flexor Digitorum Profundus
 - ✓ Flexor Digitorum Superficialis
 - ✓ Flexor Pollicis Longus

Copyright Jodi Gootkin 34

34

Carpal Tunnel Syndrome (CTS)

- Mononeuropathy with entrapment of the median nerve in the carpal tunnel of the wrist results weakness and altered sensation of the hand .
- Diagnosed clinically and confirmed by electromyography (EMG), nerve conduction study (NCS) and ultrasonography (US).

Copyright Jodi Gootkin 35

35

CTS Etiology

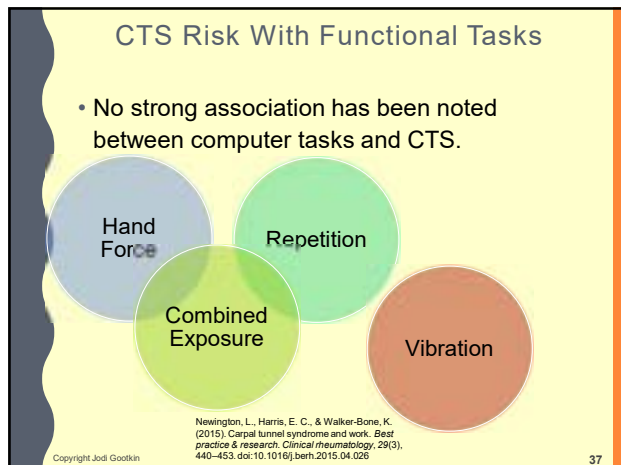
- Thickening of transverse carpal ligament or tendon sheaths, altered bony architecture, or other encroachment compresses median nerve.

Idiopathic	
Traumatic	Subluxation of lunate, wrist fracture
Inflammatory conditions	Rheumatoid arthritis
Endocrine	Diabetes, hypothyroidism, menopause, pregnancy
Space occupying lesions	Ganglions, tumors
Vascular conditions	Hemophilia, anticoagulants
Obesity	High BMI
Overuse	Tenosynovial hypertrophy of flexor tendons

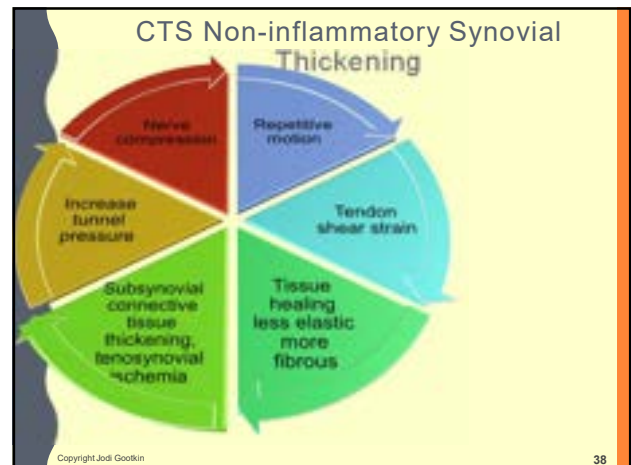
Copyright Jodi Gootkin 36

36

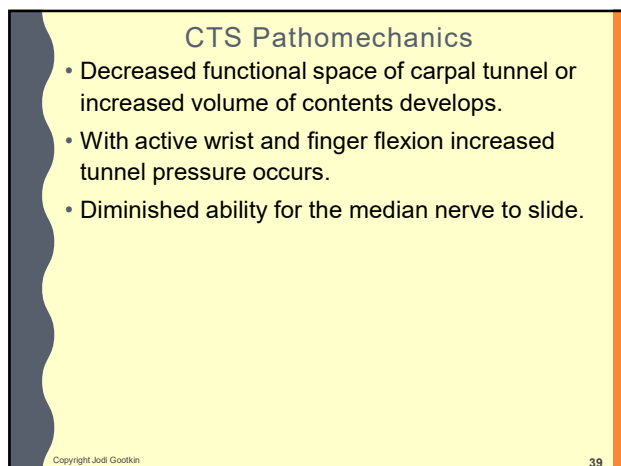
Wrist and Hand Disorders



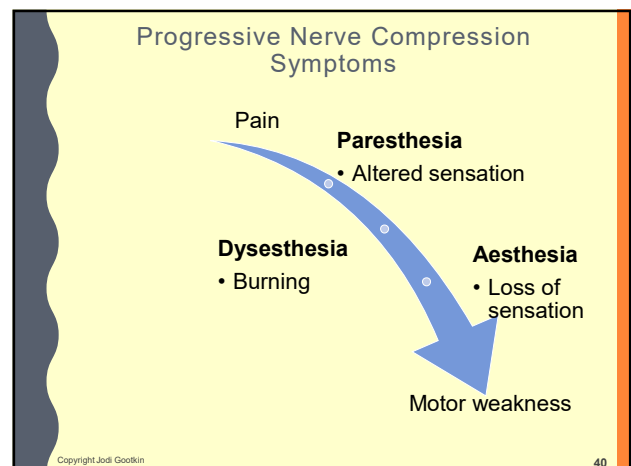
37



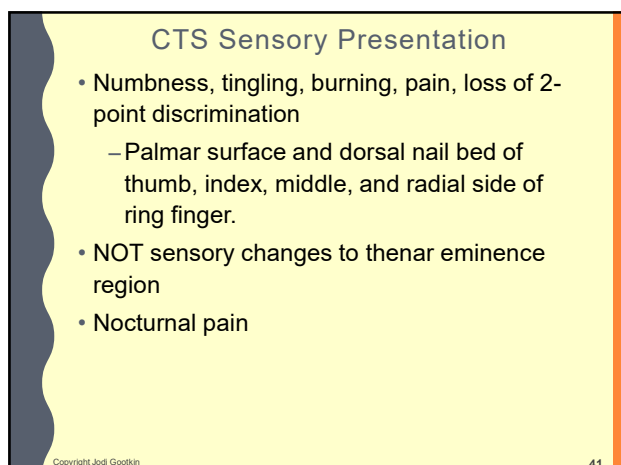
38



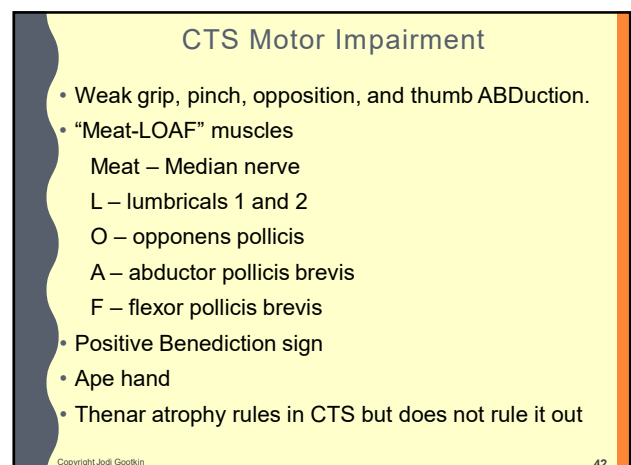
39



40



41



42

CTS Provocative Tests

- Positive Median Nerve provocative testing not recommended as independent indicators.
 - Tinel's Sign (at wrist)
 - Phalen's Test
- Upper Limb Neural Tension (ULNT) Median Nerve
 - Conflicting interpretation related to CTS

Baselgia, L. T., Bennett, D. L., Silbiger, R. M., & Schmid, A. B. (2017). Negative Neurodynamic Tests Do Not Exclude Neural Dysfunction in Patients With Entrapment Neuropathies. *Archives of physical medicine and rehabilitation*, 98(3), 480–486. doi:10.1016/j.apmr.2016.06.019

American Academy of Orthopaedic Surgeons. (2013). Appropriate Use Criteria for Treatment of Distal Radius Fractures. Rosemont, IL: American Academy of Orthopaedic Surgeons, 27-41.

Copyright Jodi Gootkin

43

CTS Differential Diagnosis

- Be precise with sensory assessment and isolated muscle testing to distinguish clinical presentation.
 - Cervical radiculopathy C6-C7
 - Lower brachial plexus injury
 - Nerve injury following upper extremity fracture
 - Diabetic neuropathy

Nee, R. J., Jull, G. A., Vicenzino, B., & Coppieters, M. W. (2012). The validity of upper-limb neurodynamic tests for detecting peripheral neuropathic pain. *Journal of orthopaedic & sports physical therapy*, 42(5), 413-424.

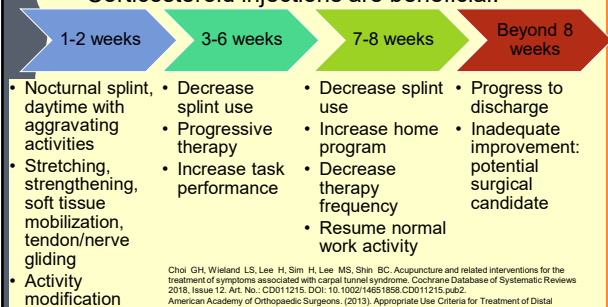
Consider This

Copyright Jodi Gootkin

44

CTS Conservative Management

- NSAIDs, diuretics, acupuncture NOT effective.
- Corticosteroid injections are beneficial.



Choi, GH, Wieland, LS, Lee, H, Sim, H, Lee, MS, Shin, BC. Acupuncture and related interventions for the treatment of symptoms associated with carpal tunnel syndrome. *Cochrane Database of Systematic Reviews* 2016, Issue 12. Art. No.: CD011215. DOI: 10.1002/14651858.CD011215.pub2

American Academy of Orthopaedic Surgeons. (2013). Appropriate Use Criteria for Treatment of Distal Radius Fractures. Rosemont, IL: American Academy of Orthopaedic Surgeons, 27-41.

Huisteide, B. M., Friden, J., Coert, J. H., Hoogvliet, P., & European HANDGUIDE Group. (2014). Carpal tunnel syndrome: hand surgeons, hand therapists, and physical medicine and rehabilitation physicians agree on a multidisciplinary treatment guideline—results from the European HANDGUIDE Study. *Archives of physical medicine and rehabilitation*, 95(12), 2253-2263.

Copyright Jodi Gootkin

45

CTS Splinting

- Nocturnal splinting and daytime splinting when performing aggravating activities
- No consensus on splint design
 - Neutral splint or cock-up
 - With or without lumbrical extension

American Academy of Orthopaedic Surgeons. (2013). Appropriate Use Criteria for Treatment of Distal Radius Fractures. Rosemont, IL: American Academy of Orthopaedic Surgeons, 27-41.

Page MJ, Massey-Westrop N, O'Connor D, Pitt V. Splinting for carpal tunnel syndrome. *Cochrane Database Syst Rev*. 2012 Jul 11;7.CD010003. doi: 10.1002/14651858.CD010003.

Copyright Jodi Gootkin

46

Anterior Interosseous Nerve (AIN) Syndrome

- Compression of branch of median nerve traveling just distal to the pronator teres in the anterior compartment of the forearm.
 - Flexor Pollicis Longus (FPL), index and middle finger flexor digitorum superficialis (FDS), and pronator quadratus (PQ)

Trauma Etiology

- Fracture
- Penetrating Injuries
- Venipuncture
- Surgery

Compression Etiology

- Lipoma or ganglion
- Compartment syndrome
- Cast pressure

Copyright Jodi Gootkin

47

AIN Syndrome Clinical Presentation

- Dull pain on anterior aspect of proximal forearm.
- Sensation remains intact.
- Muscle weakness of thumb, index and middle finger flexion.
 - Positive OK sign
- Assess tenodesis to distinguish from FPL rupture.

Copyright Jodi Gootkin

48

Posterior Interosseous Nerve (PIN) Syndrome

- Compressive neuropathy of the deep branch of the radial nerve near the supinator muscle.
- Etiology may be insidious or specific trauma, space occupying lesion, or overuse of supination/pronation.

Copyright Jodi Gootkin

49

49

PIN Syndrome Clinical Presentation

- Sensation remains intact but may present with pain.
- Palpable tenderness over arcade of Frohse.
- Distinguish from lateral epicondylitis.
 - Weak finger extension and wrist extension with radial drift
 - Unable to “rock on”

Copyright Jodi Gootkin

50

50

Guyon's Canal Syndrome

- Compression neuropathy of the ulnar nerve where it passes between the pisiform and hamate.

Intrinsic Etiology

- Ganglion Cyst
- Lipoma
- Ulnar Artery Aneurysm or Thrombosis

Extrinsic Etiology

- Pisiform, Hamate, Hypothenar Trauma
- Overuse
- Handlebar Palsy

Copyright Jodi Gootkin

51

51

Guyon's Canal Syndrome Presentation

- Presentation may be purely sensory (Zone 3), purely motor (Zone 2), or mixed (Zone 1).

Copyright Jodi Gootkin

52

52

Guyon's Canal Clinical Presentation

- Weakness of pinch and grip
 - Hypothenar muscles, ADDuctor pollicis, all interossei muscles, pinky and ring lumbricals
- Positive findings:
 - Froment's Sign
 - Wartenberg's Sign
 - Claw hand

Copyright Jodi Gootkin

53

53

Cubital Tunnel Syndrome

- Ulnar nerve is vulnerable to injury from external trauma or compression in the medial epicondyle region.
- Encroachment can also occur from bone fragments, space-occupying lesions, and regional inflammation.
- Motor and special test presentation is the same as Guyon's Canal Syndrome with the addition of symptoms from more proximal ulnar nerve branches.
 - Elbow flexion exacerbates pain
 - Positive Tinel's Sign (at Elbow)
- Weakness of wrist flexion (FCU), pinky and ring finger flexion (FDP)

Copyright Jodi Gootkin

54

54

Wrist and Hand Disorders

Copyright Innovative Educational Services and Jodi Gootkin. All rights reserved.

Reproduction, reuse, or republication of all or any part of this presentation is strictly prohibited without prior written consent of both Innovative Educational Services and Jodi Gootkin.

Ulnar Nerve Sensory Presentation

Through Wrist Canal
Guyon's Canal Syndrome

- Distal ulnar border of palm, palmar pinky, and ulnar half ring

Not Through Wrist Canal
Cubital Tunnel Syndrome

- Proximal ulnar side palm, ulnar dorsum of hand, pinky, and ulnar half ring

Will also demonstrate

Copyright Jodi Gootkin

55

Ulnar Nerve Compression Differential Diagnosis

- Guyon's Canal vs. Cubital Tunnel Syndrome
- Lower Brachial Plexus Injury
- Cervical Radiculopathy C8 T1
- Thoracic Outlet Syndrome (TOS)
- Pancoast Syndrome -non-small cell lung carcinoma (NSCLC) of superior sulcus progresses to thoracic inlet, brachial plexus, and cervical sympathetic nerve lesions.
 - Radiating pain – axilla, scapula, and ulnar nerve distribution.
 - Upper extremity and ulnar nerve atrophy
 - Horner Syndrome
 - Ptosis, miosis, hemianhidrosis, enophthalmos

Copyright Jodi Gootkin

56

Compressive Neuropathy Management

- Nocturnal and daytime splinting as needed
- Patient education on activity modification
- Ergonomic and workplace assessment
- Therapy interventions are directed at alleviating compression and restoring muscle strength, sensation and coordination for functional motor control.
- Corticosteroid Injection
- Decompression Surgery

Copyright Jodi Gootkin

57

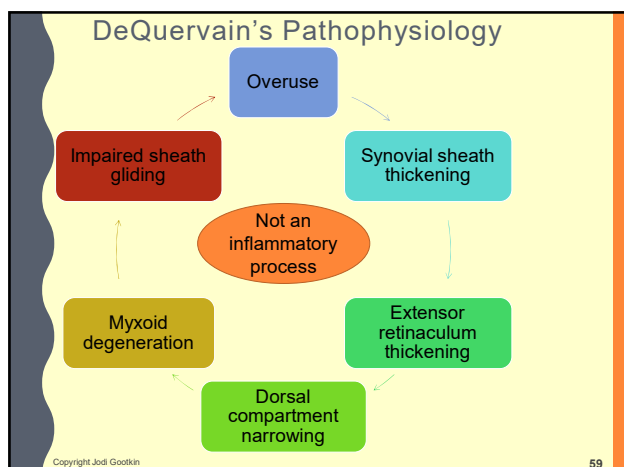
DeQuervain's Tenosynovitis

- Stenosing tenosynovitis of the wrist first dorsal compartment containing the abductor pollicis longus (APL) and extensor pollicis brevis (EPB).
- Associated with repetitive thumb motions or grasping with ulnar deviation.
- Increased incidence in females postpartum.

Consider This

Copyright Jodi Gootkin

58



59

DeQuervain's Clinical Presentation

- Tenderness along dorsolateral border of distal radius.
- Severe pain with resisted thumb extension.
- Positive Finkelstein's Test
- Treatment with corticosteroid injection, activity modification, thumb spica splint, kinesiotaping, and phonophoresis.

Rowland, P., Phelan, N., Gardiner, S., Linton, K. N., & Galvin, R. (2015). The Effectiveness of Corticosteroid Injection for De Quervain's Stenosing Tenosynovitis (DQST): A Systematic Review and Meta-Analysis. *The open orthopaedics journal*, 9, 437-444.
 D'Angelo, K., Sutton, D., Côté, P., Dion, S., Wong, J. J., Yu, H., ... & Brown, C. (2015). The effectiveness of passive physical modalities for the management of soft tissue injuries and neuropathies of the wrist and hand: a systematic review by the Ontario Protocol for Traffic Injury Management (OPTIMA) collaboration. *Journal of manipulative and physiological therapeutics*, 38(7), 493-506.

Copyright Jodi Gootkin

60

Wrist and Hand Disorders

Copyright Innovative Educational Services and Jodi Gootkin. All rights reserved.
 Reproduction, reuse, or republication of all or any part of this presentation is strictly prohibited
 without prior written consent of both Innovative Educational Services and Jodi Gootkin.

Trigger Finger and Trigger Thumb

- Primarily idiopathic stenosing tenosynovitis of the flexor tendon most commonly in the ring finger, thumb, and middle finger.
- In adults, associated with comorbidities diabetes, rheumatoid arthritis, and carpal tunnel syndrome.
- Pediatric etiology appears to be developmental.
- No agreement on overuse or trauma etiology.

Copyright Jodi Gootkin

61

61

Flexor Pulley System

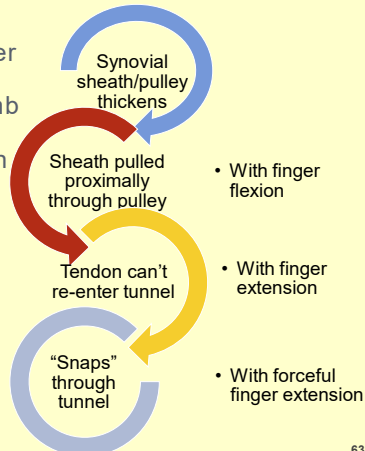
- Stabilization of the tendons in each finger within fibroosseous sheaths prevents bowstringing and maintains mechanical advantage for functional hand use.
- Annular Pulleys (A1 to A5) at MCP, PIP, DIP joints and proximal and middle phalanges
- Cruciate Pulleys (C1 to C3) on phalanges between annular pulleys

Copyright Jodi Gootkin

62

62

Trigger Finger and Trigger Thumb Clinical Presentation



Copyright Jodi Gootkin

63

63

Trigger Finger and Trigger Thumb Clinical Presentation

- Palpable tender nodule on palmar aspect of MCP joint that moves with finger flexion.
- Open Close Hand 10 Times Test
- Conservative management with steroid injection, splinting, soft tissue mobilization, stretching and surgery if not responsive.

Amendy, R., McIninch, R., Watts, A., Rodriguez, J., Wang, T., R. C., Glessner, N., & Bullock, J. (2017). Evidence-based management of adult trigger digital. *Journal of Hand Surgery (European Volume)*, 42(5), 473-480. Image:

Consider This

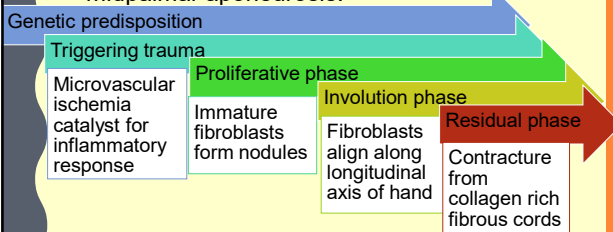
Copyright Jodi Gootkin

64

64

Dupuytren's Disease

- Progressive fibrotic thickening of the midpalmar aponeurosis.



Ball, C., Izadi, D., Verjee, L. S., Chan, J., & Nanchahal, J. (2016). Systematic review of non-surgical treatments for early dupuytren's disease. *BMC musculoskeletal disorders*, 17(1), 345. doi:10.1186/s12891-016-1200-y

Copyright Jodi Gootkin

65

Wrist and Hand Disorders

Dupuytren's Disease Clinical Presentation

- Dupuytren's Contracture - MCP flexion of the ring and pinky fingers.
- Visible palpable cords in palm without tenderness.
- Typically, conservative treatment with corticosteroid or collagenase injections and surgery indicated when hand function significantly impaired.

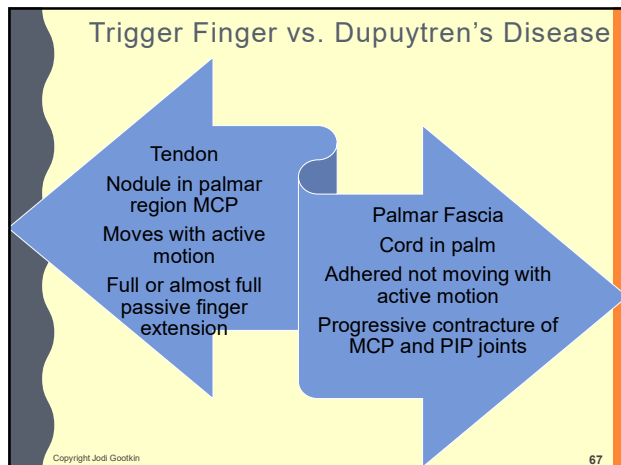
Copyright Jodi Gootkin

66

66

Copyright Innovative Educational Services and Jodi Gootkin. All rights reserved.

Reproduction, reuse, or republication of all or any part of this presentation is strictly prohibited without prior written consent of both Innovative Educational Services and Jodi Gootkin.



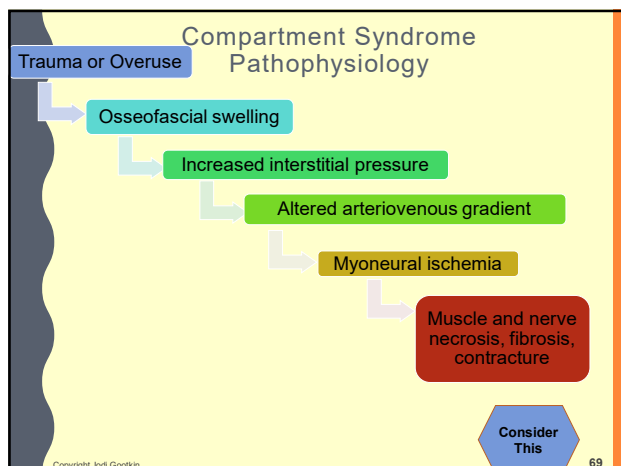
67

Compartment Syndrome

- Increased size of anatomical structures or volume within the fascial compartments of the forearm or hand can result in severe tissue damage.
- Acute – trauma, humerus supracondylar or forearm fracture, IV infiltration, burns, prolonged limb compression, animal envenomations and bites
- Chronic – overuse, Rower's Forearm

Copyright Jodi Gootkin

68



69

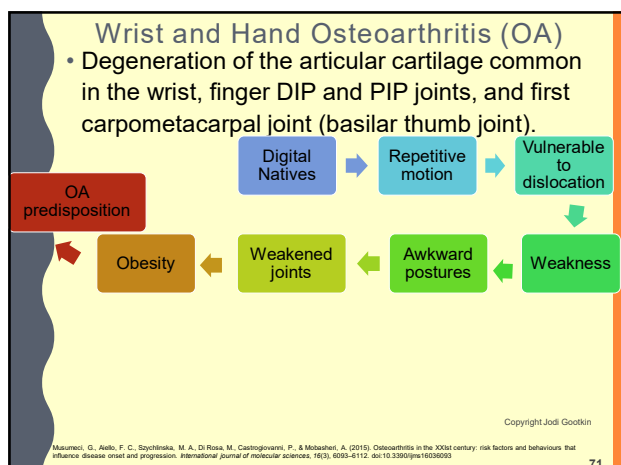
Compartment Syndrome Clinical Presentation

- Patients presenting with the "6P" findings require physician referral for rapid surgical intervention to avoid severe complications.
 - Pain disproportionate to injury
 - Paresthesia
 - Pallor
 - Paralysis
 - Poikilothermia
 - Pulselessness
- Palpable fullness of region
- Volkmann's Contracture

Kalyani, B. S., Fisher, B. E., Roberts, C. S., & Giannoudis, P. V. (2011). Compartment syndrome of the forearm: a systematic review. The Journal of hand surgery, 36(3), 535-543.

Copyright Jodi Gootkin

70



71

OA Clinical Presentation

- Hand pain, finger stiffness, reduced ROM, grip and pinch strength
- Swollen joints and deformity
 - Heberden's nodes DIP
 - Bouchard nodes PIP
 - Digital mucous cysts
 - Distal phalange and nail bed
- Positive CMC Grind Test

Copyright Jodi Gootkin

72

Wrist and Hand Disorders

Copyright Innovative Educational Services and Jodi Gootkin. All rights reserved.
Reproduction, reuse, or republication of all or any part of this presentation is strictly prohibited without prior written consent of both Innovative Educational Services and Jodi Gootkin.

OA Management

- Conservative pharmacological treatment and corticosteroid injection.
- Research varies on benefits of patient education, exercise, splinting, activity modification, ergonomic assessment.
- Surgery indicated for advanced OA of the wrist and basilar thumb joint.

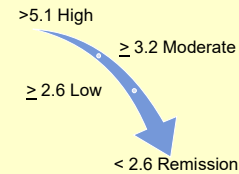
Valdes K, Mark T. A systematic review of conservative interventions for osteoarthritis of the hand. *Journal of Hand Therapy*. 2010; 23: 334–351.
 Østerås N, Kjekshus I, Smedslund G, Moe RH, Slatkowsky-Christensen B, Uhlig T, Hagen KB. (2017). Exercise for hand osteoarthritis. *Cochrane Database of Systematic Reviews* 2017, Issue 1. Art. No.: CD010388. Kloppenburg M, Kroon F. P., Blanco, F. J., Doherty, M., Dziedic, K. S., Gribbs, E. ... & Mahieu, E. (2019). 2018 update of the EULAR recommendations for the management of hand osteoarthritis. *Annals of the Rheumatic Diseases*, 78(1), 16–24.
<https://www.rheumatology.org/Practice-Quality/Clinical-Support/Clinical-Practice-Guidelines/Osteoarthritis>

Copyright Jodi Gootkin

73

Wrist and Hand Rheumatoid Arthritis (RA)

- Systemic autoimmune disease characterized by polyarticular pain, morning stiffness, fatigue, restricted range of motion, joint deformity, joint inflammation, and multiple body system compromise.
 - Bilaterally primarily small joints affected
 - Exacerbations and remissions
- Disease Activity Score (DAS28)



Copyright Jodi Gootkin

74

RA Clinical Presentation

- With chronic RA, patients experience systemic extra-articular complications.
 - Low Vision
 - Peripheral Neuropathy
 - Anemia
 - Lung Fibrosis
 - Renal Amyloidosis
 - Rheumatoid nodules in skin
 - Atherosclerosis
 - Osteoporosis

Copyright Jodi Gootkin

75

Ulnar Drift

MCP joints sublux with fingers shifting toward ulna

Swan Neck

PIP Hyperextension, DIP Flexion

Hitchhiker's Thumb

MCP Flexion, IP Extension

Boutonniere

- MCP Hyperextension, PIP Flexion, DIP Hyperextension

Copyright Jodi Gootkin

76

RA Management

- Disease modifying antirheumatic drugs (DMARD) and biologics
- Patient education on joint protection, energy conservation, adaptive equipment beneficial in managing pain.
- Therapeutic exercise may be beneficial to improve function.



Wrist Splinting
 • Improved dexterity and grip



Compression Glove
 • No benefit

<https://www.rheumatology.org/Practice-Quality/Clinical-Support/Clinical-Practice-Guidelines/Rheumatoid-Arthritis>
 Hammond A, Jones V, & Prior, Y. (2016). The effects of compression gloves on hand symptoms and hand function in rheumatoid arthritis and hand osteoarthritis: a systematic review. *Clinical rehabilitation*, 30(3), 213–224.
 Park, Y., & Chang, M. (2016). Effects of rehabilitation for pain relief in patients with rheumatoid arthritis: a systematic review. *Journal of physical therapy science*, 28(1), 304–308.
 Williams MA, Srikanthan C, Heine PJ, Bruce J, Broseau L, Hoxey-Thomas N, Lamb SE. (2018). Exercise for rheumatoid arthritis of the hand. *Cochrane Database of Systematic Reviews* 2018, Issue 7. Art. No.: CD003832

Copyright Jodi Gootkin

77

Arthritis Joint Protection

Avoid

- Tight and prolonged grasp
- Pressure on back of knuckles and tip or pad of thumb
- Repetitive activities
- Pressure on thumb side of each finger
- Prolonged periods of holding same position

Use

- Respect the pain
- Both hands when possible
- Bigger joints to complete tasks
- Pre-planning
- Splints
- Adapted equipment for looser gripping and squeezing
- Follow home exercise program
- Joins in stable position
- Slide or push objects when possible or use a cart

Bobos, P., Nazari, G., Lalone, E. A., Ferreira, L., Grenwal, R., & MacDermid, J. C. (2018). A Scoping Review of Joint Protection Programs for People with Hand Arthritis. *The Open Orthopaedics Journal*, 12(1).
 Carandang, K., Pyatak, E. A., & Vigen, C. L. P. (2016). Systematic review of educational interventions for rheumatoid arthritis. *American Journal of Occupational Therapy*, 70, 7006290020.

Copyright Jodi Gootkin

78

Wrist and Hand Disorders

Copyright Innovative Educational Services and Jodi Gootkin. All rights reserved.

Reproduction, reuse, or republication of all or any part of this presentation is strictly prohibited without prior written consent of both Innovative Educational Services and Jodi Gootkin.

Distal Radius Fracture

- Typical mechanism of injury is fall on out stretched hand (FOOSH).

Colles' Wrist in extension Dorsal Displacement

Smith's Wrist in flexion Palmar Displacement

Fragility Low energy trauma in patient with osteoporosis

Intra/extra-articular Open/closed Displace/non-displaced Simple/complex

Copyright Jodi Gootkin 79

79

AO/OTA classification

- Fractures are classified based on the location of the fracture and articular involvement.

2R3A Radius Distal Extraarticular

2R3B Radius Distal Partial Articular

2R3C Radius Distal Complete Articular

https://www2.aofoundation.org/ACF/InServer/Surgery/MyPortal/Files/7/Path/Surgery/In_docs/AO/OTA%20Classification%20Compendium%202018.pdf

Copyright Jodi Gootkin 80

80

Galeazzi vs. Monteggia Fracture

Forearm fractures identified by the bone fractured and joint dislocated. "GRI MUS"

Galeazzi

- FOOSH with elbow flexed
- Radius Fx Inferior 1/3
- Ulnar dislocation at DRUJ
- Monitor for AIN syndrome, pro/supination ROM, TFCC injury

Monteggia

- FOOSH or direct trauma in pronation
- Ulna Fx Superior 1/3
- Anterior radial head dislocation
- Monitor for limited PIN syndrome elbow ROM

Consider This

Copyright Jodi Gootkin 81

81

Pediatric Distal Radius Fractures

Buckle

- One side compresses and bends

Greenstick

- One side bends and other cracks

Metaphyseal

- Complete across shaft

Physeal

- Across growth plate

Copyright Jodi Gootkin 82

82

Salter Harris Classification

- Used to grade physeal fractures according to the involvement of the physis, metaphysis, and epiphysis

Type 1	Type 2	Type 3	Type 4	Type 5
S	A	L	T E	R
Straight through	Above	beLow	Through Everything	cRush

Copyright Jodi Gootkin 83

83

Fracture Management

- Non-displaced, extra-articular, stable fractures may be reduced and immobilized.
- Complex, displaced, intra-articular fractures require surgical stabilization through open reduction internal fixation (ORIF) or external fixation (OREF).
- During rehab monitor for shoulder pathology.

Handol. 1983; Elliott J, Theodor-Ejfor Z, Hunter J, Karantana A. Interventions for treating wrist fractures in children. Cochrane Database of Systematic Reviews 2018, Issue 12. Art. No. CD012470.

Copyright Jodi Gootkin 84

84

Wrist and Hand Disorders

Copyright Innovative Educational Services and Jodi Gootkin. All rights reserved.
 Reproduction, reuse, or republication of all or any part of this presentation is strictly prohibited
 without prior written consent of both Innovative Educational Services and Jodi Gootkin.

Fracture Complications

- Malunion or non-union
- Physeal damage in pediatrics
- Osteomyelitis
- Compression Neuropathy
- Compartment Syndrome
- Tendon Injury
- Chronic Regional Pain Syndrome (CRPS)
- Ulnar Impaction Syndrome (UIS)
- Triangular Fibrocartilage Complex Injury (TFCC)

Copyright Jodi Gootkin

85

85

Ulna Articulation at Wrist

- Although critical for hand function, the ulna is not a true joint articulation of wrist.
- The triangular fibrocartilage is an articular disc attaching on fovea of ulna and sigmoid notch of radius to separate the ulna from the lunate and triquetrum.

Copyright Jodi Gootkin

86

86

Triangular Fibrocartilage Complex (TFCC)

- TFCC is the grouping of soft tissue structures that link the radius and ulna to the hand.
- ✓ Dorsal & Volar Radioulnar Ligaments
- ✓ Ulnar Collateral Ligament Complex
- ✓ Triangular Fibrocartilage Disc
- ✓ Meniscus Homologue
- ✓ Sheath of ECU
- Its role is to stabilize distal radioulnar joint and ulnar carpals, and distribute load from the carpals to the ulna.

Copyright Jodi Gootkin

Consider This

87

87

Ulnar Variance

- Measured distance of greater than 1 mm from distal articular surfaces of radius and ulna is considered abnormal.

Positive Variance

- Ulna extends beyond radius
- Degenerative changes of ulna, fibrocartilaginous disc, and carpals.

Negative Variance

- Ulna shorter than radius
- Lunate instability and deterioration

Copyright Jodi Gootkin

88

88

Ulnar Impaction Syndrome (UIS)

- Degeneration of the ulnar head occurs from abutment against TFCC and ulnar carpals.
- Etiology is acquired positive ulnar variance from fracture, radius growth plate arrest, repetitive loading of ulnar carpus with activities.

Copyright Jodi Gootkin

89

89
Wrist and Hand Disorders

Ulnar Impaction Syndrome (UIS)

Positive ulnar variance

Ulnar carpal loading

TFCC overstretching

TFCC degeneration

Ulnar/lunate chondromalacia

Copyright Jodi Gootkin

90

90

Copyright Innovative Educational Services and Jodi Gootkin. All rights reserved.

Reproduction, reuse, or republication of all or any part of this presentation is strictly prohibited without prior written consent of both Innovative Educational Services and Jodi Gootkin.

Ulnar Impaction Syndrome Clinical Presentation

- Ulnar sided wrist pain exacerbated by forceful grip, pronation, ulnar deviation, and axial loading.
- Decreased wrist and forearm ROM
- Tenderness upon palpation of dorsal wrist near ulnar styloid and just distal to ulnar head.
- Positive Nakamura's Ulnar Stress Test
- Conservative management with splinting, activity modification, and corticosteroid injection.
- Surgical technique to alleviate impaction varies based on extent of TFCC damage and osteoarthritic changes.

Copyright Jodi Gootkin

91

91

Scaphoid Fracture

- The scaphoid proximal and distal poles are joined in the middle at the slightly narrow waist.
- FOOSH injury with impact on wrist in hyperextension and ulnar deviation generates compressive load impacting dorsal surface of scaphoid and dorsal border of distal radius.

Copyright Jodi Gootkin

92

92

Scaphoid Fracture Clinical Presentation

- Patients with distant history of trauma and current function restrictions may require referral for additional diagnostic testing.
- Tenderness, pain and swelling in the region of anatomical snuff box.
- Increased pain with pinching and grasping
- Positive Watson's Test

Copyright Jodi Gootkin

93

93

Scaphoid Fracture - Management

- Distal pole fractures can be managed with closed reduction and thumb spica cast.
- ORIF is indicated when fracture occurs at the waist or proximal pole, because the detached proximal bone fragment has a tenuous blood supply.
- Closely monitor symptoms as scaphoid is at risk for delayed, nonunion or avascular necrosis.

Consider This

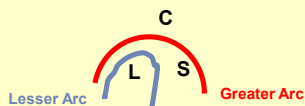
Copyright Jodi Gootkin

94

94

Carpal Arc Anatomy

- Lunate articulates with radius for wrist motion and other carpals playing a critical role in stability of carpal arcs.
- No muscles attach to the lunate so it relies on the bony architecture of its articulations with the adjacent carpals and ligamentous support for stability.



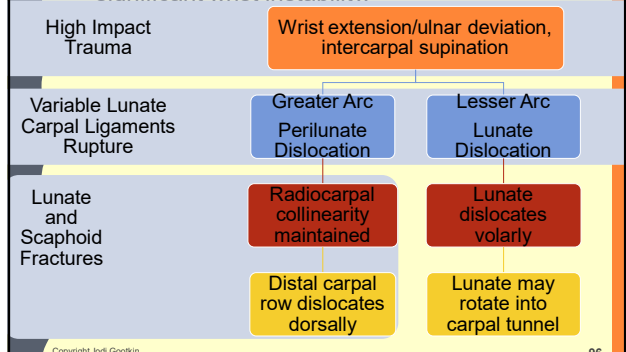
Copyright Jodi Gootkin

95

95
Wrist and Hand Disorders

Perilunate Instability

- Severe closed wrist injury resulting in significant wrist instability.



Copyright Jodi Gootkin

96

96

Copyright Innovative Educational Services and Jodi Gootkin. All rights reserved.

Reproduction, reuse, or republication of all or any part of this presentation is strictly prohibited without prior written consent of both Innovative Educational Services and Jodi Gootkin.

Perilunate Fracture-Dislocation Clinical Presentation

- Generalized wrist swelling, dorsal pain, and ROM restriction.
- Median nerve compression symptoms.
- Compartment syndrome symptoms.
- Diffuse tenderness with lunate palpation.
- Surgical intervention indicated to stabilize fractures and repair ligaments.

Copyright Jodi Gootkin

97

97

Kienbock's Disease

- Avascular necrosis of the lunate related to lunate fractures that fail to heal and osteoarthritis.
- Presents as painful stiff wrist with limited ROM, weak grip, and tenderness with lunate palpation.
- Rehabilitation will not alleviate symptoms. Immobilization in early stages may be successful with surgery indicated in advanced stages.

Copyright Jodi Gootkin

98

98

Triangular Fibrocartilage Complex Tear (TFCC)

- Injury to the complex that plays a critical role in wrist stability with grip, weight bearing, and rotational loading activities.

Type 1 Acute -Trauma

Tears and avulsion

FOOSH on pronated and extended wrist

Power drill injuries

Type 2 Chronic -Degeneration

Thinning, perforation, chondromalacia

Repetitive high wrist forces in extension and/or ulnar deviation

Age related changes

Radius fracture, UIS

Copyright Jodi Gootkin

99

99

TFCC Tear Clinical Presentation

- Ulnar sided wrist pain.
- Tenderness to palpation and swelling between pisiform and ulnar styloid process.
- Clicking with wrist ROM.
- Pain with wrist motions
 - weight bearing on extended wrist
 - resisted ulnar deviation and extension

Copyright Jodi Gootkin

100

100

TFCC Assessment

- Arthroscopy better than imaging studies to identify tear.
- Positive provocative tests noted.
 - Press Test
 - Fovea sign
 - Piano Key Sign

Lester B, Halbrecht J, Levy IM, Gaudinez R. "Press test" for office diagnosis of triangular fibrocartilage complex tears of the wrist. *Ann Plast Surg* 1995; 35:41-5.
 Andersson, J. K., Andersson, D., Karlsson, J., & Fridén, J. (2015). Efficacy of magnetic resonance imaging and clinical tests in diagnostics of wrist ligament injuries: a systematic review. *Arthroscopy: The Journal of Arthroscopic & Related Surgery*, 31(10), 2014-2020.

Copyright Jodi Gootkin

101

Consider This

101
Wrist and Hand Disorders

TFCC Tear Management

- Conservative management with splinting, corticosteroid injections and activity modification.
 - Caution when progressing pronation/supination and radial/ulnar deviation exercises.
- Surgery indicated for unresponsive or more severe tears.

Copyright Jodi Gootkin

102

102

Copyright Innovative Educational Services and Jodi Gootkin. All rights reserved.

Reproduction, reuse, or republication of all or any part of this presentation is strictly prohibited without prior written consent of both Innovative Educational Services and Jodi Gootkin.

Gamekeeper's Thumb

- Loading of the ulnar collateral ligament at the thumb MCP results injury to the ligament.
- Sustained during FOOSH when a valgus force is applied to the ABDucted thumb or chronic stress.
- May have associated conditions
 - avulsion fracture at phalanx
 - Stener lesion

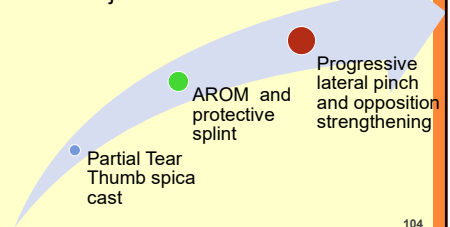
Copyright Jodi Gootkin

103

103

Gamekeeper's Thumb Clinical Presentation

- Valgus laxity of thumb MCP joint noted in extension and flexion.
- Lateral prehension painful and weak.
- Palpable swelling and tenderness along ulnar aspect thumb MCP joint.



Copyright Jodi Gootkin

104

104

Patient Reported Outcome Measures

- Used to inform treatment by screening for functional deficits and monitoring impact of therapy to personalize care for each patient.

FOTO	Focus on Therapeutic Outcomes Elbow, Wrist, and Hand
MHQ	Michigan Hand Outcomes Questionnaire
PRWE	Patient-Rated Wrist Evaluation
BCTQ	Boston Carpal Tunnel Questionnaire

Dacombe, P. J., Amirfeyz, R., & Davis, T. (2016). Patient-reported outcome measures for hand and wrist trauma: is there sufficient evidence of reliability, validity, and responsiveness? *Hand*, 11(1), 11-21.

Copyright Jodi Gootkin

105

105

Focus on Therapeutic Outcomes Elbow, Wrist, and Hand (FOTO)

- Used by Medicare to determine functional status change.
- Each item scored with sum between 10-50 that converts to functional status score of 0-100
- Are you having any difficulty carrying a shopping bag or briefcase?
- Are you having any difficulty opening a tight or new jar?

https://cdn2.hubspot.net/hub/442011/NQF/2018%20Updates/Short%20Form/Elbow%20Wrist%20Hand%20Functional%20Status_QP%23222_NQF%230427_2018.pdf

Copyright Jodi Gootkin

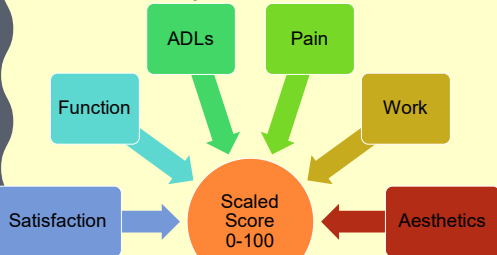
Consider This

106

106

Michigan Hand Outcomes Questionnaire(MHQ)

- 37 core questions measure hand-specific outcomes in 6 domains.



Shauver, M. J., & Chung, K. C. (2013). The Michigan hand outcomes questionnaire after 15 years of field trial. *Plastic and reconstructive surgery*, 131(5), 779e-87e. doi:10.1097/PRS.0b013e3182865d83

Chung, K.C., Pitts, M.S., Walters, M.R., Hayward, R.A. (1998). Reliability and validity testing of the Michigan Hand Outcomes Questionnaire. *Journal of Hand Surgery - American Volume*, 23(4):575-87.

Copyright Jodi Gootkin

107

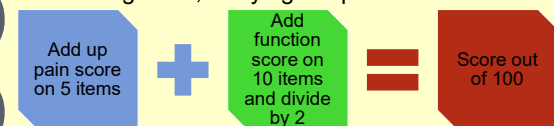
Consider This

107
Wrist and Hand Disorders

Patient Rated Wrist Evaluation (PRWE)

- Questions are intended to quantify perception of pain and disability from wrist and hand conditions.

- Pain at rest, its worst, frequency
- Cutting meat, carrying ten pounds



Mehta, S. P., MacDermid, J. C., Richardson, J., MacIntyre, N. J., & Grewal, R. (2015). Reliability and validity of selected measures associated with increased fall risk in females over the age of 45 years with distal radius fracture-A pilot study. *Journal of Hand Therapy*, 28(1), 2-10.

Mulders, M.A., Kleijpool, S.C., Dingemans, S.A., Eerten, P.V., Schepers, T., Goossens, J.C., & Schep, W.W. (2018). Normative data for the Patient-Rated Wrist Evaluation questionnaire. *Journal of hand therapy : official journal of the American Society of Hand Therapists*, 31 3, 287-294.

Copyright Jodi Gootkin

Consider This

108

108

Copyright Innovative Educational Services and Jodi Gootkin. All rights reserved.

Reproduction, reuse, or republication of all or any part of this presentation is strictly prohibited without prior written consent of both Innovative Educational Services and Jodi Gootkin.

Boston Carpal Tunnel Questionnaire (BCTQ)

- Specifically developed to be sensitive to changes in symptom severity and basic ADLs.

Symptoms	Function
1 Normal 5 Very serious	1 No difficulty 5 Can't perform
Pain, weakness, sensation	Holding book while reading, gripping phone handle

Copyright Jodi Gootkin <https://www.jospt.org/doi/full/10.2519/jospt.2019.0301> 109

109

Conclusion

- Understanding the pathophysiology and mechanism of injury for wrist and hand disorders allows the clinician to appropriately interpret symptoms.
- This will strengthen decision making that directs care and prompts communication with physicians to address potential complications.

Copyright Jodi Gootkin 110

110

1. Which low cost, high resolution diagnostic tool allows dynamic visualization of nerve entrapment with patient feedback?

- MRI
- SPECT/CT
- Ultrasonography
- Nerve Conduction Study

Copyright Jodi Gootkin 111

111

2. What condition presents with similar sensory impairments as Carpal Tunnel Syndrome?

- C6-7 Radiculopathy
- Thoracic Stenosis
- Cubital Tunnel Syndrome
- Trigger Finger

Copyright Jodi Gootkin 112

112

3. The first extensor compartment of the wrist (involved in DeQuervain's Tenosynovitis) contains a septum that separates which two tendons?

- Extensor Digitorum and Abductor Pollicis Longus
- Extensor and Flexor Carpi Ulnaris
- Flexor Digitorum Superficialis and Profundus
- Extensor Pollicis Brevis and Abductor Pollicis Longus

Copyright Jodi Gootkin 113

113

4. Which condition is suspected when the clinician palpates a firm nodule in the palm of the hand that moves with active finger flexion?

- Trigger Finger
- Dupuytren's Disease
- Gamekeepers Thumb
- Lunate Dislocation

Copyright Jodi Gootkin 114

114

Wrist and Hand Disorders

**Copyright Innovative Educational Services and Jodi Gootkin. All rights reserved.
Reproduction, reuse, or republication of all or any part of this presentation is strictly prohibited
without prior written consent of both Innovative Educational Services and Jodi Gootkin.**

5. Osseofascial swelling following trauma leading to increased interstitial pressure and myoneural ischemia describes what condition?

- A. Carpal Tunnel Syndrome
- B. Muscular Angina
- C. Compartment Syndrome
- D. Guyon's Compression

Copyright Jodi Gootkin

115

115

6. A FOOSH injury resulting in fracture of the superior/proximal shaft of the ulna with dislocation of the radial head is termed _____.

- A. Galeazzi
- B. Colles'
- C. Smith's
- D. Monteggia

Copyright Jodi Gootkin

116

116

7. What is the primary ligamentous stabilizer of the distal radioulnar joint and ulnar carpals?

- A. Flexor Retinaculum
- B. Triangular Fibrocartilage Complex
- C. Flexor Pulley System
- D. Palmar Extrinsic Ligaments

Copyright Jodi Gootkin

117

117

8. During rehabilitation from a scaphoid fracture, patients should be closely monitored for what complication?

- A. Avascular Necrosis
- B. Ulnar Impaction
- C. Nerve Entrapment
- D. Tenosynovitis

Copyright Jodi Gootkin

118

118

9. Which provocative test is utilized to assess for the integrity of the triangular fibrocartilage complex?

- A. Finklestein's
- B. Phalen's
- C. Press
- D. Valgus Laxity

Copyright Jodi Gootkin

119

119
Wrist and Hand Disorders

10. Which of the following is NOT a patient reported outcome measure that assesses the impact of wrist and hand disorders on function?

- A. FOTO
- B. VAS
- C. MHQ
- D. PRWE

Copyright Jodi Gootkin

120

120

Copyright Innovative Educational Services and Jodi Gootkin. All rights reserved.

Reproduction, reuse, or republication of all or any part of this presentation is strictly prohibited without prior written consent of both Innovative Educational Services and Jodi Gootkin.

Wrist and Hand Disorders

References

- Allahabadi, S., Kwong, J. W., Pandya, N. K., Shin, S. S., Immerman, I., & Lee, N. H. (2023). Return to play after thumb ulnar collateral ligament injuries managed surgically in athletes—a systematic review. *Journal of Hand Surgery Global Online*, 5(3), 349-357.
- Andersson, J. K., Hagert, E., & Brittberg, M. (2021). Cartilage injuries and posttraumatic osteoarthritis in the wrist: a review. *Cartilage*, 13(1_suppl), 156S-168S.
- Boccolari, P., Tedeschi, R., Platano, D., & Donati, D. (2024). Review of contemporary non-surgical management techniques for metacarpal fractures: Anatomy and rehabilitation strategies. *Orthoplastic Surgery*, 15(C), 21-23.
- Boe, C., Blazar, P., & Iannuzzi, N. (2021). Dupuytren contractures: an update of recent literature. *The Journal of Hand Surgery*, 46(10), 896-906.
- Bosman, R., Duraku, L. S., van der Oest, M. J., Hundepool, C. A., Rajaratnam, V., Power, D. M., ... & Zuidam, J. M. (2022). Surgical treatment outcome of de Quervain's disease: a systematic review and meta-analysis. *Plastic and Reconstructive Surgery—Global Open*, 10(5), e430.
- Bradet-Levesque, I., Audet, J., Roy, J. S., & Flamand, V. H. (2022). Measuring functional outcome in Dupuytren's disease: A systematic review of patient-reported outcome measures. *Journal of Hand Therapy*, 35(4), 613-627.
- Cereceda Muriel, C., Ramírez Donoso, S., Cárdenas Caniqueo, M., Silva Alfaro, V., & Concha Valdebenito, D. (2024). Effectiveness of manual therapy in carpal tunnel syndrome: Systematic review and meta-analysis. *Cultura_Ciencia_Deporte [CCD]*, 19(59).
- Cevik, J., Keating, N., Hornby, A., Salehi, O., Seth, I., & Rozen, W. M. (2024). Corticosteroid injection versus immobilisation for the treatment of De Quervain's tenosynovitis: a systematic review and meta-analysis. *Hand Surgery and Rehabilitation*, 101694.
- Challoumas, D., Ramasubbu, R., Rooney, E., Seymour-Jackson, E., Putti, A., & Millar, N. L. (2023). Management of de Quervain tenosynovitis: a systematic review and network meta-analysis. *JAMA Network Open*, 6(10), e2337001-e2337001.
- Chang, A. L., Merkow, D. B., Bookman, J. S., & Glickel, S. Z. (2023). Thumb metacarpophalangeal joint ulnar collateral ligament injuries: management and biomechanical evaluation. *JAAOS-Journal of the American Academy of Orthopaedic Surgeons*, 31(1), 7-16.
- Chhabra, A. B., & Yildirim, B. (2021). Adult distal radius fracture management. *JAAOS-Journal of the American Academy of Orthopaedic Surgeons*, 29(22), e1105-e1116.
- Choi, S. I., Malik, S., & MacLean, S. (2024). The Natural History of Non-operatively Treated Traumatic Triangular Fibrocartilage Complex Tears: A Systematic Review. *Journal of Wrist Surgery*, 13(06), 550-558.
- Chong, H. H., Pradhan, A., Dhingra, M., Liong, W., Hau, M. Y., & Shah, R. (2024). Advancements in de Quervain tenosynovitis management: a comprehensive network meta-analysis. *The Journal of Hand Surgery*, 49(6), 557-569.
- Currie, K. B., Tadisina, K. K., & Mackinnon, S. E. (2022). Common hand conditions: a review. *Jama*, 327(24), 2434-2445.
- Denkler, K. A., Park, K. M., & Alser, O. (2022). Treatment options for Dupuytren's disease: tips and tricks. *Plastic and Reconstructive Surgery—Global Open*, 10(1), e4046.
- Deshmukh, S. R., Mousoulis, C., Marson, B. A., Grindlay, D., Karantana, A., & Core Outcome Set for Hand Fractures and Joint Injuries in Adults Group. (2021). Developing a core outcome set for hand fractures and joint injuries in adults: a systematic review. *Journal of hand surgery (European volume)*, 46(5), 488-495.
- Fahy, K., & Duffaut, C. J. (2022). Hand and wrist fractures. *Current sports medicine reports*, 21(10), 345-346.
- Fernando, J. J., Fowler, C., Graham, T., Terry, K., Grocott, P., & Sandford, F. (2024). Pre-operative hand therapy management of Dupuytren's disease: A systematic review. *Hand Therapy*, 29(2), 52-61.
- Geoghegan, L., Man, J., Jain, A., Price, A., Gibbons, E., Jerosch-Herold, C., ... & Rodrigues, J. N. (2021). Factors associated with the development, progression, and outcome of Dupuytren disease treatment: a systematic review. *Plastic and reconstructive surgery*, 148(5), 753e-763e.

- Gutiérrez-Espinoza, H., Araya-Quintanilla, F., Olguín-Huerta, C., Valenzuela-Fuenzalida, J., Gutiérrez-Monclus, R., & Moncada-Ramírez, V. (2022). Effectiveness of manual therapy in patients with distal radius fracture: a systematic review and meta-analysis. *Journal of Manual & Manipulative Therapy*, 30(1), 33-45.
- Gutiérrez-Espinoza, H., Araya-Quintanilla, F., Olguín-Huerta, C., Gutiérrez-Monclus, R., Valenzuela-Fuenzalida, J., Román-Veas, J., & Campos-Jara, C. (2022). Effectiveness of surgical versus conservative treatment of distal radius fractures in elderly patients: A systematic review and meta-analysis. *Orthopaedics & Traumatology: Surgery & Research*, 108(5), 103323.
- Hassan, A., Beumer, A., Kuijter, P. P. F., & van der Molen, H. F. (2022). Work-relatedness of carpal tunnel syndrome: Systematic review including meta-analysis and GRADE. *Health science reports*, 5(6), e888.
- Jahn, A., Andersen, J. H., Descatha, A., & Dalbøge, A. (2024). Dupuytren's disease and occupational mechanical exposures: a systematic review and meta-analysis. *Occupational and Environmental Medicine*, 81(10), 535-542.
- Jansen, M. C., Duraku, L. S., Hundepool, C. A., Power, D. M., Rajaratnam, V., Selles, R. W., & Zuidam, J. M. (2022). Management of recurrent carpal tunnel syndrome: systematic review and meta-analysis. *The Journal of hand surgery*, 47(4), 388-e1.
- Kamal, R. N., & Shapiro, L. M. (2022). American Academy of Orthopaedic Surgeons/American society for surgery of the hand clinical practice guideline summary management of distal radius fractures. *JAAOS-Journal of the American Academy of Orthopaedic Surgeons*, 30(4), e480-e486.
- Keller, M. M., Barnes, R., Brandt, C., & Hepworth, L. M. (2021). Hand rehabilitation programmes for second to fifth metacarpal fractures: A systematic literature review. *The South African journal of physiotherapy*, 77(1), 1536.
- Kim, J. S., Hussain, K., Higginbotham, D. O., & Tsai, A. G. (2021). Management of thumb carpometacarpal joint dislocations: A systematic review. *Journal of Orthopaedics*, 25, 59-63.
- Leow, M. Q. H., Zheng, Q., Shi, L., Tay, S. C., & Chan, E. S. (2021). Non-steroidal anti-inflammatory drugs (NSAIDs) for trigger finger. *Cochrane Database of Systematic Reviews*, (4).
- Lim, R. Q., Lim, L. J., Atzei, A., & Liu, B. (2024). Current concepts and new trends in management of isolated triangular fibrocartilage complex injuries. *Journal of Hand Surgery (European Volume)*, 49(9), 1067-1077.
- Liu, E. H., Suen, K., Tham, S. K., & Ek, E. T. (2021). Surgical repair of triangular fibrocartilage complex tears: a systematic review. *Journal of Wrist Surgery*, 10(01), 070-083.
- Malakootian, M., Soveizi, M., Gholipour, A., & Oveisee, M. (2023). Pathophysiology, diagnosis, treatment, and genetics of carpal tunnel syndrome: a review. *Cellular and molecular neurobiology*, 43(5), 1817-1831.
- Nann, S., Kovoov, J., Fowler, J., Kieu, J., Gupta, A., Hewitt, J., ... & Maddern, G. (2024). Surgical management of Dupuytren disease: a systematic review and network meta-analyses. *Hand*, 19(8), 1283-1292.
- Normand, M., Tang, T. S., Brismée, J. M., & Sobczak, S. (2021). Clinical evaluation of thumb base osteoarthritis: a scoping review. *Hand Therapy*, 26(2), 63-78.
- Osiak, K., P. Elnazir, J. A. Walocha, and A. J. F. M. Pasternak. "Carpal tunnel syndrome: state-of-the-art review." *Folia morphologica* 81, no. 4 (2022): 851-862.
- Pace, V., Bronzini, F., Novello, G., Mosillo, G., & Braghiroli, L. (2024). Review and update on the management of triangular fibrocartilage complex injuries in professional athletes. *World journal of orthopedics*, 15(2), 110.
- Padua, L., Cuccagna, C., Giovannini, S., Coraci, D., Pelosi, L., Loreti, C., ... & Hobson-Webb, L. D. (2023). Carpal tunnel syndrome: updated evidence and new questions. *The Lancet Neurology*, 22(3), 255-
- Paraskevopoulos, E., Karanasios, S., Gioftos, G., Tatsios, P., Koumantakis, G., & Papandreou, M. (2023). The effectiveness of neuromobilization exercises in carpal tunnel syndrome: Systematic review and meta-analysis. *Physiotherapy theory and practice*, 39(10), 2037
- Pompeu, Y., Almeida, B. A., Kunze, K., Altman, E., & Fufa, D. T. (2021). Current concepts in the management of advanced trigger finger: a critical analysis review. *JBJS reviews*, 9(9), e21.
- Pradhan, S., Chiu, S., Burton, C., Forsyth, J., Corp, N., Paskins, Z., ... & Babatunde, O. O. (2022). Overall effects and moderators of rehabilitation in patients with wrist fracture: a systematic review. *Physical Therapy*, 102(6), pzac032.
- Rabinovich, R. V., Polatsch, D. B., Shin, S. S., & Beldner, S. (2021). Thumb carpometacarpal instability. *JAAOS-Journal of the American Academy of Orthopaedic Surgeons*, 29(22), 943-950.

- Ryan, L., & Doody, O. (2024). The treatment, outcomes and management of hand, wrist, finger, and thumb injuries in the professional/amateur contact sport athletes: A scoping review. *International Journal of Orthopaedic and Trauma Nursing*, 101108.
- Qin, Y., Luo, D., Qiu, H., Zhang, J., Yong, H., & Yu, S. (2024). A systematic review and meta-analysis of acupuncture for De Quervain's tenosynovitis treatment. *Postgraduate Medical Journal*, 100(1188), 709-720.
- Ramchandani, J., Thakker, A., & Tharmaraja, T. (2022). Time to reconsider occupation induced de Quervain's tenosynovitis: an updated review of risk factors. *Orthopedic Reviews*, 14(3), 36911.
- Ruettermann, M., Hermann, R. M., Khatib-Chahidi, K., & Werker, P. M. (2021). Dupuytren's disease—etiology and treatment. *Deutsches Ärzteblatt International*, 118(46), 781.
- Sandler, A. B., Scanaliato, J. P., Dennis, T., Gonzalez Trevizo, G. A., Raiciulescu, S., Nesti, L., & Dunn, J. C. (2022). Treatment of Dupuytren's contracture with collagenase: a systematic review. *Hand*, 17(5), 815-824.
- Schachinger, F., & Farr, S. (2021). Arthroscopic treatment results of triangular fibrocartilage complex tears in adolescents: a systematic review. *Journal of Clinical Medicine*, 10(11), 2363
- Schaefer, L., Maffulli, N., Baroncini, A., Eschweiler, J., Hildebrand, F., & Migliorini, F. (2022). Local corticosteroid injections versus surgical carpal tunnel release for carpal tunnel syndrome: systematic review and meta-analysis. *Life*, 12(4), 533.
- Shen, O., Chen, C. T., Jupiter, J. B., Chen, N. C., & Liu, W. C. (2023). Functional outcomes and complications after treatment of distal radius fracture in patients sixty years and over: A systematic review and network meta-analysis. *Injury*, 54(7), 110767.
- Sobeeh, M. G., Ghozy, S., Elshazli, R. M., & Landry, M. (2022). Pain mechanisms in carpal tunnel syndrome: a systematic review and meta-analysis of quantitative sensory testing outcomes. *Pain*, 163(10), e1054-e1094.
- Suwannaphisit, S., & Chuaychoosakoon, C. (2022). Effectiveness of surgical interventions for treating de Quervain's disease: A systematic review and meta-analysis. *Annals of Medicine and Surgery*, 77, 103620.
- Trillos-Chacón, M. C., Castillo-M, J. A., Tolosa-Guzman, I., Medina, A. F. S., & Ballesteros, S. M. (2021). Strategies for the prevention of carpal tunnel syndrome in the workplace: A systematic review. *Applied ergonomics*, 93, 103353.
- van der Post, A. S., Jens, S., Daams, J. G., Obdeijn, M. C., Maas, M., & Oostra, R. J. (2022). The triangular fibrocartilage complex in the human wrist: A scoping review toward uniform and clinically relevant terminology. *Clinical Anatomy*, 35(5), 626-648.
- Wong, C. R., Huynh, M. N., Fageeh, R., & McRae, M. C. (2022). Outcomes of management of recurrent Dupuytren contracture: a systematic review and meta-analysis. *Hand*, 17(6), 1104-1113.
- Wong, A. L., Wong, M. J., Parker, R., & Wheelock, M. E. (2022). Presentation and aetiology of paediatric trigger finger: a systematic review. *Journal of Hand Surgery (European Volume)*, 47(2), 192-196.
- Xiao, A. X., Graf, A. R., Dawes, A., Daley, C., Wagner, E. R., & Gottschalk, M. B. (2021). Management of acute distal radioulnar joint instability following a distal radius fracture: a systematic review and meta-analysis. *Journal of Hand Surgery Global Online*, 3(3), 133-138.
- Yazdani, A., Nasri, P., & Mahdavi, S. B. (2024). The Effects of Shock Wave Therapy on the Symptoms and Function of Individuals With Dupuytren Disease: A Systematic Review. *Archives of Physical Medicine and Rehabilitation*, 105(10), 1985-1992.