

# WRIST AND HAND DISORDERS

Presented By  
**Jodi Gootkin, PT, MED, CEAS**  
 jodiemail@comcast.net

Copyright Jodi Gootkin 2021

1

## Course Overview

This course includes a review of current literature relating to pathophysiology, arthrokinematics, diagnostic procedures, and clinical presentation for pathologies of the wrist and hand.

Copyright Jodi Gootkin 2021

2

## Course Rationale

- The purpose of this course is to provide an understanding of the pathophysiology of wrist and hand pathologies with comparative analysis of pathogenesis and clinical presentation to understand rehabilitation considerations and maximize outcomes based on current research.

Copyright Jodi Gootkin 2021

3

## Goals and Objectives

- List and identify common anatomical structures of the wrist and hand.
- Identify normal and abnormal wrist and hand arthrokinematics.
- Compare imaging and neurodiagnostic studies utilized to diagnose wrist and hand pathologies.
- Recognize and define common pathologies involving the joints, bones, ligaments, tendons, nerves, and fascia of the wrist and hand.
- Distinguish the mechanism of injury and pathogenesis for common wrist and hand disorders.
- Describe adult and pediatric fracture classifications.
- Describe the clinical presentation of common wrist and hand pathologies.
- Detail provocative tests utilized to assess pathologies of the wrist and hand.
- List management strategies for pathologies of the wrist and hand.
- Compare and contrast wrist and hand patient reported outcome measures.

Copyright Jodi Gootkin 2021

4

## Disclaimer

- Application of concepts presented in this webinar is at the discretion of the individual participant in accordance with federal, state, and professional regulations.

Copyright Jodi Gootkin 2021

5

## Course Outline and Schedule

Topic	Time
Wrist and Hand Anatomy and Arthrokinematics	0:00-0:10
Imaging and Neurodiagnostic Studies	0:11-0:25
Nerve Compression Pathology	0:26-0:30
Carpal Tunnel Syndrome	0:31-0:35
Interosseous Nerve Syndrome	0:36-0:40
Guyon's Canal Syndrome	0:41-0:45
Cubital Tunnel Syndrome	0:46-0:50
<b>Interactive Discussion of Clinical Applications</b>	<b>0:51-1:00</b>
Tendon and Fascia Pathology	1:01-1:05
De Quervain's Tenosynovitis	1:06-1:10
Trigger Finger and Thumb	1:11-1:15
Dupuytren's Disease	1:16-1:20
Compartment Syndrome	1:21-1:25
Bone and Joint Pathology	1:26:1:30
Osteoarthritis	1:31-1:35
Rheumatoid Arthritis	1:36-1:40
Distal Radius Fractures	1:41:1:45
Pediatric Fractures	1:46-1:50
<b>Interactive Discussion of Clinical Applications</b>	<b>1:51-2:00</b>
Ulnar Impaction Syndrome	2:00-2:10
Scaphoid Fracture	2:11-2:15
Perilunate Instability	2:16-2:20
Kienbock's Disease	2:21-2:25
Ligament Injuries	2:26-2:30
Triangular Fibrocartilage Complex Tear	2:31-2:35
Gamekeeper's Thumb	2:36-2:40
Patient Reported Outcome Measures	2:41-2:50
<b>Interactive Discussion of Clinical Applications</b>	<b>2:51-3:00</b>

Copyright Jodi Gootkin 2021

6

### Wrist and Hand Function

- The wrist serves as a stabilizer or moving segment for functional use of the hand to occur.

Copyright Jodi Gootkin 2021

8

### Wrist and Hand Anatomy

- Proximal to Distal

Radius and Ulna	Radiocarpal Joint (Wrist)	Proximal and Distal Radioulnar Joints (PRUJ, DRUJ)
Carpals	Midcarpal Joint	Intercarpal Joints
Metacarpals	Metacarpal Phalangeal Joint (MCP)	
Phalanges	Proximal and Distal Interphalangeal Joint (PIP, DIP)	Thumb Interphalangeal Joint (IP)

Copyright Jodi Gootkin 2021

9

### Carpal Bones

- The 8 small bones are arranged into a proximal and distal row.
- Clockwise from Thumb:
  - Straight Line To Pinky, Here Comes The Thumb
- Counter clockwise from Pinky:
  - PTs Love Sundaes, Ten Toppings Can't Hurt

Copyright Jodi Gootkin 2021

10

<h3>Radiocarpal Joint</h3> <ul style="list-style-type: none"> <li>Articulation between biconcave surface of radius with scaphoid and lunate.</li> </ul>	<h3>Distal Radioulnar Joint (DRUJ)</h3> <ul style="list-style-type: none"> <li>Articular cartilage covered ulnar head and radial sigmoid notch glide with minimal intrinsic stability from bony architecture.</li> </ul>
---	--

Copyright Jodi Gootkin 2021

11

### Normal Arthrokinematics

- Three dimensional movements between the carpals contribute to global wrist motion.
  - Flexion and Extension
  - Radial and Ulnar Deviation
  - Pronation and Supination
- Research varies on whether the proximal or distal row of carpals contributes more to wrist ROM.
  - Consider goniometry measurement using dorsal versus lateral hand placement.

Copyright Jodi Gootkin 2021

12

### Functional Task Analysis

- Wrist range of motion (ROM) required for functional tasks varies by individual.
  - Personal Hygiene
    - 50 degrees flexion to 40 degrees extension
  - Feeding
    - 35 – 40 degrees extension
  - Typing
    - 10 degrees extension
  - Sit to stand
    - 50-60 degrees extension
  - Wheelchair propulsion and assistive devices
    - Excessive compressive force and altered wrist mechanics

Copyright Jodi Gootkin 2021 13

13

### Structure Allows Function

- Proposed that morphological changes during evolution permitted Homo sapien performance of improved hunting, gathering, and protection.
- MCP/CMC rotation
  - Three jaw chuck
- Shorter and mobile 5<sup>th</sup> metacarpal
  - Power grip

Copyright Jodi Gootkin 2021 14

14

### Dart Throwers Motion (DTM)

- Movement of the wrist in an oblique motion to the anatomical axis from radial extension to ulnar flexion similar to the movement performed when throwing a dart.
- Biomechanically the proximal row of carpals form a stable base allowing motion primarily at the midcarpal joint.
- Utilized in tasks requiring forceful upper extremity demands and many activities of daily living (ADL).

Copyright Jodi Gootkin 2021 15

15

### Goniometry DTM

- Goniometric alignment of this composite motion is challenging.
- Proposed alignment:
  - Position: elbow flexion and forearm neutral
  - Axis: radiocarpal joint
  - Stationary arm: lateral border of radius
  - Moving arm: dorsal second metacarpal

Vardakastani, V., Bell, H., Mee, S., Briggstocke, G., & Kedgley, A. E. (2018). Clinical measurement of the dart throwing motion of the wrist: variability, accuracy and correction. *The Journal of hand surgery, European volume*, 43(7), 723–731.

Copyright Jodi Gootkin 2021 16

16

### Wrist and Hand Musculature

Forearm	<ul style="list-style-type: none"> <li>• Pronator Teres and Quadratus</li> <li>• Supinator</li> </ul>
Wrist	<ul style="list-style-type: none"> <li>• Palmaris Longus, Flexor Carpi Radialis and Ulnaris</li> <li>• Extensor Carpi Ulnaris, Radialis Longus and Brevis</li> </ul>
Extrinsic Hand	<ul style="list-style-type: none"> <li>• Extensor Digitorum, Indicis, Digiti Minimi</li> <li>• Flexor Digitorum Superficialis and Profundus</li> <li>• Extensor Pollicis Longus and Brevis, Flexor, Abductor Pollicis Longus</li> </ul>
Intrinsic Hand	<ul style="list-style-type: none"> <li>• Thenar and Hypothenar Eminence</li> <li>• Lumbricals, Dorsal and Palmar Interossei</li> </ul>

Copyright Jodi Gootkin 2021 17

17

### Imaging and Neurodiagnostic Studies

Copyright Jodi Gootkin 2021 18

18

### Skeletal Age Assessment

- Determination of skeletal maturity based on radiographic assessment of hand bone ossification.
- Several scoring systems are utilized
  - Greulich and Pyle (GP) utilizes a single standardized image for a range of age of each gender for comparison and determination.
  - Tanner-Whitehouse (TW) scores each carpal, radius and ulna for a total score to estimate age.
  - Computer automated assessment tools are being developed.

Copyright Jodi Gootkin 2021 19

19

### Skeletal Age Implications

- Delayed or advanced bone age compared to chronological age is correlated with clinical presentation and other diagnostic tests.

<b>Endocrine conditions</b>	• Constitutional delay, hypothyroidism, growth hormone deficiency, Cushing disease
<b>Nutritional disorders</b>	• Malnutrition
<b>Genetic syndromes</b>	• Trisomies, Turner syndrome, Klinefelter syndrome
<b>Nonendocrine chronic disease</b>	• Inflammatory bowel disease, cystic fibrosis, chronic kidney disease, neglect and abuse
<b>Chronologic age estimation</b>	• When birth records unavailable
<b>Orthodontics</b>	• Dental implants

Copyright Jodi Gootkin 2021 20

20

### Radiography (X-ray) vs. Computed Tomography (CT)

- Radiography is the first screening tool utilized to assess acute traumatic and hand injuries.
- Some research suggests it may underestimate intra-articular distal radius fracture severity or leave carpal fractures unnoticed.

Copyright Jodi Gootkin 2021 21

21

### Radiography vs. Multiple Detector Computer Tomography (MDCT)

- Assembles multiple CT images into a more 3D image for detection of the complex hand anatomy.

Copyright Jodi Gootkin 2021 22

22

### Single Photon Emission Computed Tomography/Computed Tomography SPECT/CT

- Combining two imaging studies during one scan provides information on morphological structure, metabolic activity, and precise location of lesions.

Copyright Jodi Gootkin 2021 23

23

### MRI

- Correlation of clinical presentation and radiographs can aid physician in determination of the need for MRI to identify soft tissue pathology.
- Considered to be more precise in identifying occult fractures when x-ray is negative.

Copyright Jodi Gootkin 2021 24

24

### Active MRI

- This dynamic imaging technique permits movement during scanning.
- The multiple images captured each second are strung together to create a movie of the wrist motion performed.
- Allows closer analysis of complex wrist and hand motions particularly instability.

Copyright Jodi Gootkin 2021 25

25

### Electrophysiologic Studies

- In some states, physical therapists may perform these studies with varying restrictions.
  - Specific education training is required
  - Cannot diagnose based on results

NCS  
Nerve Conduction Study

- Speed of nerve signal transmission.
- Electrodes applied superficially to skin.

EMG  
Electromyography

- Electrical activity at rest and during contraction.
- Small needles inserted into muscle.

Copyright Jodi Gootkin 2021 26

26

### Ultrasound

- Allows visualization of the entire course of a peripheral nerve in the extremity in a short time.
- Tendon thickening, effusion, and calcification can be identified.
- Diagnostic accuracy is increased as pressure from transducer may elicit patient feedback on clinical symptoms that are elicited.

Consider This

Copyright Jodi Gootkin 2021 27

27

### Nerve Ultrasound

- Dynamic imaging permits observation of nerve deformation and displacement during range of motion.

Copyright Jodi Gootkin 2021 28

28

### Provocative Tests

- Selectively manipulating tissues to evoke characteristics of different neurologic or musculoskeletal conditions to determine their presence.

Copyright Jodi Gootkin 2021 29

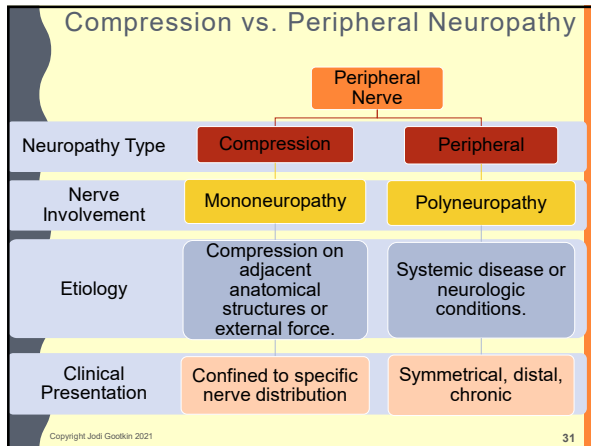
29

### Common Pathologies

Nerve	<ul style="list-style-type: none"> <li>• Carpal Tunnel Syndrome</li> <li>• Interosseous Nerve Syndrome</li> <li>• Guyon's Canal Syndrome</li> <li>• Cubital Tunnel Syndrome</li> </ul>
Tendon	<ul style="list-style-type: none"> <li>• DeQuervain's Tenosynovitis</li> <li>• Trigger Finger or Thumb</li> </ul>
Fascia	<ul style="list-style-type: none"> <li>• Dupuytren's Disease</li> <li>• Compartment Syndrome</li> </ul>
Bone/Joint	<ul style="list-style-type: none"> <li>• Osteoarthritis and Rheumatoid Arthritis</li> <li>• Distal Radius Fracture</li> <li>• Pediatric Fractures</li> <li>• Ulnar Impaction Syndrome</li> <li>• Scaphoid Fracture</li> <li>• Perilunate Instability</li> <li>• Kienbock's Disease</li> </ul>
Ligament	<ul style="list-style-type: none"> <li>• Triangular Fibrocartilage Complex Tear</li> <li>• Gamekeeper's Thumb</li> </ul>

Copyright Jodi Gootkin 2021 30

30



31

### Compression Neuropathy

- Entrapment of the peripheral nerve can occur at various intervals down the extraspinal path of the nerve.
- Differential diagnosis based on motor and sensory impairments isolates the location of the compression.

Copyright Jodi Gootkin 2021 32

32

### Space Occupying Lesion

- Ganglion cysts are benign fluid filled soft tissue swellings that form near tendons and joint capsules which can encroach on local nerves.

Copyright Jodi Gootkin 2021 33

33

### Flexor Retinaculum

- Supports the carpal arch attaching medially to the pisiform and hook of the hamate bridging to the trapezium and scaphoid.
- The carpal tunnel created is encased with the visceral and parietal synovial layers and contains:
  - ✓ Median Nerve
  - ✓ Flexor Digitorum Profundus
  - ✓ Flexor Digitorum Superficialis
  - ✓ Flexor Pollicis Longus

Copyright Jodi Gootkin 2021 34

34

### Carpal Tunnel Syndrome (CTS)

- Mononeuropathy with entrapment of the median nerve in the carpal tunnel of the wrist results weakness and altered sensation of the hand .
- Diagnosed clinically and confirmed by electromyography (EMG), nerve conduction study (NCS) and ultrasonography (US).

Copyright Jodi Gootkin 2021 35

35

### CTS Etiology

- Thickening of transverse carpal ligament or tendon sheaths, altered bony architecture, or other encroachment compresses median nerve.

Idiopathic	
Traumatic	Subluxation of lunate, wrist fracture
Inflammatory conditions	Rheumatoid arthritis
Endocrine	Diabetes, hypothyroidism, menopause, pregnancy
Space occupying lesions	Ganglions, tumors
Vascular conditions	Hemophilia, anticoagulants
Obesity	High BMI
Overuse	Tenosynovial hypertrophy of flexor tendons

Copyright Jodi Gootkin 2021 36

36

### CTS Risk With Functional Tasks

- No strong association has been noted between computer tasks and CTS.

Hand Force, Repetition, Combined Exposure, Vibration

Newington, L., Harris, E. C., & Walker-Bone, K. (2015). Carpal tunnel syndrome and work. *Best practice & research. Clinical rheumatology*, 29(3), 440-453. doi:10.1016/j.berh.2015.04.026

Copyright Jodi Gootkin 2021

37

### CTS Non-inflammatory Synovial Thickening

Nerve compression, Repetitive motion, Tendon shear strain, Tissue healing less elastic more fibrous, Subsynovial connective tissue thickening, tenosynovial ischemia, Increase tunnel pressure

Copyright Jodi Gootkin 2021

38

### CTS Pathomechanics

- Decreased functional space of carpal tunnel or increased volume of contents develops.
- With active wrist and finger flexion increased tunnel pressure occurs.
- Diminished ability for the median nerve to slide.

Copyright Jodi Gootkin 2021

39

### Progressive Nerve Compression Symptoms

Pain, Paresthesia • Altered sensation, Dysesthesia • Burning, Aesthesia • Loss of sensation, Motor weakness

Copyright Jodi Gootkin 2021

40

### CTS Sensory Presentation

- Numbness, tingling, burning, pain, loss of 2-point discrimination
  - Palmar surface and dorsal nail bed of thumb, index, middle, and radial side of ring finger.
- NOT sensory changes to thenar eminence region
- Nocturnal pain

Copyright Jodi Gootkin 2021

41

### CTS Motor Impairment

- Weak grip, pinch, opposition, and thumb ABDuction.
- "Meat-LOAF" muscles
  - Meat – Median nerve
  - L – lumbricals 1 and 2
  - O – opponens pollicis
  - A – abductor pollicis brevis
  - F – flexor pollicis brevis
- Positive Benediction sign
- Ape hand
- Thenar atrophy rules in CTS but does not rule it out

Copyright Jodi Gootkin 2021

42

### CTS Provocative Tests

- Positive Median Nerve provocative testing not recommended as independent indicators.
  - Tinel's Sign (at wrist)
  - Phalen's Test
- Upper Limb Neural Tension (ULNT) Median Nerve
  - Conflicting interpretation related to CTS

Baselgia, L. T., Bennett, D. L., Silbiger, R. M., & Schmid, A. B. (2017). Negative Neurodynamic Tests Do Not Exclude Neural Dysfunction in Patients With Entrapment Neuropathies. *Archives of physical medicine and rehabilitation*, 98(3), 480–486. doi:10.1016/j.apmr.2016.08.019  
American Academy of Orthopaedic Surgeons. (2013). Appropriate Use Criteria for Treatment of Distal Radius Fractures. Rosemont, IL: American Academy of Orthopaedic Surgeons, 27-41.

Copyright Jodi Gootkin 2021 43

43

### CTS Differential Diagnosis

- Be precise with sensory assessment and isolated muscle testing to distinguish clinical presentation.
  - Cervical radiculopathy C6-C7
  - Lower brachial plexus injury
  - Nerve injury following upper extremity fracture
  - Diabetic neuropathy

Nee, R. J., Jull, G. A., Vicenzino, B., & Coppiters, M. W. (2012). The validity of upper-limb neurodynamic tests for detecting peripheral neuropathic pain. *Journal of orthopaedic & sports physical therapy*, 42(5), 413-424.

Copyright Jodi Gootkin 2021 **Consider This** 44

44

### CTS Conservative Management

- NSAIDs, diuretics, acupuncture NOT effective.
- Corticosteroid injections are beneficial.

1-2 weeks	3-6 weeks	7-8 weeks	Beyond 8 weeks
<ul style="list-style-type: none"> <li>• Nocturnal splint, daytime with aggravating activities</li> <li>• Stretching, strengthening, soft tissue mobilization, tendon/nerve gliding</li> <li>• Activity modification</li> </ul>	<ul style="list-style-type: none"> <li>• Decrease splint use</li> <li>• Progressive therapy</li> <li>• Increase task performance</li> </ul>	<ul style="list-style-type: none"> <li>• Decrease splint use</li> <li>• Increase home program</li> <li>• Decrease therapy frequency</li> <li>• Resume normal work activity</li> </ul>	<ul style="list-style-type: none"> <li>• Progress to discharge</li> <li>• Inadequate improvement: potential surgical candidate</li> </ul>

Choi, G.H., Wieland, L.S., Lee, H., Sim, H., Lee, M.S., Shin, B.C. Acupuncture and related interventions for the treatment of symptoms associated with carpal tunnel syndrome. *Cochrane Database of Systematic Reviews* 2019, Issue 12, Art. No. CD012125. DOI: 10.1002/14651858.CD012125.pub2  
American Academy of Orthopaedic Surgeons. (2013). Appropriate Use Criteria for Treatment of Distal Radius Fractures. Rosemont, IL: American Academy of Orthopaedic Surgeons, 27-41.  
Huustede, B. M., Friden, J., Coert, J. H., Hoogvliet, P., & European HANDGUIDE Group. (2014). Carpal tunnel syndrome: hand surgeons, hand therapists, and physical medicine and rehabilitation physicians agree on a multidisciplinary treatment guideline—results from the European HANDGUIDE Study. *Archives of physical medicine and rehabilitation*, 95(12), 2253-2263.

Copyright Jodi Gootkin 2021 45

45

### CTS Splinting

- Nocturnal splinting and daytime splinting when performing aggravating activities
- No consensus on splint design
  - Neutral splint or cock-up
  - With or without lumbrical extension

American Academy of Orthopaedic Surgeons. (2013). Appropriate Use Criteria for Treatment of Distal Radius Fractures. Rosemont, IL: American Academy of Orthopaedic Surgeons, 27-41.  
Page, M.J., Masay-Westropo, N., O'Connor, D., Pitt, V. Splinting for carpal tunnel syndrome. *Cochrane Database Syst Rev*. 2012 Jul 11;7:CD010003. doi: 10.1002/14651858.CD010003.

Copyright Jodi Gootkin 2021 46

46

### Anterior Interosseous Nerve (AIN) Syndrome

- Compression of branch of median nerve traveling just distal to the pronator teres in the anterior compartment of the forearm.
  - Flexor Pollicis Longus (FPL), index and middle finger flexor digitorum superficialis (FDS), and pronator quadratus (PQ)

Trauma Etiology	Compression Etiology
<ul style="list-style-type: none"> <li>Fracture</li> <li>Penetrating Injuries</li> <li>Venipuncture</li> <li>Surgery</li> </ul>	<ul style="list-style-type: none"> <li>Lipoma or ganglion</li> <li>Compartment syndrome</li> <li>Cast pressure</li> </ul>

Copyright Jodi Gootkin 2021 47

47

### AIN Syndrome Clinical Presentation

- Dull pain on anterior aspect of proximal forearm.
- Sensation remains intact.
- Muscle weakness of thumb, index and middle finger flexion.
  - Positive OK sign
- Assess tenodesis to distinguish from FPL rupture.

Copyright Jodi Gootkin 2021 48

48



### Posterior Interosseous Nerve (PIN) Syndrome

- Compressive neuropathy of the deep branch of the radial nerve near the supinator muscle.
- Etiology may be insidious or specific trauma, space occupying lesion, or overuse of supination/pronation.

Copyright Jodi Gootkin 2021

49

### PIN Syndrome Clinical Presentation

- Sensation remains intact but may present with pain.
- Palpable tenderness over arcade of Frohse.
- Distinguish from lateral epicondylitis.
  - Weak finger extension and wrist extension with radial drift
  - Unable to “rock on”

Copyright Jodi Gootkin 2021

50

### Guyon’s Canal Syndrome

- Compression neuropathy of the ulnar nerve where it passes between the pisiform and hamate.

**Intrinsic Etiology**

- Ganglion Cyst
- Lipoma
- Ulnar Artery Aneurysm or Thrombosis

**Extrinsic Etiology**

- Pisiform, Hamate, Hypothenar Trauma
- Overuse
- Handlebar Palsy

Copyright Jodi Gootkin 2021

51

### Guyon’s Canal Syndrome Presentation

- Presentation may be purely sensory (Zone 3), purely motor (Zone 2), or mixed (Zone 1).

Copyright Jodi Gootkin 2021

52

### Guyon’s Canal Clinical Presentation

- Weakness of pinch and grip
  - Hypothenar muscles, ADDuctor pollicis, all interossei muscles, pinky and ring lumbricals
- Positive findings:
  - Froment’s Sign
  - Wartenberg’s Sign
  - Claw hand

Copyright Jodi Gootkin 2021

53

### Cubital Tunnel Syndrome

- Ulnar nerve is vulnerable to injury from external trauma or compression in the medial epicondyle region.
- Encroachment can also occur from bone fragments, space-occupying lesions, and regional inflammation.
- Motor and special test presentation is the same as Guyon’s Canal Syndrome with the addition of symptoms from more proximal ulnar nerve branches.
  - Elbow flexion exacerbates pain
  - Positive Tinel’s Sign (at Elbow)
- Weakness of wrist flexion (FCU), pinky and ring finger flexion (FDP)

Copyright Jodi Gootkin 2021

54

### Ulnar Nerve Sensory Presentation

Through Wrist Canal  
Guyon's Canal Syndrome

- Distal ulnar border of palm, palmar pinky, and ulnar half ring

Will also demonstrate

Not Through Wrist Canal  
Cubital Tunnel Syndrome

- Proximal ulnar side palm, ulnar dorsum of hand, pinky, and ulnar half ring

Copyright Jodi Gootkin 2021 55

55

### Ulnar Nerve Compression Differential Diagnosis

- Guyon's Canal vs. Cubital Tunnel Syndrome
- Lower Brachial Plexus Injury
- Cervical Radiculopathy C8 T1
- Thoracic Outlet Syndrome (TOS)
- Pancoast Syndrome -non-small cell lung carcinoma (NSCLC) of superior sulcus progresses to thoracic inlet, brachial plexus, and cervical sympathetic nerve lesions.
  - Radiating pain – axilla, scapula, and ulnar nerve distribution.
  - Upper extremity and ulnar nerve atrophy
  - Horner Syndrome
    - Ptosis, miosis, hemianhidrosis, enophthalmos

Copyright Jodi Gootkin 2021 56

56

### Compressive Neuropathy Management

- Nocturnal and daytime splinting as needed
- Patient education on activity modification
- Ergonomic and workplace assessment
- Therapy interventions are directed at alleviating compression and restoring muscle strength, sensation and coordination for functional motor control.
- Corticosteroid Injection
- Decompression Surgery

Copyright Jodi Gootkin 2021 57

57

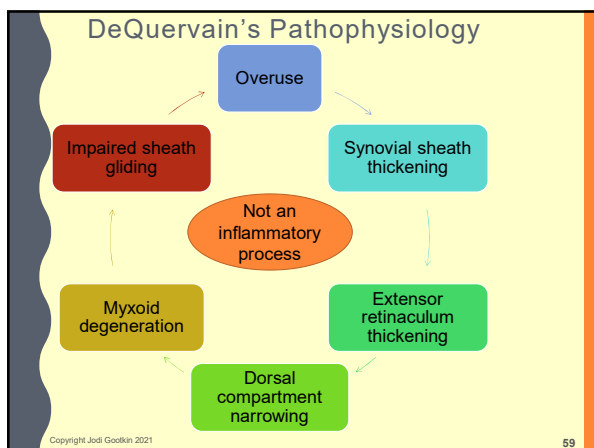
### DeQuervain's Tenosynovitis

- Stenosing tenosynovitis of the wrist first dorsal compartment containing the abductor pollicis longus (APL) and extensor pollicis brevis (EPB).
- Associated with repetitive thumb motions or grasping with ulnar deviation.
- Increased incidence in females postpartum.

Consider This

Copyright Jodi Gootkin 2021 58

58



59

### DeQuervain's Clinical Presentation

- Tenderness along dorsolateral border of distal radius.
- Severe pain with resisted thumb extension.
- Positive Finkelstein's Test
- Treatment with corticosteroid injection, activity modification, thumb spica splint, kinesiotaping, and phonophoresis.

Rowland, P., Phelan, N., Gardiner, S., Linton, K. N., & Galvin, R. (2015). The Effectiveness of Corticosteroid Injection for De Quervain's Stenosing Tenosynovitis (DOST): A Systematic Review and Meta-Analysis. *The open orthopaedics journal*, 9, 437-444.  
 D'Angelo, K., Sutton, D., Côté, P., Dion, S., Wong, J. J., Yu, H., ... & Brown, C. (2015). The effectiveness of passive physical modalities for the management of soft tissue injuries and neuropathies of the wrist and hand: a systematic review by the Ontario Protocol for Traffic Injury Management (OPTIMA) collaboration. *Journal of manipulative and physiological therapeutics*, 38(7), 493-506.

Copyright Jodi Gootkin 2021 60

60

### Trigger Finger and Trigger Thumb

- Primarily idiopathic stenosing tenosynovitis of the flexor tendon most commonly in the ring finger, thumb, and middle finger.
- In adults, associated with comorbidities diabetes, rheumatoid arthritis, and carpal tunnel syndrome.
- Pediatric etiology appears to be developmental.
- No agreement on overuse or trauma etiology.

Copyright Jodi Gootkin 2021 61

61

### Flexor Pulley System

- Stabilization of the tendons in each finger within fibroosseous sheaths prevents bowstringing and maintains mechanical advantage for functional hand use.
- Annular Pulleys (A1 to A5) at MCP, PIP, DIP joints and proximal and middle phalanges
- Cruciate Pulleys (C1 to C3) on phalanges between annular pulleys

Copyright Jodi Gootkin 2021 62

62

### Trigger Finger and Trigger Thumb Clinical Presentation

- With finger flexion
- With finger extension
- With forceful finger extension

Copyright Jodi Gootkin 2021 63

63

### Trigger Finger and Trigger Thumb Clinical Presentation

- Palpable tender nodule on palmar aspect of MCP joint that moves with finger flexion.
- Open Close Hand 10 Times Test
- Conservative management with steroid injection, splinting, soft tissue mobilization, stretching and surgery if not responsive.

Amefeyz, R., McNinch, R., Watts, A., Rodrigues, J., Datta, T. R. C., Glassey, N., & Bullock, J. (2017). Evidence-based management of adult trigger digits. *Journal of Hand Surgery (European Volume)*, 42(5), 473-480.

**Consider This**

Copyright Jodi Gootkin 2021 64

64

### Dupuytren's Disease

- Progressive fibrotic thickening of the midpalmar aponeurosis.

Ball, C., Izadi, D., Verjee, L. S., Chan, J., & Nanchahal, J. (2016). Systematic review of non-surgical treatments for early dupuytren's disease. *BMC musculoskeletal disorders*, 17(1), 345. doi:10.1186/s12891-016-1200-y

Copyright Jodi Gootkin 2021 65

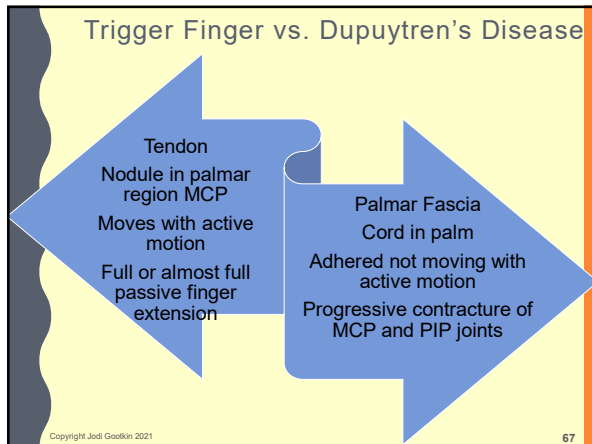
65

### Dupuytren's Disease Clinical Presentation

- Dupuytren's Contracture - MCP flexion of the ring and pinky fingers.
- Visible palpable cords in palm without tenderness.
- Typically, conservative treatment with corticosteroid or collagenase injections and surgery indicated when hand function significantly impaired.

Copyright Jodi Gootkin 2021 66

66



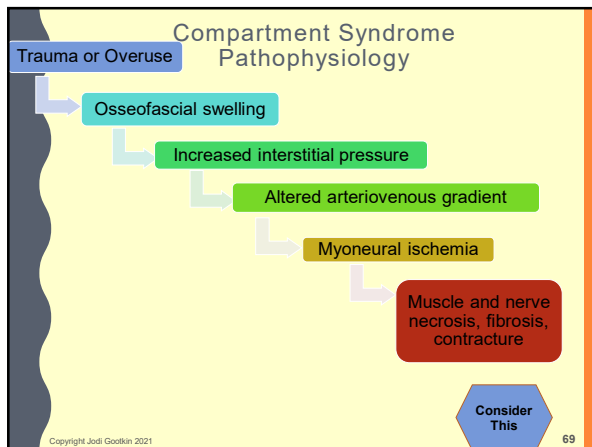
67

### Compartment Syndrome

- Increased size of anatomical structures or volume within the fascial compartments of the forearm or hand can result in severe tissue damage.
- Acute – trauma, humerus supracondylar or forearm fracture, IV infiltration, burns, prolonged limb compression, animal envenomations and bites
- Chronic – overuse, Rower's Forearm

Copyright Jodi Gootkin 2021

68



69

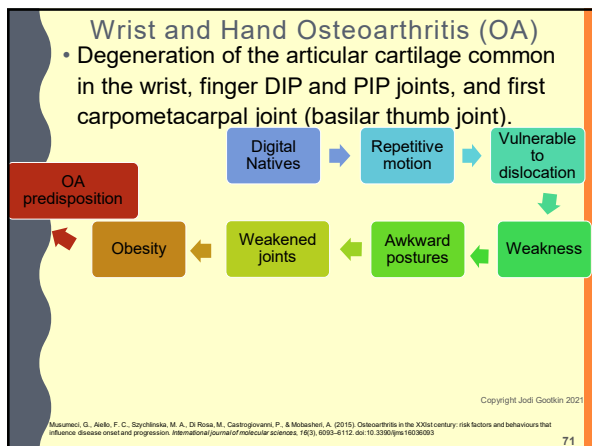
### Compartment Syndrome Clinical Presentation

- Patients presenting with the "6P" findings require physician referral for rapid surgical intervention to avoid severe complications.
  - Pain disproportionate to injury
  - Paresthesia
  - Pallor
  - Paralysis
  - Poikilothermia
  - Pulselessness
- Palpable fullness of region
- Volkmann's Contracture

Kalyani, B. S., Fisher, B. E., Roberts, C. S., & Giannoudis, P. V. (2011). Compartment syndrome of the forearm: a systematic review. The Journal of hand surgery, 36(3), 535-543.

Copyright Jodi Gootkin 2021

70



71

### OA Clinical Presentation

- Hand pain, finger stiffness, reduced ROM, grip and pinch strength
- Swollen joints and deformity
  - Heberden's nodes DIP
  - Bouchard nodes PIP
  - Digital mucous cysts
  - Distal phalange and nail bed
- Positive CMC Grind Test

Copyright Jodi Gootkin 2021

72

### OA Management

- Conservative pharmacological treatment and corticosteroid injection.
- Research varies on benefits of patient education, exercise, splinting, activity modification, ergonomic assessment.
- Surgery indicated for advanced OA of the wrist and basilar thumb joint.

Valdes K, Marik T. A systematic review of conservative interventions for osteoarthritis of the hand. *Journal of Hand Therapy*. 2010; 23: 334-351.  
 Osterås N, Kjekshus I, Smedslund G, Moe RH, Slatkowsky-Christensen B, Uhlig T, Hagen KB. (2017). Exercise for hand osteoarthritis. *Cochrane Database of Systematic Reviews* 2017, Issue 1. Art. No.: CD010388. Klöppenburg, M., Kroon, F. P., Blanco, F. J., Doherty, M., Dziedzic, K. S., Greibrokk, E., ... & Maheu, E. (2019). 2018 update of the EULAR recommendations for the management of hand osteoarthritis. *Annals of the rheumatic diseases*, 78(1), 16-24.  
<https://www.rheumatology.org/Practice-Quality/Clinical-Support/Clinical-Practice-Guidelines/Osteoarthritis>

Copyright Jodi Gootkin 2021 73

73

### Wrist and Hand Rheumatoid Arthritis (RA)

- Systemic autoimmune disease characterized by polyarticular pain, morning stiffness, fatigue, restricted range of motion, joint deformity, joint inflammation, and multiple body system compromise.
  - Bilaterally primarily small joints affected
  - Exacerbations and remissions
    - Disease Activity Score (DAS28)

Copyright Jodi Gootkin 2021 74

74

### RA Clinical Presentation

- With chronic RA, patients experience systemic extra-articular complications.
  - Low Vision
  - Peripheral Neuropathy
  - Anemia
  - Lung Fibrosis
  - Renal Amyloidosis
  - Rheumatoid nodules in skin
  - Atherosclerosis
  - Osteoporosis

Copyright Jodi Gootkin 2021 75

75

Copyright Jodi Gootkin 2021 76

76

### RA Management

- Disease modifying antirheumatic drugs (DMARD) and biologics
- Patient education on joint protection, energy conservation, adaptive equipment beneficial in managing pain.
- Therapeutic exercise may be beneficial to improve function.

<https://www.rheumatology.org/Practice-Quality/Clinical-Support/Clinical-Practice-Guidelines/Rheumatoid-Arthritis>  
 Hammond, A., Jones, V., & Prior, Y. (2016). The effects of compression gloves on hand symptoms and hand function in rheumatoid arthritis and hand osteoarthritis: a systematic review. *Clinical rehabilitation*, 30(3), 213-224.  
 Park, Y., & Chang, M. (2016). Effects of rehabilitation for pain relief in patients with rheumatoid arthritis: a systematic review. *Journal of physical therapy science*, 28(1), 304-308.  
 Williams MA, Srikesavan C, Heine PJ, Bruce J, Broesevan L, Hovey-Thomas N, Lamb SE. (2018). Exercise for rheumatoid arthritis of the hand. *Cochrane Database of Systematic Reviews* 2018, Issue 7. Art. No.: CD003832

Copyright Jodi Gootkin 2021 77

77

### Arthritis Joint Protection

**Avoid**

- Tight and prolonged grasp
- Pressure on back of knuckles and tip or pad of thumb
- Repetitive activities
- Pressure on thumb side of each finger
- Prolonged periods of holding same position

**Use**

- Respect the pain
- Both hands when possible
- Bigger joints to complete tasks
- Pre-planning
- Splints
- Adapted equipment for looser gripping and squeezing
- Follow home exercise program
- Joins in stable position
- Slide or push objects when possible or use a cart

Bobos, P., Nazari, G., Lalone, E. A., Ferreira, L., Grewal, R., & MacDermid, J. C. (2018). A Scoping Review of Joint Protection Programs for People with Hand Arthritis. *The Open Orthopaedics Journal*, 12(1).  
 Carandang, K., Pyatak, E. A., & Vigen, C. L. P. (2016). Systematic review of educational interventions for rheumatoid arthritis. *American Journal of Occupational Therapy*, 70, 7006200020.

Copyright Jodi Gootkin 2021 78

78

### Distal Radius Fracture

- Typical mechanism of injury is fall on out stretched hand (FOOSH).

<p><b>Colles'</b> Wrist in extension Dorsal Displacement</p>	<p><b>Smith's</b> Wrist in flexion Palmar Displacement</p>
<p>Fragility Low energy trauma in patient with osteoporosis</p>	<p>Intra/extra-articular Open/closed Displace/non-displaced Simple/complex</p>

Copyright Jodi Gootkin 2021 79

79

### AO/OTA classification

- Fractures are classified based on the location of the fracture and articular involvement.

2R3A	2R3B	2R3C
Radius Distal Extraarticular	Radius Distal Partial Articular	Radius Distal Complete Articular

[https://www2.aofoundation.org/ACF/le-Server/Surgery/MyPortalFiles/FilePath::Surgery/otl\\_docs/AOOTA%20Classification%20Compendium%202018.pdf](https://www2.aofoundation.org/ACF/le-Server/Surgery/MyPortalFiles/FilePath::Surgery/otl_docs/AOOTA%20Classification%20Compendium%202018.pdf)

Copyright Jodi Gootkin 2021 80

80

### Galeazzi vs. Monteggia Fracture

Forearm fractures identified by the bone fractured and joint dislocated. "GRI MUS"

<p><b>Galeazzi</b></p> <ul style="list-style-type: none"> <li>FOOSH with elbow flexed</li> <li>Radius Fx Inferior 1/3</li> <li>Ulnar dislocation at DRUJ</li> <li>Monitor for AIN syndrome, pro/supination ROM, TFCC injury</li> </ul>	<p><b>Monteggia</b></p> <ul style="list-style-type: none"> <li>FOOSH or direct trauma in pronation</li> <li>Ulna Fx Superior 1/3</li> <li>Anterior radial head dislocation</li> <li>Monitor for limited PIN syndrome elbow ROM</li> </ul>
--	---

Consider This

Copyright Jodi Gootkin 2021 81

81

### Pediatric Distal Radius Fractures

Buckle	Greenstick	Metaphyseal	Physeal
<ul style="list-style-type: none"> <li>One side compresses and bends</li> </ul>	<ul style="list-style-type: none"> <li>One side bends and other cracks</li> </ul>	<ul style="list-style-type: none"> <li>Complete across shaft</li> </ul>	<ul style="list-style-type: none"> <li>Across growth plate</li> </ul>

Copyright Jodi Gootkin 2021 82

82

### Salter Harris Classification

- Used to grade physeal fractures according to the involvement of the physis, metaphysis, and epiphysis

Type 1	Type 2	Type 3	Type 4	Type 5
S	A	L	T E	R
Straight through	Above	beLow	Through Everything	cRush

Copyright Jodi Gootkin 2021 83

83

### Fracture Management

- Non-displaced, extra-articular, stable fractures may be reduced and immobilized.
- Complex, displaced, intra-articular fractures require surgical stabilization through open reduction internal fixation (ORIF) or external fixation (OREF).
- During rehab monitor for shoulder pathology.

Handol H, Elbati J, Theodor-Ejorib Z, Hunter J, Karantana A. Interventions for treating wrist fractures in children. Cochrane Database of Systematic Reviews 2018, Issue 12. Art. No. CD012470.

Copyright Jodi Gootkin 2021 84

84

### Fracture Complications

- Malunion or non-union
- Physeal damage in pediatrics
- Osteomyelitis
- Compression Neuropathy
- Compartment Syndrome
- Tendon Injury
- Chronic Regional Pain Syndrome (CRPS)
- Ulnar Impaction Syndrome (UIS)
- Triangular Fibrocartilage Complex Injury (TFCC)

Copyright Jodi Gootkin 2021 85

85

### Ulna Articulation at Wrist

- Although critical for hand function, the ulna is not a true joint articulation of wrist.
- The triangular fibrocartilage is an articular disc attaching on fovea of ulna and sigmoid notch of radius to separate the ulna from the lunate and triquetrum.

Copyright Jodi Gootkin 2021 86

86

### Triangular Fibrocartilage Complex (TFCC)

- TFCC is the grouping of soft tissue structures that link the radius and ulna to the hand.
- ✓ Dorsal & Volar Radioulnar Ligaments
- ✓ Ulnar Collateral Ligament Complex
- ✓ Triangular Fibrocartilage Disc
- ✓ Meniscus Homologue
- ✓ Sheath of ECU
- Its role is to stabilize distal radioulnar joint and ulnar carpals, and distribute load from the carpals to the ulna.

Consider This

Copyright Jodi Gootkin 2021 87

87

### Ulnar Variance

- Measured distance of greater than 1 mm from distal articular surfaces of radius and ulna is considered abnormal.

<h4 style="margin: 0;">Positive Variance</h4> <ul style="list-style-type: none"> <li>• Ulna extends beyond radius</li> <li>• Degenerative changes of ulna, fibrocartilaginous disc, and carpals.</li> </ul>	<h4 style="margin: 0;">Negative Variance</h4> <ul style="list-style-type: none"> <li>• Ulna shorter than radius</li> <li>• Lunate instability and deterioration</li> </ul>
---	--

Copyright Jodi Gootkin 2021 88

88

### Ulnar Impaction Syndrome (UIS)

- Degeneration of the ulnar head occurs from abutment against TFCC and ulnar carpals.
- Etiology is acquired positive ulnar variance from fracture, radius growth plate arrest, repetitive loading of ulnar carpus with activities.

Copyright Jodi Gootkin 2021 89

89

### Ulnar Impaction Syndrome (UIS)

```

    graph TD
      A[Positive ulnar variance] --> B[Ulnar carpal loading]
      B --> C[TFCC overstretching]
      C --> D[TFCC degeneration]
      D --> E[Ulnar/lunate chondromalacia]
  
```

Copyright Jodi Gootkin 2021 90

90

### Ulnar Impaction Syndrome Clinical Presentation

- Ulnar sided wrist pain exacerbated by forceful grip, pronation, ulnar deviation, and axial loading.
- Decreased wrist and forearm ROM
- Tenderness upon palpation of dorsal wrist near ulnar styloid and just distal to ulnar head.
- Positive Nakamura's Ulnar Stress Test
- Conservative management with splinting, activity modification, and corticosteroid injection.
- Surgical technique to alleviate impaction varies based on extent of TFCC damage and osteoarthritic changes.

Copyright Jodi Gootkin 2021 91

91

### Scaphoid Fracture

- The scaphoid proximal and distal poles are joined in the middle at the slightly narrow waist.
- FOOSH injury with impact on wrist in hyperextension and ulnar deviation generates compressive load impacting dorsal surface of scaphoid and dorsal border of distal radius.

Copyright Jodi Gootkin 2021 92

92

### Scaphoid Fracture Clinical Presentation

- Patients with distant history of trauma and current function restrictions may require referral for additional diagnostic testing.
- Tenderness, pain and swelling in the region of anatomical snuff box.
- Increased pain with pinching and grasping
- Positive Watson's Test

Copyright Jodi Gootkin 2021 93

93

### Scaphoid Fracture - Management

- Distal pole fractures can be managed with closed reduction and thumb spica cast.
- ORIF is indicated when fracture occurs at the waist or proximal pole, because the detached proximal bone fragment has a tenuous blood supply.
- Closely monitor symptoms as scaphoid is at risk for delayed, nonunion or avascular necrosis.

Consider This

Copyright Jodi Gootkin 2021 94

94

### Carpal Arc Anatomy

- Lunate articulates with radius for wrist motion and other carpals playing a critical role in stability of carpal arcs.
- No muscles attach to the lunate so it relies on the bony architecture of its articulations with the adjacent carpals and ligamentous support for stability.

Copyright Jodi Gootkin 2021 95

95

### Perilunate Instability

- Severe closed wrist injury resulting in significant wrist instability.

Copyright Jodi Gootkin 2021 96

96



### Perilunate Fracture-Dislocation Clinical Presentation

- Generalized wrist swelling, dorsal pain, and ROM restriction.
- Median nerve compression symptoms.
- Compartment syndrome symptoms.
- Diffuse tenderness with lunate palpation.
- Surgical intervention indicated to stabilize fractures and repair ligaments.

Copyright Jodi Gootkin 2021 97

97

### Kienbock's Disease

- Avascular necrosis of the lunate related to lunate fractures that fail to heal and osteoarthritis.
- Presents as painful stiff wrist with limited ROM, weak grip, and tenderness with lunate palpation.
- Rehabilitation will not alleviate symptoms. Immobilization in early stages may be successful with surgery indicated in advanced stages.

Copyright Jodi Gootkin 2021 98

98

### Triangular Fibrocartilage Complex Tear (TFCC)

- Injury to the complex that plays a critical role in wrist stability with grip, weight bearing, and rotational loading activities.

<b>Type 1 Acute -Trauma</b> Tears and avulsion FOOSH on pronated and extended wrist Power drill injuries	<b>Type 2 Chronic -Degeneration</b> Thinning, perforation, chondromalacia Repetitive high wrist forces in extension and/or ulnar deviation Age related changes Radius fracture, UIS
---	---

Copyright Jodi Gootkin 2021 99

99

### TFCC Tear Clinical Presentation

- Ulnar sided wrist pain.
- Tenderness to palpation and swelling between pisiform and ulnar styloid process.
- Clicking with wrist ROM.
- Pain with wrist motions
  - weight bearing on extended wrist
  - resisted ulnar deviation and extension

Copyright Jodi Gootkin 2021 100

100

### TFCC Assessment

- Arthroscopy better than imaging studies to identify tear.
- Positive provocative tests noted.
  - Press Test
  - Fovea sign
  - Piano Key Sign

Lester B, Halbrecht J, Levy IM, Gaudinez R. "Press test" for office diagnosis of triangular fibrocartilage complex tears of the wrist. *Ann Plast Surg* 1995; 33:411-5.  
 Andersson, J. K., Andermord, D., Karlsson, J., & Fridén, J. (2015). Efficacy of magnetic resonance imaging and clinical tests in diagnostics of wrist ligament injuries: a systematic review. *Arthroscopy: The Journal of Arthroscopic & Related Surgery*, 31(10), 2014-2020.

**Consider This**

Copyright Jodi Gootkin 2021 101

101

### TFCC Tear Management

- Conservative management with splinting, corticosteroid injections and activity modification.
  - Caution when progressing pronation/supination and radial/ulnar deviation exercises.
- Surgery indicated for unresponsive or more severe tears.

Copyright Jodi Gootkin 2021 102

102

### Gamekeeper's Thumb

- Loading of the ulnar collateral ligament at the thumb MCP results injury to the ligament.
- Sustained during FOOSH when a valgus force is applied to the ABDucted thumb or chronic stress.
- May have associated conditions
  - avulsion fracture at phalanx
  - Stener lesion

Copyright Jodi Gootkin 2021 103

103

### Gamekeeper's Thumb Clinical Presentation

- Valgus laxity of thumb MCP joint noted in extension and flexion.
- Lateral prehension painful and weak.
- Palpable swelling and tenderness along ulnar aspect thumb MCP joint.

Copyright Jodi Gootkin 2021 104

104

### Patient Reported Outcome Measures

- Used to inform treatment by screening for functional deficits and monitoring impact of therapy to personalize care for each patient.

FOTO	Focus on Therapeutic Outcomes Elbow, Wrist, and Hand
MHQ	Michigan Hand Outcomes Questionnaire
PRWE	Patient-Rated Wrist Evaluation
BCTQ	Boston Carpal Tunnel Questionnaire

Dacomb, P. J., Amirfeiz, R., & Davis, T. (2016). Patient-reported outcome measures for hand and wrist trauma: is there sufficient evidence of reliability, validity, and responsiveness?. *Hand*, 11(1), 11-21.

Copyright Jodi Gootkin 2021 105

105

### Focus on Therapeutic Outcomes Elbow, Wrist, and Hand (FOTO)

- Used by Medicare to determine functional status change.
- Each item scored with sum between 10-50 that converts to functional status score of 0-100
- Are you having any difficulty carrying a shopping bag or briefcase?
- Are you having any difficulty opening a tight or new jar?

[https://cdm2.hubspot.net/hub/614420/11/NOF/2018%20Update/Short%20Forms/Elbow%20Wrist%20Hand%20Functional%20Status\\_QP%23222\\_NOF%230427\\_2018.pdf](https://cdm2.hubspot.net/hub/614420/11/NOF/2018%20Update/Short%20Forms/Elbow%20Wrist%20Hand%20Functional%20Status_QP%23222_NOF%230427_2018.pdf)

Copyright Jodi Gootkin 2021 106

106

### Michigan Hand Outcomes Questionnaire(MHQ)

- 37 core questions measure hand-specific outcomes in 6 domains.

Shauer, M. J., & Chung, K. C. (2013). The Michigan Hand Outcomes Questionnaire after 15 years of field trial. *Plastic and reconstructive surgery*, 131(5), 770e-71e. doi:10.1097/PRS.0b013e3182865d83  
Chung KC, Pillsbury MS, Walters MR, Hayward RA. (1998). Reliability and validity testing of the Michigan Hand Outcomes Questionnaire. *Journal of Hand Surgery - American Volume*, 23(4):575-87.

Copyright Jodi Gootkin 2021 107

107

### Patient Rated Wrist Evaluation (PRWE)

- Questions are intended to quantify perception of pain and disability from wrist and hand conditions.
  - Pain at rest, its worst, frequency
  - Cutting meat, carrying ten pounds

Melita, S. P., MacDermid, J. C., Richardson, J., MacIntyre, N. J., & Grewal, R. (2015). Reliability and validity of selected measures associated with increased fall risk in females over the age of 45 years with distal radius fracture—A pilot study. *Journal of Hand Therapy*, 28(1), 2-10.  
Muller, M. A., Knapik, S. C., Ongerons, S. A., Eerten, P. V., Schepers, T., Goslings, J. C., & Schep, N. W. (2018). Normative data for the Patient-Rated Wrist Evaluation questionnaire. *Journal of hand therapy: official journal of the American Society of Hand Therapists*, 31 3, 267-294.

Copyright Jodi Gootkin 2021 108

108

### Boston Carpal Tunnel Questionnaire (BCTQ)

- Specifically developed to be sensitive to changes in symptom severity and basic ADLs.

<b>Symptoms</b>	1 Normal 5 Very serious	<b>Function</b>	1 No difficulty 5 Can't perform
	Pain, weakness, sensation		Holding book while reading, gripping phone handle

Copyright Jodi Gootkin 2021 <https://www.jospt.org/doi/full/10.2519/jospt.2019.0301> 109

109

### Conclusion

- Understanding the pathophysiology and mechanism of injury for wrist and hand disorders allows the clinician to appropriately interpret symptoms.
- This will strengthen decision making that directs care and prompts communication with physicians to address potential complications.

Copyright Jodi Gootkin 2021 110

110

1. Which low cost, high resolution diagnostic tool allows dynamic visualization of nerve entrapment with patient feedback?

- MRI
- SPECT/CT
- Ultrasonography
- Nerve Conduction Study

Copyright Jodi Gootkin 2021 111

111

2. What condition presents with similar sensory impairments as Carpal Tunnel Syndrome?

- C6-7 Radiculopathy
- Thoracic Stenosis
- Cubital Tunnel Syndrome
- Trigger Finger

Copyright Jodi Gootkin 2021 112

112

3. The first extensor compartment of the wrist (involved in DeQuervain's Tenosynovitis) contains a septum that separates which two tendons?

- Extensor Digitorum and Abductor Pollicis Longus
- Extensor and Flexor Carpi Ulnaris
- Flexor Digitorum Superficialis and Profundus
- Extensor Pollicis Brevis and Abductor Pollicis Longus

Copyright Jodi Gootkin 2021 113

113

4. Which condition is suspected when the clinician palpates a firm nodule in the palm of the hand that moves with active finger flexion?

- Trigger Finger
- Dupuytren's Disease
- Gamekeepers Thumb
- Lunate Dislocation

Copyright Jodi Gootkin 2021 114

114

5. Osseofascial swelling following trauma leading to increased interstitial pressure and myoneural ischemia describes what condition?

- A. Carpal Tunnel Syndrome
- B. Muscular Angina
- C. Compartment Syndrome
- D. Guyon's Compression

Copyright Jodi Gootkin  
2021

115

115

6. A FOOSH injury resulting in fracture of the superior/proximal shaft of the ulna with dislocation of the radial head is termed \_\_\_\_\_.

- A. Galeazzi
- B. Colles'
- C. Smith's
- D. Monteggia

Copyright Jodi Gootkin  
2021

116

116

7. What is the primary ligamentous stabilizer of the distal radioulnar joint and ulnar carpals?

- A. Flexor Retinaculum
- B. Triangular Fibrocartilage Complex
- C. Flexor Pulley System
- D. Palmar Extrinsic Ligaments

Copyright Jodi Gootkin  
2021

117

117

8. During rehabilitation from a scaphoid fracture, patients should be closely monitored for what complication?

- A. Avascular Necrosis
- B. Ulnar Impaction
- C. Nerve Entrapment
- D. Tenosynovitis

Copyright Jodi Gootkin  
2021

118

118

9. Which provocative test is utilized to assess for the integrity of the triangular fibrocartilage complex?

- A. Finklestein's
- B. Phalen's
- C. Press
- D. Valgus Laxity

Copyright Jodi Gootkin  
2021

119

119

10. Which of the following is NOT a patient reported outcome measure that assesses the impact of wrist and hand disorders on function?

- A. FOTO
- B. VAS
- C. MHQ
- D. PRWE

Copyright Jodi Gootkin  
2021

120

120

## References

Ahmed, A., Javed, M. I., Akhtar, M. S., Mangi, M. I., & Jalli, S. A. (2019). Anatomic variation of the first dorsal compartment in surgical treatment of DeQuervain's disease. *Phil J Surg*, 35(1), 55-58.

Aleksenko D, Varacallo M. Guyon Canal Syndrome. [Updated 2019 May 5]. In: StatPearls [Internet]. Treasure Island (FL): StatPearls Publishing; 2019 Jan-. Available from: <https://www.ncbi.nlm.nih.gov/books/NBK431063/>

Alsnack, S., Gliner, S., & Zigm, S. (2015). Efficacy of splinting variations in different treatment protocols in trigger thumb. *JPO: Journal of Prosthetics and Orthotics*, 27(1), 17-22.

Amari, G.A., Abreu, M.A., Veronesi, B.A., & Rezzano, R.M. (2018). Arthroscopic Assessment of the Wrist with Kienbock's Disease. Acta orthopaedica brasiliens.

American Academy of Orthopaedic Surgeons. (2013). *Appropriate Use Criteria for Treatment of Distal Radial Fractures*. Rosemont, IL: American Academy of Orthopaedic Surgeons, 27-41.

American Academy of Orthopaedic Surgeons. (2016). *Management of carpal tunnel syndrome: evidence-based clinical practice guidelines*. 2016.

Amirifeyz, R., McNinch, R., Watts, A., Rodrigues, J., Davis, T. R. C., Glasser, N., & Bullock, J. (2017). Evidence-based management of adult trigger digits. *Journal of Hand Surgery (European Volume)*, 42(5), 473-480.

Anderson, J. K. (2017). Treatment of scapholunate ligament injury: current concepts. *EFORT open reviews*, 2(9), 382-393.

Anderson, J. K., Anderson, D., Karlsson, J., & Fridén, J. (2015). Efficacy of magnetic resonance imaging and clinical tests in diagnosis of wrist ligament injuries: a systematic review. *Arthroscopy: The Journal of Arthroscopic & Related Surgery*, 31(10), 2014-2020.

Auld, T., & Wenzel, J. P. (2017). Dupuytren's disease: How to recognize its early signs. *The Journal of Family Practice*, 66(3), E5.

Babazadeh, S., Ling, F., & Page, R. Effects of Wrist Kinematic Coupling Motion during Dart-Thrower's Motion in Real-Time Measurement. *Barlow SJ. A non-surgical intervention for triangular fibrocartilage complex tears. Physiother Res Int*. 21:271-276.

Basaglia, L. T., Bennett, D. L., Silberg, R. M., & Schmidt, A. B. (2017). Negative Neurodynamic Tests Do Not Exclude Neural Dysfunction in Patients With Entrapment Neuropathies. *Archives Of Physical Medicine And Rehabilitation*, 98(3), 480-486. doi:10.1016/j.apmr.2016.06.019

Basha, M. A. A., Ismail, A. A., & Imam, A. H. F. (2018). Does radiography still have a significant diagnostic role in evaluation of acute traumatic wrist injuries? A prospective comparative study. *Emergency radiology*, 25(2), 129-138.

Beleckas, C., & Caffee, R. (J). Distal radius fractures in the athlete. *Current Reviews In Musculoskeletal Medicine*, 10(1), 62-71. doi:10.1007/s12178-017-9385-8

Bhuanranonh, P., Sranauer, I. M., & Makhora, K. (2018). Determining Sources of Effort Based on Grip Strength Test in Three Wrist Positions. *Safety and Health at work*.

Biehl, C., Braut, T., Thomann, U., Osta, A., Szalay, G., & Rehar, S. (2018). Radiocarpal fusion and midcarpal resection interposition arthroplasty: long-term results in patients with BMC musculoskeletal disorders. 19(1), 286.

Birklein, F., O'Neill, D., & Schreiner, T. (2015). Complex regional pain syndrome: An optimistic perspective. *Neurology*, 84(1), 89-96.

Birawa, S. (2015). *Ulnarocarpal Impaction*. Eplasty, 15.

Bonfi, H. M., Jager, L., Galan, S., Soliman, A. T., Frey, A., & Dirlik, H. P. (2005). Optimization of MDCT of the wrist to achieve diagnostic image quality with minimum radiation exposure. *American Journal of Roentgenology*, 185(3), 647-654.

Boutin RD, Buonocore MH, Immerman I, Ashwell T, Sonico GJ, Szabo RM, et al. (2013) Real-Time Magnetic Resonance Imaging (MRI) during Active Wrist Motion: Observations. *PLoS ONE* 8(12): e84004. Copyright Jodi Gootkin 2021

121

122

Dacombe, P.-J., Amirifeyz, R., & Davis, T. (2016). Patient-reported outcome measures for hand and wrist trauma: is there sufficient evidence of reliability, validity, and responsiveness? *Hand*, 11(1), 11-21.

Dale, A. M., Harris-Adams, C., Rempel, D., Gerr, F., Hegmann, K., Silvestri, B., ... & Thiese, M. S. (2013). Prevalence and incidence of carpal tunnel syndrome in US working populations: pooled analysis of six prospective studies. *Scandinavian journal of work, environment & health*, 39(5), 426-435.

Daniels, E. W., Cook, D. J., Jacobs, B. C., & Phillips, S. P. (2018). Existing Evidence on Ultrasound-Guided Injections in Sports Medicine. *Orthopaedic journal of sports medicine*, 6(2), 232586718756576.

De Santis, V., Di Majo, S., Soliman, A. T., Rasola, G., Ebelly, R., & Millimaggi, G. (2014). Hand X-ray in pediatric endocrine: Skeletal age assessment and beyond. *Journal of endocrinology and metabolism*, 78(Suppl 1), S63-S71. doi:10.4103/2220-8210.145076

Deng, X., Chao, L. P., Chu, S., Leung, K. F., Li, S., & Ip, W. (2018). Exploratory use of ultrasound to determine whether demyelination following carpal tunnel syndrome is associated with axonal degeneration. *Neural regeneration research*, 13(2), 317.

Ettema, S., MacDermid, J. C., Vincent, J. J., Packerham, T. L., Walton, D. M., & Grewal, R. R. (2018). Rasch analysis of the patient-rated wrist evaluation questionnaire. *Archives of physiotherapy*, 8(1), 5.

Ettema, A. (2005). Carpal tunnel syndrome: The role of the subcutaneous connective tissue. *Gildeprint Drukkerijen BV, Enschede, The Netherlands*. [https://repub.eur.nl/pub/85470/0207\\_Ettema\\_%20Arke%20Maria.pdf](https://repub.eur.nl/pub/85470/0207_Ettema_%20Arke%20Maria.pdf)

Forman, T. A., Forman, S. K., & Rose, N. E. (2005). A clinical approach to diagnosing wrist pain. *Am Fam Physician*, 72(9), 1753-1758.

Furuta, G., & Singh, N. (2016). Assessment of Ligaments and Fibrocartilage Complex of Wrist Joint in Trauma - MRI vs MR Arthrography.

Gannon, B. M. (2016). Biomechanics of the Distal Radioulnar Joint in the Normal Wrist and Following Distal Radius Malunion. *Gaillard, A. K., Shah, D. S., & Kozlowski, A. E. (2013). Wrist tendon moment arms: Quantification by imaging and experimental techniques. Journal of biomechanics*, 68, 135-140.

Gilto, B., Draghi, A. G., & Draghi, F. (2018). Sonography of Non-specific Disorders of the Hand and Wrist Tendons. *Journal of ultrasound in medicine: official journal of the American Institute of Ultrasound in Medicine*, 37, 1, 51-68.

Gonzalez, B., Ahmadi Bari, M., Arzougar, M., Bahramzadeh, M., Curran, S., Madani, S. P., & Hutchins, S. W. (2016). Comparison of the efficacy of a neutral wrist splint and a wrist splint incorporating a lumbrical unit for the treatment of patients with carpal tunnel syndrome. *Prosthetics and orthotics international*, 40(6), 517-523.

Gonzalez-Suarez, C. B., Buenavente, L. D., Cua, R. C., Fidal, M. B., Cabrera, J. C., & Regala, G. J. (2018). Inter-Rater and Intra-Rater Reliability of Sonographic Median Nerve and Wrist Measurements. *Journal of medical ultrasound*, 26(1), 14.

Hamamoto Y, Ito H, Fujikawa M, et al. (2015) Serological and Progression Differences of Joint Destruction in the Hand and Feet in Rheumatoid Arthritis - a Cross-Sectional Cohort Study. *PLoS ONE* 10(8): e0136611.

Hammond, A., Jones, V., & Prior, Y. (2016). The effects of compression forces on hand symptoms and hand function in rheumatoid arthritis and hand osteoarthritis: a systematic review. *Clinical rehabilitation*, 30(3), 213-224.

Hansson, H. G., Eliott, J., Ijzerman, E. J., Hunter, J., Kaseniana, A. Interventions for treating wrist fractures in children. *Cochrane Database of Systematic Reviews* 2018, Issue 12. Art. No.: CD012470.

Hasan, T., & Fazzi, M. (2015). De Quervain's Syndrome: Etiopathogenesis and Pathogenesis: A Randomised Controlled Trial in Pregnant Females: De Quervain. *Journal of Orthopaedics, Trauma and Rehabilitation*, 19(1), 2-6.

Herzberg, G., Burnier, M., & Nakamura, T. (2018). A New Wrist Clinical Evaluation Score. *Journal of wrist surgery*, 7, 2, 109-114. Copyright Jodi Gootkin 2021

123

Hochberg, M. C., Altman, R. D., April, K. T., Benkhalti, M., Guyatt, G., McGowan, J., ... & Tugwell, P. (2012). American College of Rheumatology 2012 recommendations for the use of nonpharmacologic and pharmacologic therapies in osteoarthritis of the hand, hip, and knee. *Arthritis care & research*, 64(4), 465-474.

Hou, W. H. Chi, C. C., Lu, H., Chou, Y. Y., Kuo, K. N., Chung, H. Y. (2017) Vocational rehabilitation for enhancing return-to-work in workers with traumatic upper limb injuries. *Cochrane Database of Systematic Reviews*, 2017, Issue 12. Art. No.: CD010020.

Choi, G., Yang, W., Chen, X., Qi, W., Li, X., Du, Y., & Xie, P. (2018). Estimation of Time-Varying Coherence Amongst Synergic Muscles During Wrist Movements. *Front. Neurosci*, 12.

Hueller MW, Birkert A, Strobel K, Pérez Lago MDS, Werner L, Hug U, et al. (2013) Imaging Non-Specific Wrist Pain: Interobserver Agreement and Diagnostic Accuracy of SPECT/CT, MRI, CT, Bone Scan and Plain Radiographs. *PLoS ONE* 8(12): e83539.

Huisaeta, B. M., Fridén, J., Goert, J. H., Hooglyder, P., & European HANDGUIDE Group. (2014). Carpal tunnel syndrome: hand surgeons, hand therapists, and physical medicine and rehabilitation physicians agree on a multidisciplinary treatment guideline—results from the European HANDGUIDE Study. *Archives of physical medicine and rehabilitation*, 95(12), 2253-2263.

Huisaeta, B., & Bozartar, A. P. (2010). Ultrasound: Basic understanding and learning the language. *International Journal Of Shoulder Surgery*, 4(3), 55-62. doi:10.4103/0973-6042.76960

Ijpeze, T. C., Smith, H. C., Lee, D. J., & Elfar, J. C. (2016). Distal Radial Fracture Outcomes and Rehabilitation. *Geriatric Orthopaedic Surgery & Rehabilitation*, 7(3), 202-205. doi:10.1177/1545855616669202

Israel, D., Delclaux, S., André, A., Aprédois, C., Ronglémas, P., & Mansat, P. (2016). Peri-lunate dislocation and fracture-dislocation of the wrist: Retrospective evaluation of 65 cases. *Orthopaedics & Traumatology: Surgery & Research*, 102(3), 351-355.

Jacobson, J. A., Wilson, T. J., & Yang, L. J. S. (2016). Sonography of common peripheral nerve disorders with clinical correlation. *Journal of Ultrasound in Medicine*, 35(4), 683-693.

Jafari, D., Mazar, F. N., Shariatzadeh, H., Shahverdi, S., Moghimi Z, et al. Inflammation and Fibrosis of Transverse Carpal Ligament and Flexor Tendonopathy in Severe Idiopathic Carpal Tunnel Syndrome. *Shahs Ortho J* 2014; 1(3):627.

Kalyani, B. S., Fisher, B. E., Roberts, C. S., & Gianopoulos, P. V. (2011). Compartment syndrome of the forearm: a systematic review. *The Journal of hand surgery*, 36(3), 535-543.

Kiani, P. M., Voplat, G. S., Mansour, M. K., Gaspar, M. P., Wolfe, S. W., Crisco, J. J., & Got, C. (2019). Relative Contributions of the Midcarpal and Radiocarpal Joints to Dart-Thrower's Motion at the Wrist. *The Journal of hand surgery*, 43(3), 234-240.

Kara, A., Celik, H., Seker, A., Kilinc, E., Camur, S., & Uzun, M. (2015). Surgical treatment of dorsal perilunate fracture-dislocations and prognostic factors. *International Journal of Surgery*, 24, 57-63.

Karakapan, M., et al. (2018). One portal endoscopic release of the first extensor compartment in de Quervain's disease. *Acta Orthop Traumatol Turc*

Kaviri, M., & Liss, F. E. (2016). Identifying and treating traumatic hand and wrist injuries. *Journal of the American Academy of PAs*, 31(7), 15-21.

Kim, K. G., Park, C. S., Jeon, S. H., Jung, E. Y., Ha, J., & Lee, S. (2018). Feasibility of a New Desktop Motion Analysis System with a Video Game Console for Assessing Various Three-Dimensional Wrist Motions. *Clinics in Orthopaedic Surgery*, 10(4), 468-478.

Koenigshofer, V. V., Krüger, B., Staud, M., Goehring, J. C., Probst, R. W., & Scholtes, V. A. (2016). Are the patient-rated wrist evaluation (PRWE) and the disabilities of the arm, shoulder and hand (DASH) questionnaire used in distal radial fractures truly valid and reliable? *Bone & joint research*, 7(1), 36-45. Copyright Jodi Gootkin 2021

124

123

124

Kloppenborg, M., Kroon, F. P., Blanco, F. J., Doherty, M., Dzielicki, K. S., Grotzke, E., ... & Mahieu, E. (2019). 2018 update of the EULAR recommendations for the management of hand osteoarthritis. *Annals of the rheumatic diseases*, 78(1), 16-24.

Kochera, A., & Agrawal, Y. (2018). Landmark Technique for a Wrist Block: JBJS essential surgical techniques, 8, 1, e7.

Kolmer, J., Baumert, P., Milford, D., Dombert, T., Staub, F., Benzhusen, M., et al. (2012). 12-Signal Ultrasound Nerve Branches at the Wrist in Guyon's Canal Syndrome. *PLoS ONE* 7(10): e47285.

Korb, M. A., Bedew, M. A., Adossary, N. M., Mahmoud, G., & Naggui, M. F. (2018). Sonographic assessment of carpal tunnel syndrome in diabetic patients with and without polyneuropathy. *Medicine*, 97(24), e1104.

Kuo, L. S., Kujler, P. P. F., Oppeman, J., Kerkhof, G. M., Maas, M., & Frings-Dresen, M. H. (2018). Overuse wrist injuries in young athletes: What do sports physicians consider important signals and functional limitations? *Journal of sports sciences*, 36(1), 86-96.

Krüti, M., van der Woude, J. C., van Suijskom-Smit, L. W., & Koes, B. W. (2012). Manipulative interventions for reducing pincer elbow in young children. *Cochrane Database of Systematic Reviews*, (1).

Kuo, T. T., Lee, M. R., Liao, Y. Y., Chen, J. P., Hsu, Y. W., & Ch'K (2016) Assessment of Median Nerve Mobility by Ultrasound Dynamic Imaging for Diagnosing Carpal Tunnel Syndrome. *PLoS ONE* 11(11): e0147051.

Kuo, Y. L., Hsu, C. C., Kuo, L. C., Wu, P. T., Shao, C. J., Wu, K. C., ... & Jou, L. M. (2015). Inflammation is present in de Quervain disease—correlation study between biochemical and histopathological evaluation. *Annals of plastic surgery*, 74, 1146-1151.

Kunip, N. B. R., Puchner, M., Kock, T., & Gohseier, M. (2018). Wrist Kinematics and Kinetics during Wheelchair Propulsion with a Novel Handle-based Propulsion Mechanism. In 2018 40th Annual International Conference of the IEEE Engineering in Medicine and Biology Society (EMBC) (pp. 2146-2149). IEEE.

Lameijer, C. M., Nizien, C. K., El Mourini, M., & van der Sijde, C. C. (2018). Pain, impaired functioning, poor satisfaction and diminished health status eight years following perilunate (fracture) dislocations. *Disability and Rehabilitation*, 1-8.

Lans, J., Lasa, A., Chen, N. C., & Jupiter, J. B. (2018). Incidence and Functional Outcomes of Scapholunate Disassociations Associated Distal Radius Fractures: A 2-year Follow-up Scapholunate Dislocation. *The open orthopaedics journal*, 12, 33.

Lee, J., Kim, T., & Lim, K. (2018). Effects of eccentric control exercise for wrist extensor and shoulder stabilization exercise on the pain and functions of tennis elbow. *Journal of physical therapy science*, 30(4), 590-594.

Lee, Y. K., Park, S., & Lee, M. (2015). Flexor Tendon Entrapment at the Malunited Base Fracture of the Proximal Phalanx of the Finger in Child: A Case Report. *Medicine*, 94(5), e1408.

Lettenko D, Varacallo M. (2018). Guyon Canal Syndrome. In: StatPearls [Internet]. Treasure Island (FL): StatPearls Publishing; 2018 Jan-. Available from: <https://www.ncbi.nlm.nih.gov/books/NBK431063/>

Levine RH, Forts LA, Wissman M. Satter Hand Fractures. [Updated 2019 Jun 4]. In: StatPearls [Internet]. Treasure Island (FL): StatPearls Publishing; 2019 Jan-. Available from: <https://www.ncbi.nlm.nih.gov/books/NBK430688/>

Liao, J. C. Y., Chong, K. A., & Tan, D. M. (2013). Causes and assessment of subacute and chronic wrist pain. *Singapore Med J*, 54(10), 592-598.

Linton, L. B. (2005). Wrist range of motion during a gardening occupation using an ergonomically labeled trowel versus a standard-design trowel - an extension and replication.

Mallik, S. K., Jha, D. K., Nagardar, A., & Mahapatra, S. (2018). A comparative study between splinting versus corticosteroid injection in de-quervain's disease. *International Journal of Orthopaedics*, 4(3), 22-26.

Manickang, N., Bisset, L., & Kawajiri, J. (2018). Lateral epicondylitis exhibits adaptive muscle activation strategies based on wrist posture and levels of grip force: a case-control study. *Journal of musculoskeletal & neuronal interaction*, 18(3), 323. Copyright Jodi Gootkin 2021

125

Mansuipur, P. K., Deren, M. E., & Kamal, R. O. B. I. N. (2013). Nerve compression syndromes of the upper extremity: diagnosis, treatment, and rehabilitation. *Rhode Island Medical Journal*, 96(5), 37-39.

Marini, F., Squeri, V., Morasso, P., Konczak, J., & Massa, L. (2016). Robot-aided mapping of wrist proprioceptive accuracy across a 3D workspace. *PLoS one*, 11(8), e0161155.

Mechaco, E. G., Aguilar, J. I., Simó, C., & Ferrero, M. A. M. (2016). Types and Tricks in Perilunate Carpal Fracture-Dislocations. *Mehta, S. P., MacDermid, J. C., Richardson, J., MacIntyre, N. J., & Grewal, R. (2015). Reliability and validity of selected measures associated with increased fall risk in females over the age of 45 years with distal radius fracture—A pilot study. *Journal of Hand Therapy*, 28(1), 2-10.*

Mehanna, M., & Rhenne, S. J. (2013). Rupture of the ulnar collateral ligament of the thumb - a review. *International journal of emergency medicine*, 6(1), 31. doi:10.1186/1865-1380-6-31

Meservey, M., Wakek, K. W., & Vastrateke, K. (2018). Secondary Abduction Syndromes of the Wrist in Trauma: A Pictorial Essay. *Journal of the Belgian Society of Radiology*, 102(1).

Meyer, P., Linington, P. F., Pesquer, L., Poussange, N., Silvestre, A., & Lallaudriere, B. (2018). Imaging of Wrist Injuries: A Standardized US Examination in Daily Practice. *Journal of the Belgian Society of Radiology*, 102(1).

Morrell, J., Frischi, G., & Sant, A. E. (2017). Dupuytren's Disease: Predicting Factors and Associated Conditions. A Single Center Questionnaire-Based Case-Control Study. *The archives of bone and joint surgery*, 5(6), 384-393.

Mortimo, H., Aperia, E. P., Herzberg, G., Werner, F. W., Wolfe, S. W., & Garcia-Elias, M. (2007). 2007 IFSSH committee report of wrist biomechanics/normative biomechanics of the so-called "anti-throwing motion of the wrist". *The Journal of hand surgery*, 32(9), 1447-1453.

Morrell, N. T., Moyer, A., Quintan, N., & Shafritz, A. B. (2017). Scapholunate and perilunate injuries in the athlete. *Current reviews in musculoskeletal medicine*, 10(1), 45-52.

Mulders, M. A., Kleipool, S. C., Dingemans, S. A., Eerten, P. V., Schepers, T., Goings, J., C., & Schep, N. W. (2018). Normative data for the Patient-Rated Wrist Evaluation questionnaire. *Journal of hand therapy: official journal of the American Society of Hand Therapists*, 31, 287-294.

Nance, E. M., Byun, D. J., Endo, Y., Wolfe, S. W., & Lee, S. K. (2017). Dorsal Wrist Pain in the Extended Wrist-Loading Position: An MRI Study. *Journal of wrist surgery*, 6(4), 276-279.

Nee, R. J., Jull, G. A., Viozesano, B., & Coppjeters, M. W. (2012). The validity of upper-limb neurodynamic tests for detecting peripheral neuropathic pain. *Journal of Occupational & Sports Physical Therapy*, 42(5), 413-424.

Neuberger, B., Benndorf, M., Redlbach, C., Krauß, T., Lampert, F., Zajonc, H., et al. (2016). Comparison of Diagnostic Accuracy of Radiation Dose-Equivalent Reduction: Multidetector Computed Tomography and Cone Beam Computed Tomography for Fractures of Adult Cadaveric Wrist. *PLoS ONE* 11(10): e0148599.

Newington, L., Harris, E. C., & Walker-Bone, K. (2015). Carpal tunnel syndrome and work. *Best practice & research. Clinical rheumatology*, 29(3), 446-452.

Nichols, J. A., Bednar, M. S., & Murray, W. M. (2016). Surgical simulations based on limited quantitative data: understanding how musculoskeletal models can be used to predict motion arms and guide experimental design. *PLoS one*, 11(6), e0157346.

Nioback, P. C., Soestman, M., Daniel, J. R., Bittman, M., & Rosenwasser, M. P. (2017). Arthroscopic Wrist Debridement and Radial Styloectomy for Advanced Scapholunate Advanced Collapse Wrist: Long-Term Follow-Up. *HAND*, 15:589-607.

Norman, J., Baleskard, L., Thomson, M. W., & Kvernemo, H. D. (2018). Wrist malpractice claims in Northern Norway 2005-2014. Lessons to be learned. *International Journal of Circumpolar Health*, 77(1), 1483690.

Copyright Jodi Gootkin 2021

126

125

126

Oka, K., & Morimoto, H. (2018). Current Management of Scaphoid Nonunion Based on the Biomechanical Study. *Journal of wrist surgery*, 7(2), 94-100.

Oksyoglu, P., Nias, K., Kilinc, F., Tasdemir, N., Bozkurt, M., & Yildiz, I. (2015). Assessment of the Presence of Carpal Tunnel Syndrome in Patients with Diabetes Mellitus, Hypothyroidism and Acromegaly. *Journal of clinical and diagnostic research : JCDR*, 9(6), OC14-OC18.

O'Sullivan, S. J. (2010). Kienbock's disease. *Journal of Orthopaedic & Sports Physical Therapy*, 40(6), 376-376.

Osterås, N., Kjekshus, I., Smedslund G, Moe RH, Slatkowsky-Christensen B, Uhlig T, Hagen KB. (2017). Exercise for hand osteoarthritis. *Cochrane Database of Systematic Reviews* 2017, Issue 1. Art. No. CD010388.

Page MJ, Massy-Westropp N, O'Connor D, Pitt V. Splinting for carpal tunnel syndrome. *Cochrane Database Syst Rev*. 2012 Jul 11;7:CD010003.

Pelleiter, R., Bourbonnais, D., Higgins, J., Mireault, M., Danino, M.A., & Harris, P. (2018). Left Right Judgement Task and Sensor, Motor, and Cognitive Assessment in Participants with Wrist/Hand Pain. *Rehabilitation research and practice*.

Peters S, Page MJ, Coppeters MW, Ross M, Johnston V. (2016). Rehabilitation following carpal tunnel release. *Cochrane Database of Systematic Reviews* 2016, Issue 2. Art. No. CD004158. DOI: 10.1002/14651858.CD004158.pub3.

Pinckney, L. (2017). Dupuytren's disease. *The Cupola Scholarship at Gettysburg College*.

Pinho, A. B., & Sobania, R. L. (2017). Perilunate carpal dislocation. Clinical evaluation of patients operated with reduction and percutaneous fixation without capsular-ligament repair. *Revista Brasileira de Ortopedia (English Edition)*, 52(4), 402-409.

Pinnaveil R. (2011). Sticks and stones and broken bones: distal radius fractures in children. *Canadian family physician / Médecin de famille canadien*, 57(1), 45-46.

Raessadat, S.A., Karimzadeh, A., Hashemi, M., & Baghezadeh, L. (2018). Safety and efficacy of platelet-rich plasma in treatment of carpal tunnel syndrome: a randomized controlled trial. *BMC musculoskeletal disorders*, 19(1), 49.

Rainbow, M. J., Kamal, R. N., Leverthal, E., Akelman, E., Moore, D. C., Wolfe, S. W., & Crisco, J. J. (2013). In vivo kinematics of the scaphoid, lunate, capitate, and third metacarpal in extreme wrist flexion and extension. *The Journal of hand surgery*, 38(2), 278-288.

Rainbow, M. J., Kamal, R. N., Moore, D. C., Akelman, E., Wolfe, S. W., & Crisco, J. J. (2015). Subject-specific carpal ligament elongation in extreme positions, grip, and the dart thrower's motion. *Journal of biomechanical engineering*, 137(11), 111006.

Rankin IA, Sargeant H, Rehman H, Gurusamy KS. (2017). Low-level laser therapy for carpal tunnel syndrome. *Cochrane Database of Systematic Reviews* 2017, Issue 8. Art. No. CD012765.

Rieder, F.F., & Dekkers, T. (2018). The perioperative patient experience of hand and wrist surgical patients - An exploratory study using patient journey mapping. *Patient Experience Journal*, 5(3), 97-107.

Rohde, R. S., Crisco, J. J., & Wolfe, S. W. (2010). The advantage of throwing the first stone: how understanding the evolutionary demands of *Homo sapiens* is helping us understand carpal motion. *The Journal of the American Academy of Orthopaedic Surgeons*, 18(1), 51.

Roman-Liu, D., & Bartzuz, P. (2013). The influence of wrist posture on the time and frequency EMG signal measures of forearm muscles. *Gait & posture*, 37(3), 340-344.

Rouland, P., Phelan, N., Gardiner, S., Linton, K. N., & Galvin, R. (2015). The Effectiveness of Corticosteroid Injection for De Quervain's Stenosing Tenosynovitis (DQST): A Systematic Review and Meta-Analysis. *The open orthopaedics journal*, 9, 437-444.

Ruby, L. K., Conroy, W. P., An, K. N., Linscheid, R. L., & Chao, E. Y. S. (1988). Relative motion of selected carpal bones: a kinematic analysis of the normal wrist. *Journal of Hand Surgery*, 13(1), 1-10.

Saad, M. S. H. (2016). Measurement of Normal Median Nerve Area at the Level of the Wrist Joint in Adult Using Diagnostic Ultrasonography. *Doctoral Dissertation, Sudan University of Science and Technology*.

127

Sadura-Siekulka, T., Sokolowska, B., Prusinowska, A., Trzaska, A., & Kiejzopolska-Ortowska, K. (2018). Benefits of wrist splinting in patients with rheumatoid arthritis. *Reumatologia*, 56(6), 362-367.

Saha-Coll, G., Garcia-Elias, M., Leon-Lopez, M. T., Lusa-Perez, M., & Rodriguez-Baeza, A. (2011). Effects of forearm muscles on carpal stability. *Journal of Hand Surgery (European Volume)*, 36(7), 553-559.

Sandelin, H., Waris, E., Hivensalo, E. J., Vasenius, J., Huhtala, H., Raatikainen, T., & Heikman, T.H. (2018). Patient injury claims involving fractures of the distal radius. *Acta orthopaedica*, 89(2), 240-245.

Sang Ki, L. E. E., Young Dong, S. O. N. G., & Won Sik, C. H. O. Y. (2015). Correlation between dorsovolar translation and rotation of the radius on the distal radioulnar joint during supination and pronation of forearm. *Acta Orthopaedica Belgica*, 81, 511-522.

Sastry, T., Rishi, S., Colenci, R., Campos, R., Vassallo, D., & Cortopassi, A.C. (2018). 48h hand surgeries with local anesthesia with epinephrine, without a tourniquet, without sedation, and without an anesthesiologist. *Revista brasileira de ortopedia (English Edition)*, 53(3), 281-286.

Shah, D. S., & Kedgley, A. E. (2016). Control of a wrist joint motion simulator: a phantom study. *Journal of biomechanics*, 49(13), 3061-3068.

Shah, D. S., Middleton, C., Gurdezi, S., Horwitz, M. D., & Kedgley, A. E. (2017). The effects of wrist motion and hand orientation on muscle forces: a physiologic wrist simulator study. *Journal of biomechanics*, 60, 232-237.

Shah, D. S., Middleton, C., Gurdezi, S., Horwitz, M. D., & Kedgley, A. E. (2018). Alterations to wrist tendon forces following flexor carpi radialis or ulnaris sacrifice: a cadaveric simulator study. *The Journal of hand surgery (European Volume)*, 43(8), 886-888.

Shaver, M. J., & Chung, K. C. (2013). The Michigan hand outcomes questionnaire after 15 years of field trial. *Plastic and reconstructive surgery*, 131(5), 779e-87a.

Shinkai, H., Yamamoto, M., Tabe, M., Iwatsuki, K., Kurimoto, S., & Hirata, H. (2017). Non-invasive volumetric analysis of asymptomatic hands using a 3-D scanner. *PLoS one*, 12(8), e0182675.

Smart, K. M., Wand, B., & O'Connell, N. E. (2015). A Cochrane Systematic Review of physiotherapy for pain and disability in adults with Complex Regional Pain Syndrome (CRPS).

So, H., Chung, V.C., Cheng, J.C., & Yip, R.M. (2018). Local steroid injection versus wrist splinting for carpal tunnel syndrome: A randomized clinical trial. *International journal of rheumatic diseases*, 21, 1, 102-107.

Stanton, T. R., Ward, B. M., Carr, D. B., Binkley, F., Weisner, G. L., & O'Connell, N. E. (2013). Local anaesthetic sympathetic blockade for complex regional pain syndrome. *Cochrane Database of Systematic Reviews*, (8).

Steed, J. T., Drexler, K., Woodridge, A. N., & Ferguson, M. (2017). Anterior Interososseous Nerve Neuropraxia Secondary to Shoulder Arthroscopy and Open Subscapular Long Head Biceps Tenodesis. *Case reports in orthopaedics*, 2017.

Strong, J. P., Eschweizer, J., Knoke, M., Rennekampff, H. O., Rademacher, K., & Pallua, N. (2018). Impact of scapholunate dissociation on human wrist kinematics. *Journal of Hand Surgery (European Volume)*, 43(2), 179-186.

Strom, A. L., Agarwal, S., Gedema, P. S., & Levi, B. (2017). Peripheral Neuropathy and Nerve Compression Syndromes in Burns. *Clinics in plastic surgery*, 44(4), 793-803. doi:10.1016/j.cps.2017.05.010

Stroud, K., McPhee, M., Bell, A., Martin-Khan, M., & Russell, T. (2018). Best practice management of closed hand and wrist injuries in the emergency department (part 1 of the musculoskeletal injuries rapid review series). *Emergency Medicine Australasia*.

Stuyck FM, Dobeles S, Schaffer S-D, Mueller S, Ateschrang A, Baumann M, et al. (2015) Early Functional Postoperative Therapy of Distal Radius Fractures with a Dynamic Orthosis: Results of a Prospective Randomized Cross-Over Comparative Study. *PLoS ONE* 10(1):e0117720.

128

Suh, N., Ek, E. T., & Wolfe, S. W. (2014). Carpal fractures. *The Journal of hand surgery*, 39(4), 785-791.

Tanović, A.T., Tanović, E., Mekić, M., Simić, I.M., Papović, A., & Krpa, H. (2018). Effects of early diagnosis of the wrist over-use syndrome on the treatment. *Medicinski glasnik : official publication of the Medical Association of Zenica-Doboj Canton, Bosnia and Herzegovina*, 15(2), 168-173.

Tan Berg, P. W., Dirksingreen, T., Strackee, S. D., & Buijze, G. A. (2016). Classifications of Acute Scaphoid Fractures: A Systematic Literature Review. *Journal of Wrist Surgery*, 5(2), 152-159.

Tenório, P.H., Vieira, M., Albert, A.M., Abreu, M.F., Nakamoto, J.C., & Claiquet, A. (2018). Evaluation of intra- and interobserver reliability of the AO classification for wrist fractures. *Revista brasileira de ortopedia*, 53(6), 703-708.

Ting, J., Y. S. (2015). Rehabilitation of an athlete with Kienbock's disease. In *BMC proceedings* (Vol. 9, No. S3, p. A106). BioMed Central.

Turugut, A., Erkuş, S., Koca, A., Payzner, L., Çayık, A. O., & Kalenderci, Ö. (2018). Analysis of the factors causing tight cast syndrome after closed reduction and casting of pediatric distal radius fractures. *Acta orthopaedica et traumatologica turcica*, 52(5), 329-333.

Vahed, L.K., Ariyanpur, A., Gharedaghi, M.B., & Rezaei, H. (2018). Ultrasound as a diagnostic tool in the investigation of patients with carpal tunnel syndrome. *European journal of translational myology*, 28(2).

Vajdic, K., Mark, T. A systematic review of conservative interventions for osteoarthritis of the hand. *Journal of Hand Therapy*, 2010; 23: 334-351.

van Doesburg MHM, Henderson J, Mink van der Molen AB, An K-N, Amadio PC (2012) Transverse Plane Tendon and Median Nerve Motion in the Carpal Tunnel: Ultrasound Comparison of Carpal Tunnel Syndrome Patients and Healthy Volunteers. *PLoS ONE* 7(5): e37081.

Vardakastani, V., Bell, H., Mee, S., Briggsstocke, G., & Kedgley, A. E. (2018). Clinical measurement of the dart throwing motion of the wrist: variability, accuracy and correction. *Journal of Hand Surgery (European Volume)*, 43(5):1634-1637.

Verdecchia, N.M., Johnson, J., Baratz, M., & Crebaugh, S. (2018). Neurologic complications in common wrist and hand surgical procedures. *Orthopedic reviews*, 10(1).

Vezedidis, P. S., Yoshikawa, H., Hart, R., & Blazar, P. (2010). Ulnar-sided wrist pain. Part I: anatomy and physical examination. *Skeletal radiology*, 39(8), 733-745.

Washington State Department of Labor. (2014). *Work-Relatedness, I.E., Assessment, A. E., & Worksheet, V. E. Work-Related Carpal Tunnel Syndrome Diagnosis and Treatment Guideline*.

Werner, F.W., & Short, W.H. (2018). Carpal Pronation and Supination Changes in the Unstable Wrist. *Journal of wrist surgery*, 7, 4, 298-302.

Wirthel, J. D. R., Zhao, C., An, K. N., & Amadio, P. C. (2014). Carpal tunnel syndrome pathophysiology: role of subsynovial connective tissue. *Journal of wrist surgery*, 3(04), 220-226.

Wijffels, M. M. E., Brink, P. R. G., & Schipper, I. B. (2012). Clinical and non-clinical aspects of distal radioulnar joint instability. *The Open Orthopaedics Journal*, 6, 204.

Williams MA, Srikesavan C, Heine PJ, Bruce J, Broseau L, Hovey-Thomas N, Lamb SE. (2018). Exercise for rheumatoid arthritis of the hand. *Cochrane Database of Systematic Reviews* 2018, Issue 7. Art. No. CD003832.

Wolfe, S.W. (2013). 17 Distal Radius Fractures.

Woo, Ha-Chi et al. "Development of Kinematic Graphs of Median Nerve during Active Finger Motion: Implications of Smartphone Use." *PLoS one* vol. 11, e0158455. 1 Jul. 2016.

Copyright: Jodi Gootkin 2021

129

Xiao, X., Huang, J., Chen, Z., Xia, X., Wang, S., & Yang, Z. (2018). Effects of computer-assisted wrist/hand training on the improvement of hand function in traumatic hand injuries. *International Journal Of Clinical And Experimental Medicine*, 11(2), 1208-1216.

Xie, C., Gnanesegaran, G., Mohan, H., & Liveratos, L. (2013). Assessment of Inter-modality Spatial Alignment Accuracy in Hybrid Single-Photon Emission Computed Tomography in Patients with Hand and Wrist Pain. *World Journal of nuclear medicine*, 12(3), 87-93.

Yoon, A. P., Mathews, A. L., Huettnerer, H. E., Meckholt, B. F., & Chung, K. C. (2018). Improving effective magnetic resonance imaging (MRI) application in soft tissue wrist injury. *The Journal of the American Board of Family Medicine*, 31(5), 795-804.

Zengin, E. C., Özcan, C., Jastan, C., Bulut, B., & Sener, M. (2018). Cast immobilization versus volar locking plate fixation of AO type C distal radius fractures in patients aged 60 years and older. *Acta orthopaedica et traumatologica turcica*.

Zhang, L., Cao, H., Zhang, Q., Fu, T., Yin, R., Xia, Y., Li, L., & Gu, Z. (2018). Motion analysis of the wrist joints in Chinese rheumatoid arthritis patients: a cross-sectional study. *BMC musculoskeletal disorders*, 19(1), 270.

Zhang, P., Jia, B., Chen, X. K., Wang, Y., Huang, W., & Wang, T. B. (2018). Effects of surgical and nonoperative treatment on wrist function of patients with distal radius fracture. *Chinese Journal of Traumatology*, 21(1), 30-33.

Copyright: Jodi Gootkin 2021

130

## Wrist and Hand Disorders Resources

Disease Activity Score (DAS28)

<https://www.das28.nl/das28/en/introduction-menu.html>

Focus on Therapeutic Outcomes Elbow, Wrist, and Hand (FOTO)

[https://cdn2.hubspot.net/hubfs/442011/NQF/2018%20Updates/Short%20Forms/Elbow%20Wrist%20Hand%20Functional%20Status\\_QPP%23222\\_NQF%230427\\_2018.pdf?t=1519935041375](https://cdn2.hubspot.net/hubfs/442011/NQF/2018%20Updates/Short%20Forms/Elbow%20Wrist%20Hand%20Functional%20Status_QPP%23222_NQF%230427_2018.pdf?t=1519935041375)

The Michigan Hand Outcomes Questionnaire (MHQ)

<http://mhq.lab.medicine.umich.edu/home>

[https://download.lww.com/wolterskluwer\\_vitalstream\\_com/PermaLink/PRS/A/PRS\\_128\\_1\\_2011\\_05\\_11\\_CHUNG\\_203363\\_SDC1.pdf](https://download.lww.com/wolterskluwer_vitalstream_com/PermaLink/PRS/A/PRS_128_1_2011_05_11_CHUNG_203363_SDC1.pdf)

Patient Rated Wrist Evaluation (PRWE)

[https://static-content.springer.com/esm/art%3A10.1186%2F1471-2474-4-24/MediaObjects/12891\\_2003\\_60\\_MOESM1\\_ESM.pdf](https://static-content.springer.com/esm/art%3A10.1186%2F1471-2474-4-24/MediaObjects/12891_2003_60_MOESM1_ESM.pdf)

Boston Carpal Tunnel Questionnaire (BCTQ)

<https://journals.plos.org/plosone/article/file?id=info:doi/10.1371/journal.pone.0129918.s002&type=supplementary>

Copyright Jodi Gootkin 2021