

# Distal Upper Extremity Surgical Management Goals and Objectives

## Course Description

"Distal Upper Extremity Surgical Management" is an online recorded video of a previously presented live CE webinar for rehabilitation professionals that examines surgical procedures to manage common orthopedic pathologies of the distal upper extremity. This course includes a review of current literature relating to surgical procedures for nerves, tendons, ligaments, and bones of the forearm, wrist and hand.

## Course Rationale

The purpose of this course is to provide an understanding of the current trends in surgical procedures to manage degenerative, traumatic and non-traumatic pathologies of forearm, wrist, and hand. The emphasis is comparative analysis of contemporary surgical techniques to restore distal upper extremity function through repair of nerves, tendons, ligaments, and bones.

## Course Goals and Objectives

Upon completion of this course, participants will be able to:

1. List and identify common anatomical structures of the wrist and hand.
2. Distinguish neuropathy, degenerative, traumatic, and non-traumatic distal upper extremity pathologies.
3. Identify emerging surgical techniques for distal upper extremity pathologies.
4. Compare nerve decompression, nerve repair, and nerve transfer surgical procedures.
5. Identify the zones of flexor tendon repair and surgical repair techniques.
6. Identify fascia surgical techniques to manage conditions of the wrist and hand.
7. List surgical mechanisms of stabilization of forearm and carpal fractures.
8. Identify post-surgical complications during healing of distal upper extremity fractures.
9. Recognize common arthroplasty surgical techniques for the wrist and hand.

**Course Provider** – Innovative Educational Services

**Provider Contact Information** – [information@cheapceus.com](mailto:information@cheapceus.com)

**Course Instructor** – Jodi Gootkin, PT, Med, CEAS

**Financial/Non-financial Disclosure** - Neither the Provider nor the instructor have any financial or non-financial conflict of interest related to the presentation of this CE program.

**Target Audience** – Occupational Therapists, Occupational Therapy Assistants

**OT Scope of Practice** – Foundational Knowledge

**Course Educational Level** – This course is applicable for introductory learners.

**Course Prerequisites** – None

**Instructional Method** – Distance Learning – Independent; Asynchronous online video-based home study

**Location** - Cheapceus.com

**Date** – Continuously available on-demand

**PD Activity Completion Requirements / Criteria for Issuance of CE Credits** – Completion of viewing of 3 hour recorded video, and a score of 70% correct or greater on the course post-test.

**Continuing Education Credits** – Three (3) contact hours / .3 AOTA CEUs

**Course Fee** - \$34.95

**Registration Information** – No pre-registration required; available on-demand at Cheapceus.com

**Special Needs Requests** – Email: [information@cheapceus.com](mailto:information@cheapceus.com) or phone: 954-663-4101

**Cancellation by the Learner** – Learners may cancel their participation at any time and receive a full refund of all paid fees.

**Cancellation by the Provider** – Registrants for the cancelled activity will be contacted by an IES staff member via phone call or email within 12 hours of the cancellation decision. If the decision to cancel is made less than 14 hours prior to the event, each participant will be contacted no later than 2 hours prior to the scheduled start time of the activity. Registrants will receive a full refund if an activity is cancelled by the Provider. The refund will be processed back to the Registrant within 12 hours of the cancellation.

**Complaint Resolution** – Please call 954-663-4101 (24 hours/day, 7 days/week) to speak with a live customer service agent. Our goal is to work with our customers to resolve all issues to the customer's satisfaction with just one phone call whenever possible.

**Refund Policy** - Unrestricted 100% refund upon request. The request for a refund by the learner shall be honored in full without penalty or other consideration of any kind. The request for a refund may be made by the learner at any time without limitations before, during, or after course participation.



Innovative Educational Services is an AOTA Approved Provider of professional development. PD activity approval ID# 5471. This Distance Learning – Independent PD activity is offered at .3 CEUs; Introductory; OT Foundational Knowledge. The assignment of AOTA CEUs does not imply endorsement of specific course content, products, or clinical procedures by AOTA.

# Distal Upper Extremity Surgical Management

Presented By  
Jodi Gootkin, PT, MEd, CEAS  
jodiemail@comcast.net

Copyright Jodi Gootkin

1

## Course Overview

- “Distal Upper Extremity Surgical Management” examines surgical procedures to manage common orthopedic and neurologic pathologies of the distal upper extremity. This course includes a review of current literature relating to surgical procedures for nerves, tendons, ligaments, and bones of the forearm, wrist and hand.

Copyright Jodi Gootkin

2

## Course Rationale

- The purpose of this course is to provide an understanding of the current trends in surgical procedures to manage degenerative, traumatic and non-traumatic pathologies of forearm, wrist, and hand. The emphasis is comparative analysis of contemporary surgical techniques to restore distal upper extremity function through repair of nerves, tendons, ligaments, and bones.

Copyright Jodi Gootkin

3

## Goals and Objectives

1. List and identify common anatomical structures of the wrist and hand.
2. Distinguish neuropathy, degenerative, traumatic, and non-traumatic distal upper extremity pathologies.
3. Identify emerging surgical techniques for distal upper extremity pathologies.
4. Compare nerve decompression, nerve repair, nerve graft, and nerve transfer surgical procedures.
5. Identify the zones of flexor tendon repair and surgical repair techniques.
6. Describe fascia surgical techniques to manage conditions of the wrist and hand.
7. List surgical mechanisms of stabilization of forearm and carpal fractures.
8. Identify post-surgical complications during healing of distal upper extremity fractures.
9. Describe the surgical technique to manage thumb osteoarthritis.
10. Recognize common hand splints indicated to manage wrist and hand disorders.

Copyright Jodi Gootkin

4

## Disclaimer

- Application of concepts presented in this webinar is at the discretion of the individual participant in accordance with federal, state, and professional regulations.

Copyright Jodi Gootkin

5

Topic	Time
Wrist and Hand Anatomy and Arthrokinematics	0:00-0:10
Surgical Technique and Anesthesia	0:11-0:15
Peripheral Nerve Injury	0:16-0:20
Nerve Repair, Graft, and Transfer	0:21-0:30
Compressive Neuropathy	0:31-0:35
Carpal Tunnel Release	0:36-0:50
Interactive Discussion of Clinical Applications	0:51-1:00
Ulnar Nerve Decompression	1:01-1:05
Decompressive Fasciotomy	1:06-1:10
Tendon Transfer	1:11-1:15
Flexor Tendon Repair	1:16-1:30
Trigger Finger and De Quervain's Tendon Release	1:31-1:40
Dupuytren's Fasciotomy and Fasciectomy	1:41-1:50
Interactive Discussion of Clinical Applications	1:51-2:00
Nerve, Fascia, and Tendon Rehab Considerations	2:01-2:05
Trapeziectomy	2:06-2:10
Distal Radius Fracture Stabilization	2:11-2:15
Scaphoid Fracture Stabilization	2:16-2:25
Perilunate Fracture Dislocation Management	2:26-2:30
Kienbock's Surgery	2:31-2:35
Casts and Splints	2:36-2:45
Adaptive Equipment	2:46-2:50
Interactive Discussion of Clinical Applications	2:51-3:00



## Course Outline and Schedule

Consider This

Copyright Jodi Gootkin

6

Distal Upper Extremity Surgical Management

Copyright Innovative Educational Services and Jodi Gootkin. All rights reserved.

Reproduction, reuse, or republication of all or any part of this presentation is strictly prohibited without prior written consent of both Innovative Educational Services and Jodi Gootkin.

## How To Obtain CEUs For This Course

- ▶ After watching the video go to [www.cheapceus.com](http://www.cheapceus.com)
- ▶ Complete the post test with score of at least 70%
  - ▶ May be retaken multiple times
- ▶ Submit online payment for course
- ▶ Print certificate
- ▶ **Course review and summary for post test at the end of the webinar.**



Consider This

Copyright Jodi Gootkin

7

## Distal Upper Extremity Anatomy

### ▶ Proximal to Distal

Humerus, Radius, Ulna	Elbow Joint	
Radius and Ulna	Radiocarpal Joint (Wrist)	Proximal and Distal Radioulnar Joints (PRUJ, DRUJ)
Carpals	Midcarpal Joint	Intercarpal Joints
Metacarpals	Metacarpal Phalangeal Joint (MCP)	
Phalanges	Proximal and Distal Interphalangeal Joint (PIP, DIP)	Thumb Interphalangeal Joint (IP)


Image: By LadyofPhos Mariana Ruiz Villarreal - Some of my sources: [1], Gray's Anatomy "Williams & Warwick", Atlas der Anatomie des Menschen "Schober", Anatomia del cuerpo humano "Tobisch, Rhein, u. et al.", and a termia printed by "Jodger anatomie GmbH" - LadyofPhos, Public Domain.

Copyright Jodi Gootkin

8

## Carpal Bones

- ▶ The 8 small bones are arranged into a proximal and distal row.
- ▶ Clockwise from Thumb:
  - ▶ Straight Line To Pinky, Here Comes The Thumb
- ▶ Counter clockwise from Pinky:
  - ▶ PTs Love Sundaes, Ten Toppings Can't Hurt



Copyright Jodi Gootkin

9

## Normal Arthrokinematics

- ▶ Bony architecture and ligamentous stability allow the hand to sustain external loads and perform fine motor tasks.
- ▶ The wrist complex controls the length tension relationship of the extrinsic hand muscles.

Copyright Jodi Gootkin

10

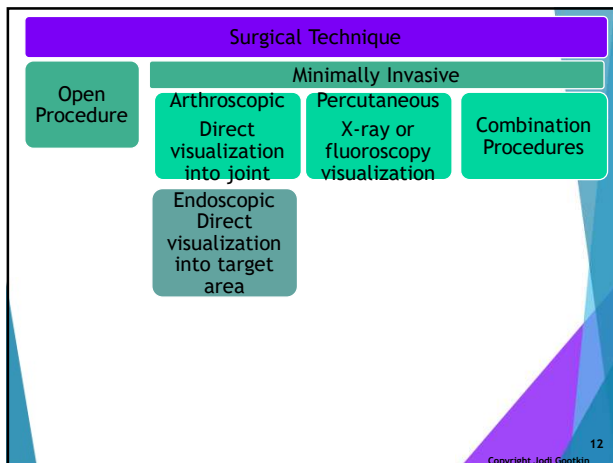
## Surgical Alteration of Biomechanics

- ▶ Surgical modifications to anatomical structures alters the geometry of the wrist and hand bones.
- ▶ Minor changes in joint congruency shift muscle-tendon paths resulting in altered biomechanics, force generation and post operative function.

Consider This

Copyright Jodi Gootkin

11



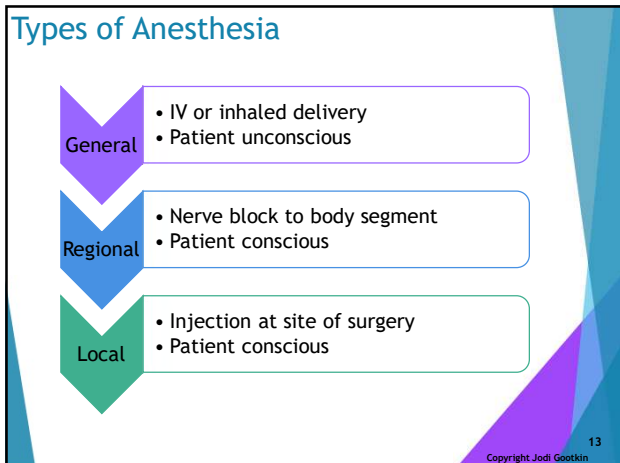
Copyright Jodi Gootkin

12

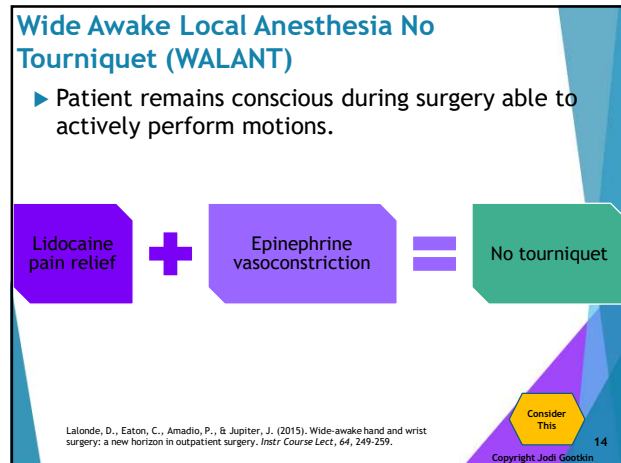
Distal Upper Extremity Surgical Management

Copyright Innovative Educational Services and Jodi Gootkin. All rights reserved.

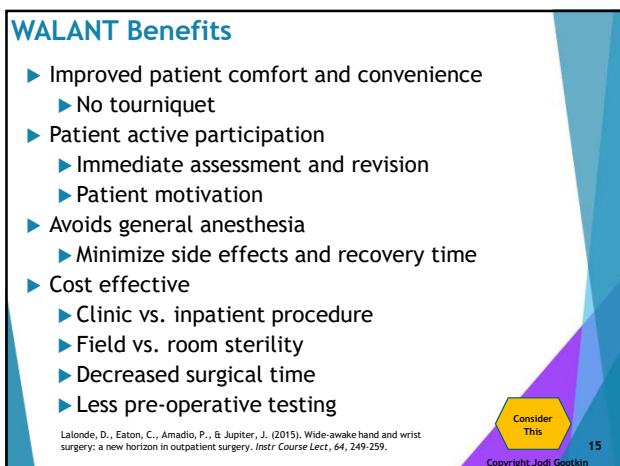
Reproduction, reuse, or republication of all or any part of this presentation is strictly prohibited without prior written consent of both Innovative Educational Services and Jodi Gootkin.



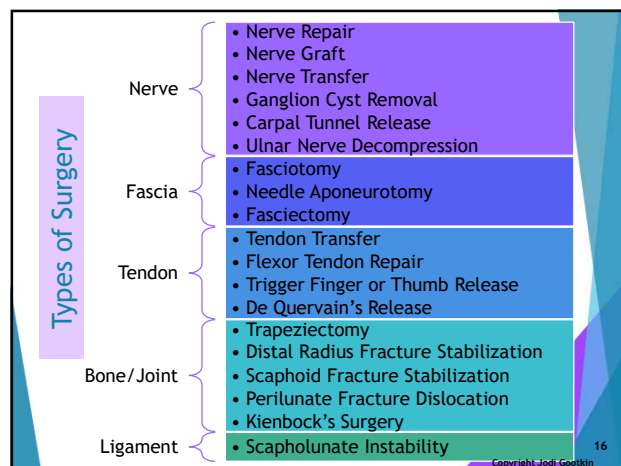
13



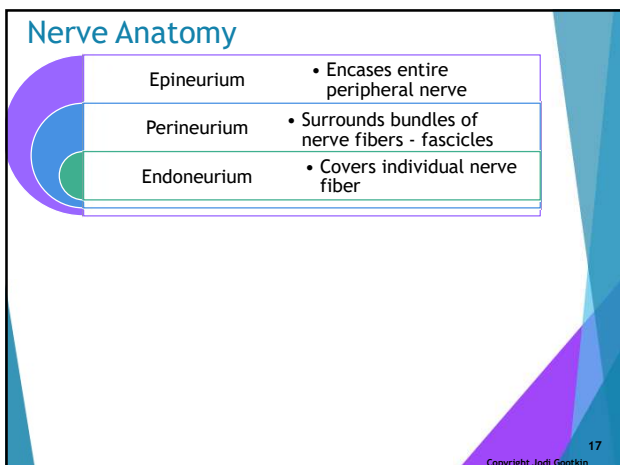
14



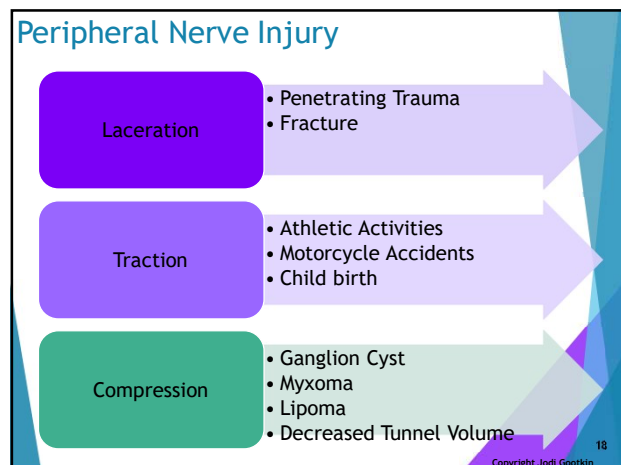
15



16



17

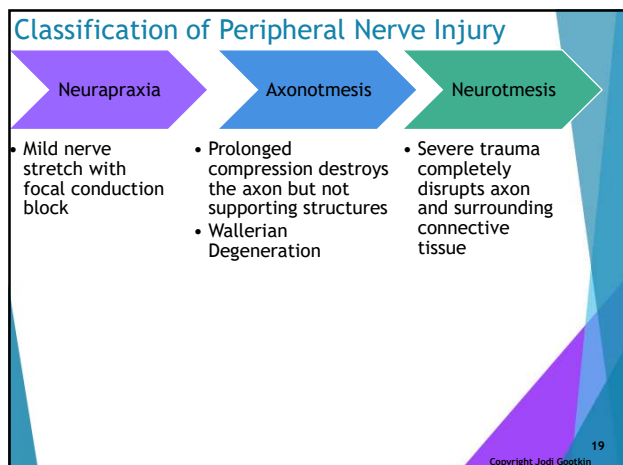


18

Distal Upper Extremity Surgical Management

Copyright Innovative Educational Services and Jodi Gootkin. All rights reserved.

Reproduction, reuse, or republication of all or any part of this presentation is strictly prohibited without prior written consent of both Innovative Educational Services and Jodi Gootkin.



19

### Nerve Repair

- ▶ Sharp lacerations can sever nerves requiring fascicular matching of the proximal and distal segments.
- ▶ Direct repair is performed with end-to-end epineurial microsutures.
- ▶ Caution is taken when approximating the nerve to avoid strangulated or loose nerve ends of the coaptation.

Rinker, B. D. (2018). Nerve Repair Manual: A Practical Approach to Injuries and Repair in the Brachial Plexus and Upper Extremity. *Annals of plastic surgery*, 80(1), e1.

Copyright Jodi Gootkin

20

### Nerve Graft

- ▶ A primary repair may not be possible if too much tension would be created or if there is a loss of nerve length not allowing the ends to approximate.

**Autograft**

- Provides original internal scaffolding
- Medial antebrachial cutaneous
- Radial sensory branch
- Dorsal ulnar cutaneous

**Allograft**

- Host axons and Schwann cells repopulate scaffold
- Decellularized to minimize immunogenic reactions

Huachyar, K. S., Momeni, A., Pyles, M. N., Cha, J. Y., Maan, Z. N., Ducher, D., ... & Schoonhoven, J. V. (2016). The role of current techniques and concepts in peripheral nerve repair. *Plastic surgery international*, 2016.

Copyright Jodi Gootkin

21

### Artificial Conduits

- ▶ Biologic or synthetic conduits are used to bridge the defect in the nerve to guide regeneration.
- ▶ Implants may be laced with support cells and nerve growth factor to enhance axon migration.

Arslantunali, D., Dursun, T., Yucel, D., Hasirci, N., & Hasirci, V. (2014). Peripheral nerve conduits: technology update. *Medical devices (Auckland, N.Z.)*, 7, 405-424.

Copyright Jodi Gootkin

22

### Nerve Transfer

- ▶ A non-critical close proximity donor nerve is relocated to the recipient muscle or skin region to restore motor and/or sensory innervation.
- ▶ Slow regeneration rates and motor end plate degradation over time may preclude muscle recovery in larger motor nerve defects.

**Motor**

- Expendable donor from less important limb muscle
- Intrinsic hand function

**Sensory**

- Sacrifice donor sensory distribution
- Critical sensation for grasp

Grinnell, D., & Keating, C. P. (2014). Peripheral nerve reconstruction after injury: a review of clinical and experimental therapies. *BioMed research international*, 2014, 698256. doi:10.1155/2014/698256

Copyright Jodi Gootkin

23

### Nerves Used for Transfer

- ▶ Preference is to utilize a nerve that innervates a synergistic muscle and is in close proximity for tension free transfer.

Damaged	Lost	Transferred
Radial	Motor wrist, finger, thumb extension	Median from FDS, PL, FCR
Median	Sensory thumb and index	Ulnar Digital Branch
Ulnar	Hand intrinsic	Median Anterior Interosseous Branch

Copyright Jodi Gootkin

24

## Neuroma Complication

- ▶ Neuroma formation during healing can lead to sensory loss, neuropathic pain, or the need for revision surgery.
- ▶ The inflammatory reaction during healing and increased concentration of nerve growth factor leads to connective tissue hyperplasia.

25

Copyright Jodi Gootkin

25

## Nerve Repair, Grafting, Transfer Rehab

- ▶ Immobilization without tensioning the nerve site followed by gradual mobilization to prevent joint contracture.
- ▶ Hyperesthesia during healing is a positive indicator of regeneration.
  - ▶ In pediatrics manifests as biting
- ▶ Patient education on safety particularly related to hot and cold sensation.
- ▶ Alternating current electrical stimulation can be initiated once volitional twitch contraction is evident.

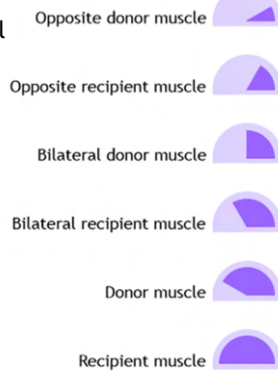
26

Copyright Jodi Gootkin

26

## Muscle Re-education

- ▶ Biofeedback may be helpful to facilitate cortical remapping for recruitment of muscle that received nerve transfer.
- ▶ Typically rehab progression
  - ▶ Phase 1 high frequency, low load activation
  - ▶ Phase 2 progression from assisted to active then resisted exercise



Novak, C. B., & von der Heyde, R. L. (2015). Rehabilitation of the upper extremity following nerve and tendon reconstruction: when and how. *Seminars in plastic surgery*, 29(1), 73-80. doi:10.1055/s-0035-1544172

Copyright Jodi Gootkin

27

## Compressive Neuropathy

- ▶ Nerves pass through anatomic tunnels often along with tendons and vascular structures.
- ▶ Decreased nerve conduction can result from increased volume of contents or reduced size of the tunnel.
- ▶ When conservative management fails or space occupying lesions are identified surgery may be necessary.

Images: Cropped  
https://www.ncbi.nlm.nih.gov/pmc/articles/PMC4472390/

28

Copyright Jodi Gootkin

28

## Ganglion Cyst

- ▶ A ganglion cyst is a small fluid filled sac arising from an extension of the synovial joint capsule or inflamed tendon sheath.
- ▶ Patients may be asymptomatic or present with nerve compression weakness and/or sensory impairment.

29

Copyright Jodi Gootkin

29

## Ganglion Cyst Excision

- ▶ The cyst is removed along with a section of tissue near the tendon sheath or joint to minimize the risk of the cyst reforming.

30

Copyright Jodi Gootkin

30



## Carpal Tunnel Syndrome

- ▶ Entrapment of the median nerve occurs beneath the flexor retinaculum of the wrist resulting in weakness.
- ▶ Motor weakness of the hand intrinsic and thenar muscles limits grasp and pinch.
- ▶ Sensory impairment involves the palmar surface and dorsal nail bed of the thumb, index, middle, and radial side of ring finger.
- ▶ Surgery is indicated when conservative management fails to relieve persistent numbness and thenar wasting is evident.

Copyright Jodi Gootkin 31

31

## Carpal Tunnel Anatomy

- ▶ Tendons of the flexor digitorum profundus and superficialis along with the median nerve are encased in a synovial membrane.
- ▶ Subsynovial connective tissue is layered within the tunnel to minimize shear stress with hand motion.

Copyright Jodi Gootkin 32

32

## Carpal Tunnel Release (CTR)

- ▶ Open surgical decompression to divide the transverse carpal ligament increasing the space available for the median nerve and finger flexor tendons.
- ▶ Mini-open repair may provide earlier symptom relief and return to activity, but long-term outcomes compared to standard open release are inconclusive.

American Academy of Orthopaedic Surgeons. (2016). Management of carpal tunnel syndrome: evidence-based clinical practice guidelines. 2016. Copyright Jodi Gootkin 33

33

## Endoscopic CTR

- ▶ Endoscopic release with small ports allows incision only of the tissue contributing to the compression.

American Academy of Orthopaedic Surgeons. (2016). Management of carpal tunnel syndrome: evidence-based clinical practice guidelines. 2016. Copyright Jodi Gootkin 34

34

## Ultra Minimally Invasive CTR

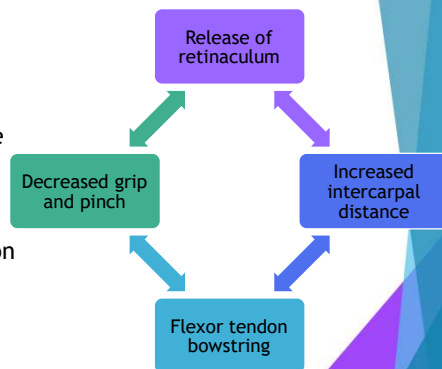
- ▶ Emerging techniques incorporate ultrasound guiding to visualize structures with only one tiny incision for the knife.

Petrover, D., Silvera, J., De Baere, T., Vigan, M., & Hakime, A. (2017). Percutaneous Ultrasound-Guided Carpal Tunnel Release: Study Upon Clinical Efficacy and Safety. *Cardiovascular and Interventional radiology*, 40(4), 568-575. Copyright Jodi Gootkin 35

35

## Flexor Retinaculum Reconstruction

- ▶ Research varies regarding the benefit of flexor retinaculum reconstruction or lengthening.

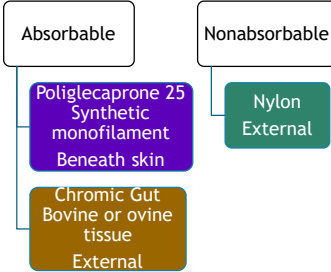


American Academy of Orthopaedic Surgeons. (2016). Management of carpal tunnel syndrome: evidence-based clinical practice guidelines. 2016. Lai, S., Zhang, K., Li, J., & Fu, W. (2019). Carpal tunnel release with versus without flexor retinaculum reconstruction for carpal tunnel syndrome at short- and long-term follow-up—A meta-analysis of randomized controlled trials. *PLoS one*, 14(1), e0211369. Pavlidis, L., Chalkidis, B. E., Demir, E., & Dimitriou, C. G. (2010). The effect of transverse carpal ligament lengthening on carpal tunnel volumetry: a comparison between four techniques. *Annals of plastic surgery*, 65(5), 480-484. Copyright Jodi Gootkin 36

36

### CTR Sutures

- ▶ The initial tensile strength of absorbable sutures diminishes as they dissolve.
- ▶ Nylon sutures require manual removal as healing of the incision occurs.



Copyright Jodi Gootkin

37

### CTR Post Operative Splinting

- ▶ According to the AAOS, strong evidence indicates no enhancement of long-term outcomes with the use of post operative splinting.

American Academy of Orthopaedic Surgeons. (2016). Management of carpal tunnel syndrome: evidence-based clinical practice guidelines. 2016.

Copyright Jodi Gootkin

38

### CTR Complications

- ▶ Injury to palmar cutaneous or recurrent motor branch of median nerve
- ▶ Hypertrophic scarring
- ▶ Tendon adhesion
- ▶ Hematoma or infection
- ▶ Complex Regional Pain Syndrome (CRPS)
- ▶ Pillar Pain

Copyright Jodi Gootkin

39

### Post Operative Pain

- ▶ Assess patient to determine the specific location of pain at thenar and hypothenar muscle insertions on flexor retinaculum or directly along the incision.

P  
A  
I  
N  
E  
D

Incision Pain

At incision site

Resolves in days to weeks

Pillar Pain

At ridge of trapezium, scaphoid tubercle, pisiform, or hook of hamate

May persist for several months

Copyright Jodi Gootkin

40

### Complex Regional Pain Syndrome (CRPS)

- ▶ Post-operative CRPS may result in pain levels significantly exceeding pre-operative pain.
- ▶ Monitor patients for signs including:
  - ▶ Allodynia
  - ▶ Burning pain
  - ▶ Edema
  - ▶ Trophic skin changes

Copyright Jodi Gootkin

41

### CTR Rehab

Day 2

Incision protection  
Edema control  
Tendon gliding  
Thumb and digit IP blocked AROM

Active wrist ROM

Week 3

Nerve gliding  
Scar massage and desensitization  
Theraputty grip and pinch  
Strengthening

Copyright Jodi Gootkin

42



## CTR Post-op Rehab Research

- Current research does not reflect a clear benefit of post-operative rehabilitation to improve outcomes.

Cohort	Interventions	Outcomes
2016 Cochrane Review	Splinting Exercise Cryotherapy Scar desensitization	Limited low quality evidence of benefit
2015 AAOS Guidelines	Supervised therapy	Moderate evidence no additional benefit

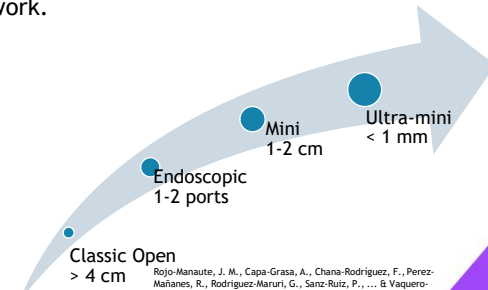
Peters S, Page MJ, Coppieters MW, Ross M, Johnston V. (2016). Rehabilitation following carpal tunnel release. Cochrane Database of Systematic Reviews 2016, Issue 2. Art. No.: CD004158.  
American Academy of Orthopaedic Surgeons. (2016). Management of carpal tunnel syndrome: evidence-based clinical practice guidelines. 2016.

Copyright Jodi Gootkin

43

## CTR Outcomes

- Smaller incisions result in better cosmetic results, lower pain rates, and faster return to work.



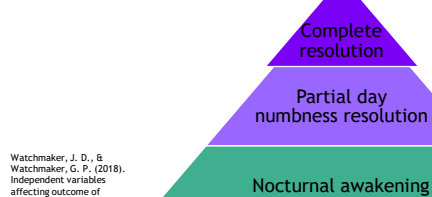
Rojas-Manaute, J. M., Capa-Grasa, A., Chana-Rodríguez, F., Pérez-Mañanes, R., Rodríguez-Maruri, G., Sanz-Ruiz, P., ... & Vaquerro-Martin, J. (2016). Ultra-Minimally Invasive Ultrasound-Guided Carpal Tunnel Release: A Randomized Clinical Trial. *Journal of Ultrasound in Medicine*, 35(6), 1149-1157.

Copyright Jodi Gootkin

44

## CTR Sensory Outcomes

- The vast majority of patients experience improvement in sensation, but the extent varies.
- The persistence of nocturnal awakening is infrequent.
- Percentage improvement of numbness appears to diminish with advancing age.

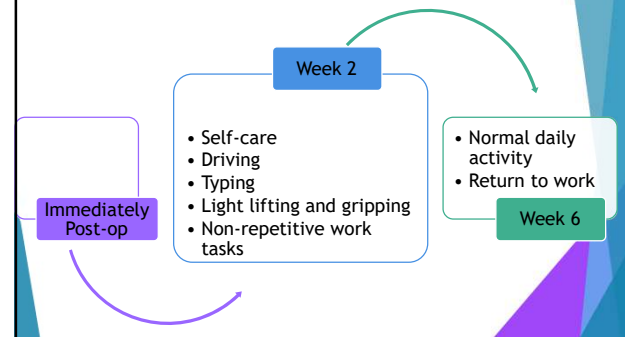


Watchmaker, J. D., & Watchmaker, G. P. (2018). Independent variables affecting outcome of carpal tunnel release surgery. *HAND*, 13(3), 285-291.

45

45

## CTR Return to Function

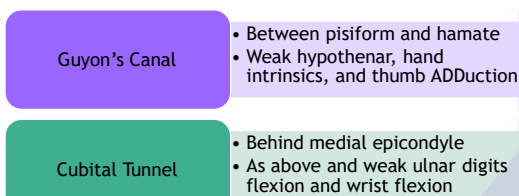


Copyright Jodi Gootkin

46

## Ulnar Nerve Compression Syndrome

- Traumatic, overuse or space occupying lesions result altered sensation of the ring and pinky finger combined with motor impairment.



47

47

## Cubital Tunnel Cyst

- Space occupying lesions or altered bone geometry from fracture can create compression of the ulnar nerve behind the medial epicondyle of the humerus.

Copyright Jodi Gootkin

48

## Ulnar Nerve Decompression

- ▶ Post traumatic skeletal deformity altering geometry of the cubital tunnel may require surgical decompression.

### Decompression

- Fewer complications

### Anterior Transposition

- New compression point risk

### Medial Epicondylectomy

- Medial elbow destabilization risk

49

Copyright Jodi Gootkin

49

## Restoring Functional Fine Motor

- ▶ Tendon transfer from the thumb can restore the lateral prehension due to atrophy of index finger dorsal interossei muscle.

Bruner  
Extensor Pollicis Brevis  
Interphalangeal stability

Neviaser  
Abductor Pollicis Longus  
Requires tendon grafting

Nobuta, S., Sato, K., Kanazawa, K., Hatori, M., & Itoi, E. (2009). Effects of tendon transfer to restore index finger abduction for severe cubital tunnel syndrome. *Upsala Journal of medical sciences*, 114(2), 95-99. doi:10.1080/03009730802702602

50

Copyright Jodi Gootkin

50

## Guyon's Canal Cyst

- ▶ Surgical excision is required to restore motor function to hypothenar muscles and sensation to pinky and ring fingers.

51

Copyright Jodi Gootkin

51

## Guyon's Canal Decompression

- ▶ Variability in the motor and sensory branches of the ulnar nerve complicate surgery.

52

Copyright Jodi Gootkin

52

## Compartment Syndrome



- ▶ Altered hemodynamics of forearm and hand fascial compartments occurs from acute trauma or chronic overuse of forearm muscles.
- ▶ Post trauma patients must be monitored for the "6Ps"
  - ▶ Pain disproportionate to injury
  - ▶ Paresthesia
  - ▶ Pallor
  - ▶ Paralysis
  - ▶ Poikilothermia
  - ▶ Pulselessness

Consider This

53

Copyright Jodi Gootkin

53

## Decompressive Fasciotomy

- ▶ Incisions into the fascia relieve pressure to restore perfusion to nerves, muscles, and soft tissues to avoid severe ischemia requiring amputation.
- ▶ Surgical site is often left open for irrigation and debridement in the days following initial surgery.

54

Copyright Jodi Gootkin

54

## Volkmann's Contracture

- Muscle necrosis from tissue hypoxemia leading to contracture of the wrist and fingers is graded based on the Tsuge Classification.

Stage	Affected muscle	Treatment
Mild	Finger flexors	Splinting & tendon lengthening
Moderate	Wrist and finger flexors	Excision of necrotic tissue, neurolysis, tendon transfer
Severe	Wrist and finger flexors and extensors	

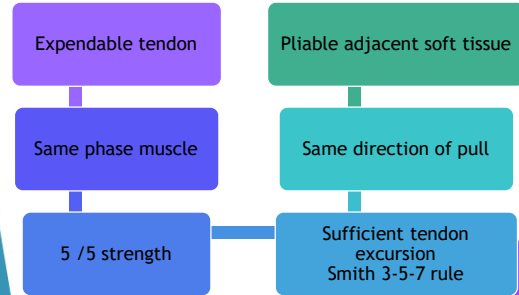
55

Copyright Jodi Gootkin

55

## Tendon Transfer

- Tendon transfer may be indicated to restore functional hand to use after nerve injury, rupture due to fracture, or necrosis.



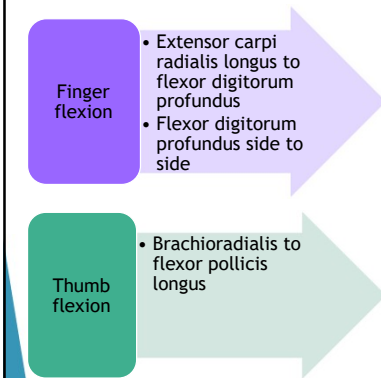
Carl DJ, Habusta SF. Hand, Tendon Transfers. [Updated 2018 Oct 27]. In: StatPearls [Internet]. Treasure Island (FL): StatPearls Publishing; 2019 Jan-. Available from: <https://www.ncbi.nlm.nih.gov/books/NBK499359/>

56

Copyright Jodi Gootkin

56

## Common Transfer Muscles



57

Copyright Jodi Gootkin

57

## Flexor Tendon Injury

- Traumatic closed or open injury lacerating tendons of the flexor digitorum profundus (FDP) and flexor digitorum superficialis (FDS).
- Camper's Chiasm is where the FDS splits into 2 segments allowing the FDP tendon to pass through to insert on distal phalanx.

**F D i P**  
**e e p**

Consider This

58

Copyright Jodi Gootkin

58

## Zones of Injury

Zone I	Distal to the FDS insertion near tip of finger
Zone II	FDS insertion to distal palmar crease or MCP A1 pulley No Man's Land
Zone III	A1 pulley to carpal ligament in palm region
Zone IV	Carpal tunnel near wrist crease
Zone V	Proximal to carpal tunnel

Consider This

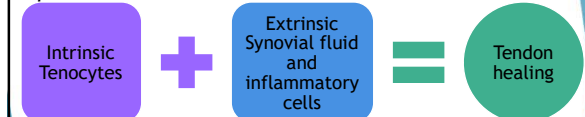59

Copyright Jodi Gootkin

59

## Tendon Healing

- Tendons receive vascular perfusion directly through vincula and through synovial sheath diffusion.
- Two pathways contribute to healing that progress is through inflammatory, fibroblastic, and remodeling phases.



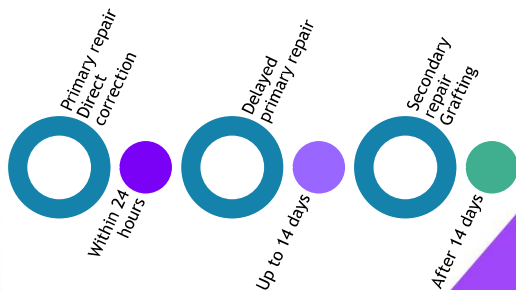
60

Copyright Jodi Gootkin

60

## Flexor Tendon Repair

- ▶ The zone of injury and timing of the repair influence rehabilitation outcomes.



Copyright Jodi Gootkin

61

## Flexor Tendon Primary Repair

Retrieve proximal and distal tendon ends

Core suture to secure proximal stump

Freilich, A. M., & Chhabra, A. B. (2007). Secondary flexor tendon reconstruction, a review. *The Journal of hand surgery*, 32(9), 1436-1442.

Copyright Jodi Gootkin

62

## Suture Techniques

- ▶ Multistrand techniques are suggested to complete the core suturing of the of the tendon ends.
- ▶ The goal is to provide strong gap resistance and fatigue strength.

Griffin, M., Hindocha, S., Jordan, D., Saleh, M., & Khan, W. (2012). An overview of the management of flexor tendon injuries. *The open orthopaedics journal*, 6, 28-35. doi:10.2174/1874325001206010028

Copyright Jodi Gootkin

63

## Secondary Tendon Repair

- ▶ Reconstruction may be necessary when initial surgery is required to manage vascular or bony injuries, delayed presentation, or when primary repair has failed.
- ▶ Autogenous tendon graft
  - ▶ Palmaris longus
  - ▶ Plantaris
  - ▶ Extensor digitorum longus

Copyright Jodi Gootkin

64

## Tendon Repair Splinting

- ▶ Immobilization maintains the repaired musculotendinous unit in a shortened position and prevents forceful contraction.
- ▶ Dorsal blocking splint
  - ▶ Wrist neutral to 40 degrees of flexion
  - ▶ MCP 50 to 70 degrees of flexion
  - ▶ IP extension
- ▶ Kleinert splint
  - ▶ Dorsal extension with rubber band traction
- ▶ Manchester short splint


Khor, W. S., Langer, M. F., Wong, R., Zhou, R., Peck, F., & Wong, J. K. (2016). Improving outcomes in tendon repair: a critical look at the evidence for flexor tendon repair and rehabilitation. *Plastic and reconstructive surgery*, 138(6), 1045e-1058e.

Copyright Jodi Gootkin

65

## Flexor Tendon Repair Rehab

- ▶ Timing of active rehab considers multiple intrinsic and extrinsic factors related to the "work of flexion".



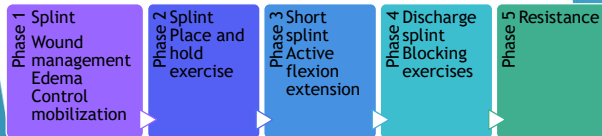
Novak, Christine B, and Rebecca L von der Heyde. "Rehabilitation of the upper extremity following nerve and tendon reconstruction: when and how." *Seminars in plastic surgery* vol. 29,1 (2015): 73-80.

Copyright Jodi Gootkin

66

## Flexor Tendon Rehab

- ▶ Follow the physician protocol.
- ▶ Initially no passive wrist extension or finger extension, active flexion of involved tendons.
- ▶ Tendon gliding of uninvolved fingers may be permitted.



67

Copyright Jodi Gootkin

67

## Controlled Mobilization

- ▶ Following specific active mobility protocols improves tendon healing biology, limits restrictive adhesions, and leads to increased tendon excursion.

- ▶ Duran
  - ▶ Passive finger flexion
- ▶ Kleinert
  - ▶ Passive flexion and active extension
- ▶ Early Active Motion (EAM)
  - ▶ Active flexion

Jha, B., Ross, M., & Peters, S. E. (2017). Rehabilitation following surgery for flexor tendon injuries of the hand. *The Cochrane database of systematic reviews*, 2017(1).  
Yousef, J., & Anthony, S. (2018). *Flexor Tendon Injuries. Essentials of Hand Surgery*, 21.

68

Copyright Jodi Gootkin

68

## Complications

- ▶ Bowstringing
- ▶ Tendon adhesions
  - ▶ Tenolysis may be necessary
- ▶ Rupture
  - ▶ Edema and ROM considerations
- ▶ Quadriga
- ▶ Lumbrical plus finger
- ▶ Joint contracture

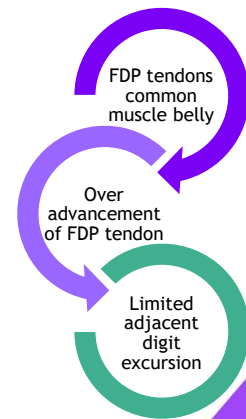
69

Copyright Jodi Gootkin

69

## Quadriga

- ▶ Inability to fully actively flex the finger adjacent to a finger with a previous FDP injury.

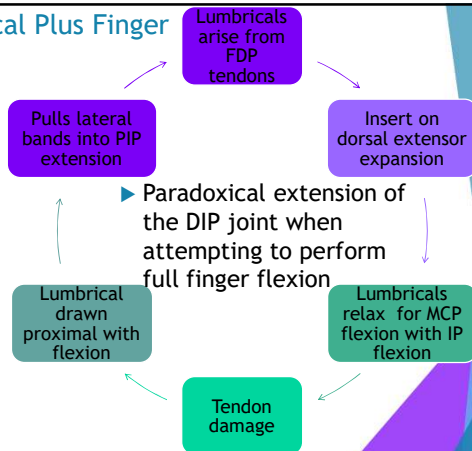


70

Copyright Jodi Gootkin

70

## Lumbrical Plus Finger



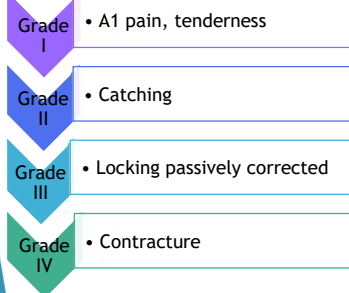
71

Copyright Jodi Gootkin

71

## Trigger Finger or Trigger Thumb

- ▶ Patients present with mechanical impingement "catching" of the finger locking in flexion.



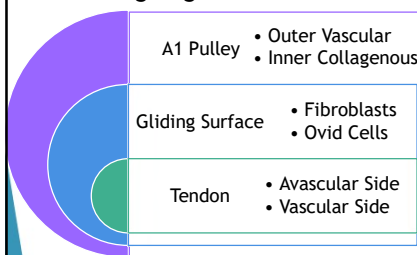
72

Copyright Jodi Gootkin

72

## Finger Flexor Pulley System

- ▶ Fibrocartilagenous metaplasia of the A1 ligamentous pulley and stenosing tenosynovitis of the ring finger and thumb at the MCP joint.



Copyright Jodi Gootkin 73

73

## Trigger Finger or Thumb Release

- ▶ Through open or percutaneous technique the A1 pulley and tendon sheath at the MCP joint is freed of fibrotic restrictions allowing the swollen tendon to glide more easily.
- ▶ Active motion confirms release with modifications possible before incision closure.
- ▶ With ROM and strengthening caution with
  - ▶ Composite wrist/finger extension
  - ▶ Repetitive gripping

Copyright Jodi Gootkin 74

74

## De Quervain's Release

- ▶ Stenosing tenosynovitis of the abductor pollicis longus (APL) and extensor pollicis brevis (EPB) from repetitive thumb motions or grasping with ulnar deviation results in radial sided wrist pain.
- ▶ The presence of a septum between the tendons and multiple slips of the APL may contribute to fibrosis.
- ▶ Endoscopic or open procedure to release the first dorsal compartment retinaculum.

Copyright Jodi Gootkin 75

75

## De Quervain's Release Rehab

- ▶ The radial nerve superficial sensory branch can become inflamed or damaged during decompression surgery.
- ▶ Thumb spica splinting protects the surgical site.

Copyright Jodi Gootkin 76

76

## Dupuytren's Contracture

- ▶ Patients with a genetic predisposition develop progressive palmar fibromatosis leading to contracture of the ring and pinky finger MCP joints.

Copyright Jodi Gootkin 77

77

## Dupuytren's Surgical Procedures

Enzymatic Fasciotomy

Needle Aponeurotomy

Fasciectomy

- ▶ Recurrence defined as "more than 20 degrees of contracture recurrence in any treated joint at one year post-treatment compared to six weeks post-treatment."

Kan, H. J., Verrijp, F. W., Hovius, S., van Nieuwenhoven, C. A., Dupuytren Delight Group, B. Selles, R. W. (2017). Recurrence of Dupuytren's contracture: A consensus-based definition. *PLoS one*, 12(5), e0164849.

Copyright Jodi Gootkin 78

78



## Enzymatic Fasciotomy

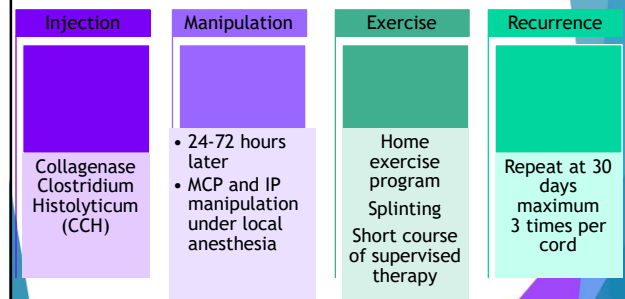
- ▶ Xiaflex® is a purified microbial Collagenase Clostridium Histolyticum (CCH) that disrupts the Type I and III collagen bonds in the cords.
- ▶ Indications
  - ▶ 20\*-100\* MCP contracture
  - ▶ 20\*-80\* PIP contracture
  - ▶ 2 affected joints in the same hand

Xiaflex® <https://dupuytren-contraction.xiaflex.com/hcp/about-xiaflex/#stepThree>

Copyright Jodi Gootkin

79

## CCH Post-Injection Protocol



Xiaflex® Training Guide: <https://dupuytren-contraction.xiaflex.com/public/pdf/xiaflex-dc-managed-distribution-training-guide.pdf>  
<https://dupuytren-contraction.xiaflex.com/patient/about-xiaflex/receiving-xiaflex/>

Copyright Jodi Gootkin

80

## CCH Injection Side Effects

- ▶ Monitor patient for signs of infection, nerve injury or allergic reaction.
- ▶ Some patients may experience skin tears that require bandaging.

81

Copyright Jodi Gootkin

81

## Needle Aponeurotomy (NA)

- ▶ Through multiple small puncture sites, a needle divides the contracted cords and septal paths between palmar aponeurosis and dermis.
- ▶ Active range of motion can begin the day of surgery.
- ▶ Custom nighttime splint worn at night for several months may improve outcomes.
- ▶ Avoid strenuous gripping for 1 week

Consider This

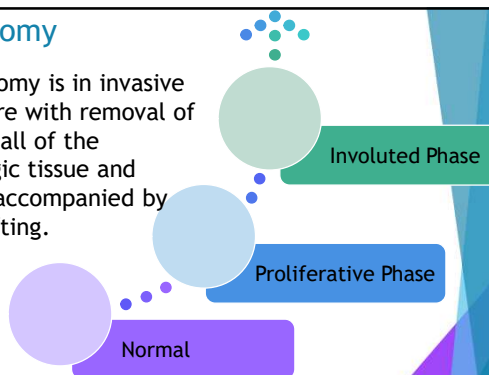
82

Copyright Jodi Gootkin

82

## Fasciectomy

- ▶ Fasciectomy is an invasive procedure with removal of some or all of the pathologic tissue and may be accompanied by skin grafting.



83

Copyright Jodi Gootkin

83

## Post Operative Fasciectomy

- ▶ Post operatively a soft dressing and splint is applied to maintain the finger in extension.
- ▶ When ROM begins avoid composite extension.
- ▶ Monitor patient for infection, neurapraxia, CRPS.

84

Copyright Jodi Gootkin

84

## Dupuytren's Outcomes

Procedure	Variables	Outcome
Collagenase Injection	Primary MCP and IP ROM reached 49% at <1yr and 58% at >1yr	Short and medium term satisfactory response. Long term uncertain.
Needle Fasciotomy	50-58% recurrence 9-25% complication	Similar complication to injection
Fasciectomy	12-39% recurrence 14-67% complication	More complications than needle but less recurrence

Sanjuan-Cerveró, R., Vazquez-Ferreiro, P., Gomez-Herrero, D., & Carrera-Huaso, F. J. (2017). Efficacy of collagenase clostridium histolyticum for dupuytren disease: a systematic review. *Revista Iberoamericana de Cirugía de la Mano*, 45(02), 070-088.  
Chen, N. C., Srinivasan, R. C., Shauver, M. J., & Chung, K. C. (2011). A systematic review of outcomes of fasciotomy, aponeurotomy, and collagenase treatments for Dupuytren's contracture. *Hand*, 6(3), 250-255.

Copyright Jodi Gootkin

85

## Rehabilitation Considerations Nerve, Fascia and Tendon Surgery

- ▶ Initial Post-op
  - ▶ Splinting
  - ▶ Wound healing
  - ▶ Edema management
  - ▶ Joint protection
  - ▶ Pain management
  - ▶ Home exercise
- ▶ Later Rehab
  - ▶ Wean splinting
  - ▶ Scar mobility
  - ▶ Protected ROM
  - ▶ Progressive strengthening
  - ▶ Functional retraining

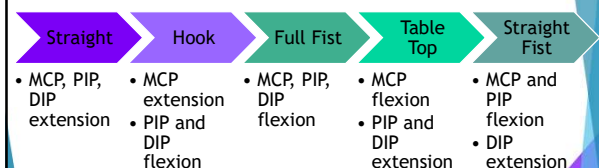
PROTOCOL

Copyright Jodi Gootkin

86

## Tendon Gliding Exercise

- ▶ Designed to maintain free gliding between the tendons of the flexor digitorum profundus (FDP) and flexor digitorum superficialis (FDS).



Consider This

Webb, M. A. (1987). Tendon gliding exercises. *American Journal of Occupational Therapy*, 41(3), 164-167. Copyright Jodi Gootkin

87

## Post Operative Complications

- ▶ Following wrist and hand surgery, patients must be monitored for digital thrombosis that can lead to ischemia.
  - ▶ Rule out Thoracic Outlet Syndrome, Raynaud's Disease, or excessive external compression
  - ▶ Skin inspection - color and epidermolysis
  - ▶ Assess capillary refill

Copyright Jodi Gootkin

88

## Wrist and Hand Joint Reconstruction

- ▶ Conservative treatment failure for osteoarthritis is defined as
  - ▶ 'not sufficiently effective in relieving pain'
- ▶ Unlike large joint replacement, hand surgery for osteoarthritis is focused on pain relief as opposed to functional improvement.

Kloppenborg, M., Kroon, F. P., Blanco, F. J., Doherty, M., Dziedzic, K. S., Greibrokk, E., ... & Maheu, E. (2019). 2018 update of the EULAR recommendations for the management of hand osteoarthritis. *Annals of the Rheumatic Diseases*, 78(1), 16-24.

Copyright Jodi Gootkin

89

## Basal Joint Arthritis

- ▶ The thumb carpometacarpal (CMC) joint possesses little stability from skeletal architecture relying on ligaments and muscles to allow the motion necessary for forceful grasp and fine pinch.
- ▶ Deterioration of the ligaments allow metacarpal translation on the trapezium with shear stress forces leading to cartilage degeneration.
- ▶ Trapeziectomy is the most common initial surgical intervention.

Consider This

Judd, A. L., Wells, A. P., Crisco, J. J., Hagert, E., Wolf, J. M., Glickel, S. Z., & Yao, J. (2013). The thumb carpometacarpal joint: anatomy, biomechanics, and biomechanics. *Instructional course lectures*, 62, 165-179.

Copyright Jodi Gootkin

90

## Trapeziectomy with Ligament Reconstruction And Tendon Interposition (LRTI)

- ▶ Removal of the trapezium.
- ▶ Flexor carpi radialis (FCR) insertion relocated to first metacarpal.
- ▶ Portion of tendon utilized to reconstruct anterior oblique ligament.
- ▶ Remaining “anchovy” is placed in space from excised trapezium.

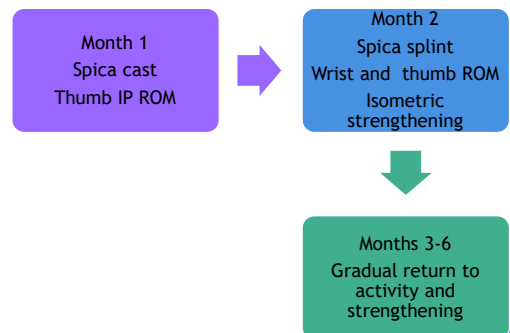
Wajon, A., Vinycomb, T., Carr, E., Edmunds, I., & Ada, L. (2015). Surgery for thumb (trapeziometacarpal joint) osteoarthritis. *Cochrane database of systematic reviews*, (2).

91

Copyright Jodi Gootkin

91

## Trapeziectomy Rehab



92

Copyright Jodi Gootkin

92

## Distal Radius Fracture

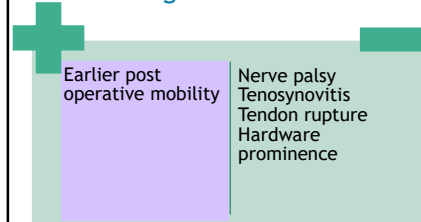
- ▶ Low energy trauma in older individuals or high force impact in younger individuals can lead to distal radius fracture.
- ▶ Physicians attempt to achieve an anatomic reduction in stabilizing fracture segments.
  - ▶ Inclination
  - ▶ Dorsal tilt
  - ▶ Radial length

93

Copyright Jodi Gootkin

93

## Volar Locking Plate



Saving, J., Enocson, A., Ponzer, S., & Navarro, C. M. (2019). External Fixation Versus Volar Locking Plate for Unstable Dorsally Displaced Distal Radius Fractures—A 3-Year Follow-Up of a Randomized Controlled Study. *The Journal of hand surgery*, 44(1), 16-23.

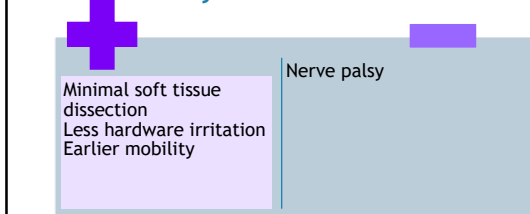
Calbryk, M., & Ipek, D. (2018). Use of Volar Locking Plate Versus Intramedullary Nailing for Fixation of Distal Radius Fractures: A Retrospective Analysis of Clinical and Radiographic Outcomes. *Medical science monitor : International medical journal of experimental and clinical research*, 24, 602-613. doi:10.12659/msm.908762

Consider This

Copyright Jodi Gootkin

94

## Intramedullary Nail



Calbryk, M., & Ipek, D. (2018). Use of Volar Locking Plate Versus Intramedullary Nailing for Fixation of Distal Radius Fractures: A Retrospective Analysis of Clinical and Radiographic Outcomes. *Medical science monitor : International medical journal of experimental and clinical research*, 24, 602-613. doi:10.12659/msm.908762

Jordan, R. W., & Sathna, A. (2015). Defining the role of intramedullary nailing for fractures of the distal radius: a systematic review. *The bone & joint journal*, 97(10), 1370-1376.

Consider This

95

Copyright Jodi Gootkin

95

## External Fixation

- ▶ Potential complications include
  - ▶ Nerve palsy
  - ▶ Pin infection
  - ▶ Loss of fracture reduction

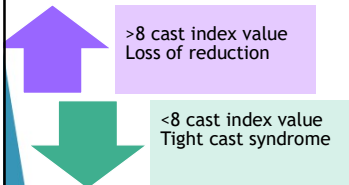
Saving, J., Enocson, A., Ponzer, S., & Navarro, C. M. (2019). External Fixation Versus Volar Locking Plate for Unstable Dorsally Displaced Distal Radius Fractures—A 3-Year Follow-Up of a Randomized Controlled Study. *The Journal of hand surgery*, 44(1), 16-23.

Copyright Jodi Gootkin

96

## Tight Cast Syndrome

- ▶ Closed reduction with casting is the prevailing method of management for distal radius fractures in pediatric cases.
- ▶ A poorly applied cast can result in swelling, pain, and potential progression to compartment syndrome and Volkmann's contracture.



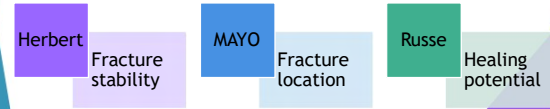
Turgut, A., Erkuş, S., Koca, A., Payzner, L., Çiçek, A. O., & Kalandaner, Ö. (2018). Analysis of the factors causing tight cast syndrome after closed reduction and casting of pediatric distal radius fractures. *Acta orthopaedica et traumatologica turcica*, 52(5), 329-333.

Copyright Jodi Gootkin

97

## Scaphoid Fracture

- ▶ Healing is complicated by the tenuous blood supply of the scaphoid bone with proximal pole fractures at risk for delayed union, nonunion, avascular necrosis.



Copyright Jodi Gootkin

98

## Scaphoid Fracture Stabilization

- ▶ ORIF or percutaneous pins or headless screws are placed.
- ▶ Bone grafting may be incorporated to bridge the fracture defect.
- ▶ Dorsal approach may allow for more accurate placement but may risk injury to extensor pollicis longus, extensor indicis, and extensor digitorum to the index finger.

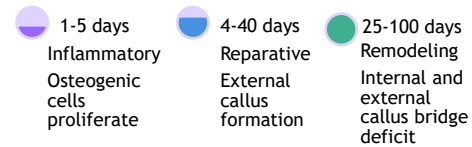
Copyright Jodi Gootkin

99

99

## Fracture Healing

- ▶ Scaphoid fracture healing occurs at a slower rate than other sites in the body.

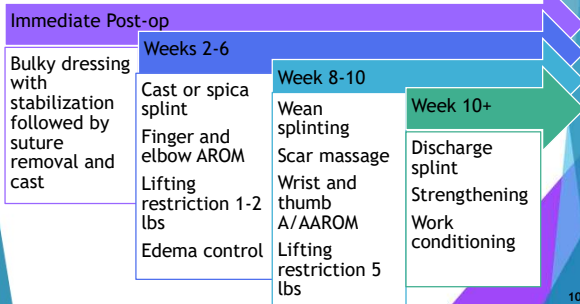


Copyright Jodi Gootkin

100

## Scaphoid Fracture Rehab

- ▶ To diminish the risk of non-union, rehabilitation progressive slowly minimizing activities with vibration exposure and fall risk.



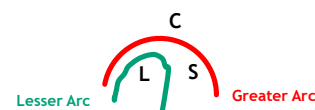
Copyright Jodi Gootkin

101

101

## Perilunate Fracture Dislocations

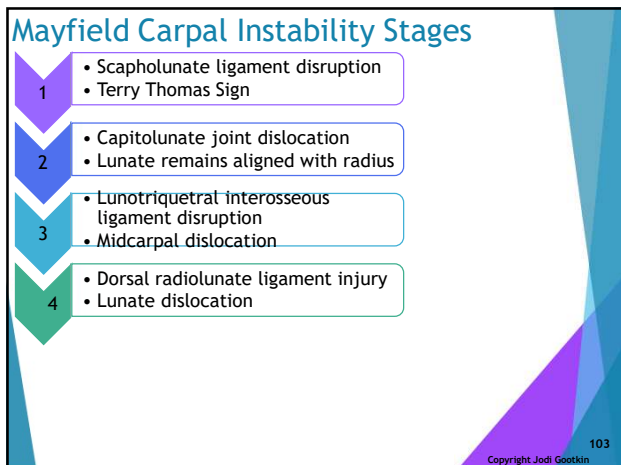
- ▶ Alignment of the lunate is critical for correct geometry of the carpal arcs necessary for hand function and stability.
- ▶ FOOSH injuries in extreme pronation and ulnar deviation hyperextended wrist results in combined fractures and dislocations of carpal.



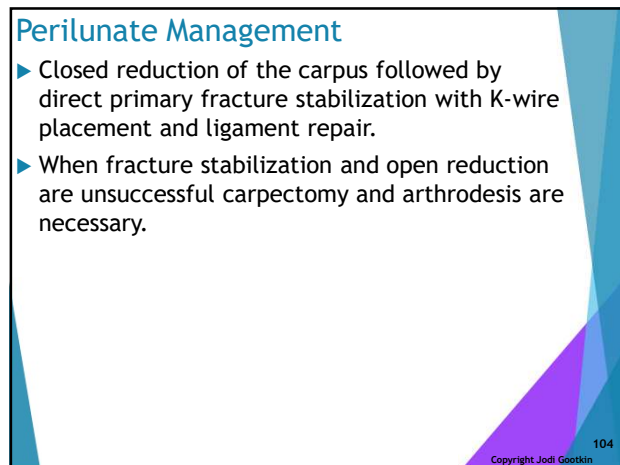
Copyright Jodi Gootkin

102

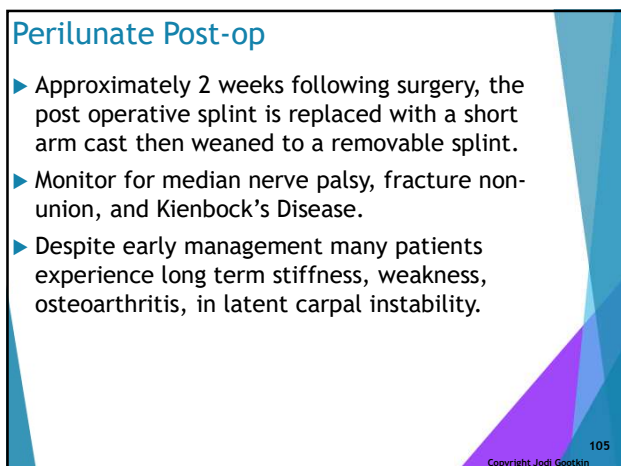
102



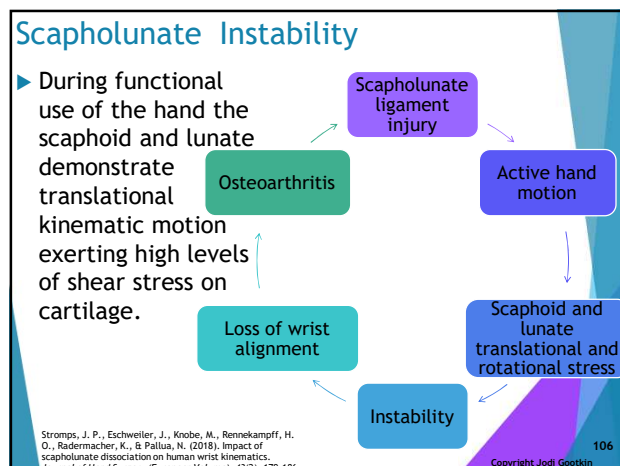
103



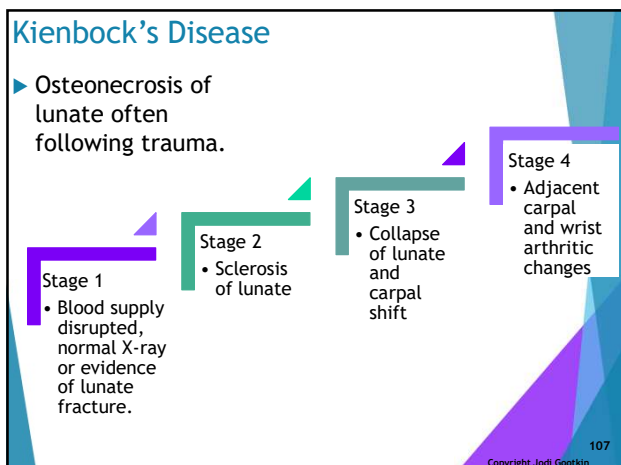
104



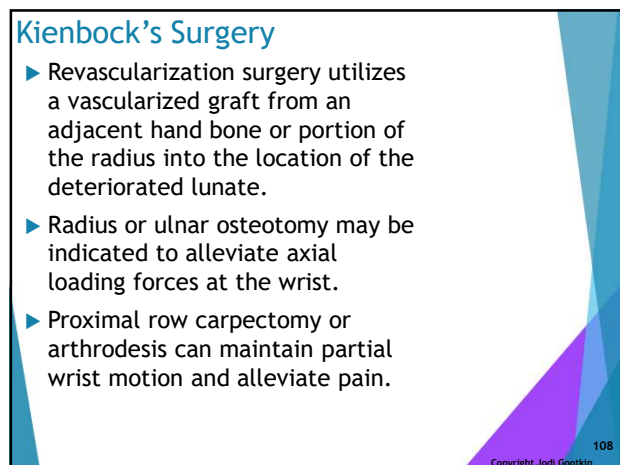
105



106



107



108

## Casts and Splints

- ▶ Casts may be utilized to rigidly stabilize surgical repair sites.
- ▶ Splints utilized for post operative stabilization allow some expandability to accommodate swelling and visualization of the wound.
- ▶ Splints wearing schedule can be modified protect the wrist and hand as the patient regains functional use of the hand.

109

Copyright Jodi Gootkin

109

## Thumb Spica Splint

- ▶ Extends from just distal to the IP joint of the thumb to the mid forearm.
  - ▶ Forearm neutral and wrist extended or neutral with thumb wineglass position and slight MCP and IP flexion.

110

Copyright Jodi Gootkin

110

## Volar Splint

- ▶ Volar splint begins in the palm at the MCP joints and extends to the forearm proximal to the elbow.
  - ▶ Forearm and wrist in neutral or slight extension.

111

Copyright Jodi Gootkin

111

## Ulnar and Radial Gutter Splints

- ▶ Ulnar gutter the runs from the DIP or MCP of the pinky and ring finger along the ulnar aspect up to the mid-forearm.
- ▶ Radial gutter the runs from DIP or MCP of the index and middle finger along the radial aspect to mid-forearm.
- ▶ For both forearm neutral with slight wrist extension, MCP 50° flexion, PIP and DIP slight flexion.

112

Copyright Jodi Gootkin

112

## Sugar Tong Splint

- ▶ A U-shaped splint that runs from the dorsal aspect of the knuckles, around the elbow, along the volar forearm stopping at the MCP joints.
  - ▶ Elbow flexion at 90 degrees, forearm neutral and wrist neutral or slight extension.

113

Copyright Jodi Gootkin

113

## Adaptive Equipment

- ▶ Utilization of equipment to perform functional and work tasks can minimize unnecessary stress on joints and decrease musculoskeletal demands to execute the task.

### External Pressure

Odd shaped objects  
Slippery surfaces  
Tightly fit objects  
Small handles/objects  
Cold objects

### Internal Pressure

Extremes of range of motion  
Excessive grip pressure  
Sustained positions

114

Copyright Jodi Gootkin

114



- Longer lever arm**
  - Decreases muscle power and torque requirements
- Larger surface area**
  - Use palm and proximal upper extremity force
- Increase circumference**
  - Allows use of larger joints and decrease force requirement
- Use alternative joints**
  - Eliminate workload on hands
- Add stability and decrease friction**
  - Reduced muscle power and endurance requirement

Copyright Jodi Gootkin 115

115

### Smoking and Healing

- Increased infection rates are noted in smokers following closed and open hand fractures.
- Electronic cigarettes have been shown to decrease hand microvascular circulation.

Pywell, M. J., Wordsworth, M., Kwasnicki, R. M., Chadha, P., Hettiaratchy, S., & Halsey, T. (2018). The effect of electronic cigarettes on hand microcirculation. *The Journal of hand surgery*, 43(5), 432-438.

Mishra, S. V., & Catalano III, L. W. (2019). Comparison of open and closed hand fractures and the effect of urgent operative intervention. *The Journal of hand surgery*, 44(1), 65-e1.

Copyright Jodi Gootkin 116

116

### Conclusion

- Research continues to explore innovative surgical techniques to restore hand kinematics and muscle function following injury.
- Understanding the complex hand anatomy will allow clinicians to understand physician protocols and apply rehabilitation techniques to restore functional hands use.

Copyright Jodi Gootkin 117

117

- Which of the following changes resulting during hand surgical interventions does NOT impact biomechanics?
  - Altered hand geometry
  - Restoration of vascular supply
  - Shifted muscle-tendon paths
  - Joint congruency changes

Copyright Jodi Gootkin 118

118

- How is WALANT surgery different than traditional surgery?
  - Higher cost
  - Surgical time is longer
  - No tourniquet is utilized
  - Warm arm compresses are applied

Copyright Jodi Gootkin 119

119

- What surgical procedure relocates donor nerves to a target muscle or skin region to restore innervation?
  - Transfer
  - Decompression
  - Grafting
  - Repair

Copyright Jodi Gootkin 120

120

4. Which of the following is NOT one of the “6P’s” when monitoring for a Compartment Syndrome?

- A. Poikilothermia
- B. Paresthesia
- C. Pallor
- D. Pressure

121

Copyright Jodi Gootkin

121

5. Zone I Flexor Tendon Repairs are performed on injuries located \_\_\_\_\_.

- A. Near the tip of the finger
- B. Close to the metacarpal phalangeal joint
- C. In the palm
- D. Near the wrist crease

122

Copyright Jodi Gootkin

122

6. Needle Aponeurotomy (microscopic punctures in the palmar fascia) is used to treat which condition?

- A. Carpal Tunnel Syndrome
- B. Dupuytren’s Contracture
- C. Scaphoid Necrosis
- D. Trigger Finger

123

Copyright Jodi Gootkin

123

7. Which of the following is NOT a position used in tendon gliding exercises?

- A. Table Top
- B. Hook
- C. Opposition
- D. Straight Fist

124

Copyright Jodi Gootkin

124

8. Trapeziectomy is performed on what joint?

- A. Thumb Carpometacarpal
- B. Scapholunate
- C. Distal Radioulnar
- D. Interphalangeal

125

Copyright Jodi Gootkin

125

9. A volar locking plate is utilized during open reduction internal fixation to stabilize a fracture of what bone?

- A. Lunate
- B. Radius
- C. Trapezium
- D. Ulna

126

Copyright Jodi Gootkin

126

10. What is the name of the U-shaped splint that runs from the dorsal aspect of the knuckles, around the elbow, along the volar forearm stopping at the MCP joints?
- A. Thumb Spica
  - B. Ulnar Gutter
  - C. Sugar Tong
  - D. Radial Gutter

Copyright Jodi Gootkin

127

127

## Distal Upper Extremity Surgical Management

### References

- Alrayes, M. S., Altawili, M., Alsaffar, M. H., Alfarhan, G. Z., Owedah, R. J., Bodal, I. S., ... & Sindi Sr, A. W. (2024). Surgical interventions for the management of carpal tunnel syndrome: A narrative review. *Cureus*, 16(3).
- Andronic, O., Nagy, L., Burkhard, M. D., Casari, F. A., Karczewski, D., Kriechling, P., ... & Jud, L. (2022). Long-term outcomes of the four-corner fusion of the wrist: A systematic review. *World journal of orthopedics*, 13(1), 112.
- Anene, C. C., Thomas, T. L., Matzon, J. L., & Jones, C. M. (2024). Complications following intramedullary screw fixation for metacarpal fractures: a systematic review. *The Journal of Hand Surgery*, 49(10), 1043-e1.
- Ayhan, E., Tuna, Z., & Oksuz, C. (2021). Getting better results in flexor tendon surgery and therapy. *Plastic and Reconstructive Surgery—Global Open*, 9(2), e3432.
- Boeckstyns, M. E., & Herzberg, G. (2024). Complications after total wrist arthroplasty. *Journal of Hand Surgery (European Volume)*, 49(2), 177-187.
- Bollard, S. M., Kelly, B., McDermott, C., & Potter, S. (2021). The use of point of care ultrasound in hand surgery. *The Journal of Hand Surgery*, 46(7), 602-607.
- d'Ailly, P. N., Mulders, M. A., Bisoendial, R. J., Kuijper, T. M., Coert, J. H., & Schep, N. W. (2022). Arthroscopic synovectomy of the wrist in patients with rheumatoid arthritis: a systematic review of the current literature. *JCR: Journal of Clinical Rheumatology*, 28(2), 77-83.
- Daher, M., Roukoz, S., Chalhoub, R., Ghoul, A., Tarchichi, J., Aoun, M., & Sebaaly, A. (2023). Management of displaced metacarpal shaft fractures: a systematic review and meta-analysis. *JPRAS open*, 38, 163-172.
- de Roo, S. F., Sprangers, P. N., Walbeehm, E. T., & van der Heijden, B. (2021). Systematic review and meta-analysis of surgical options for recurrent or persistent carpal tunnel syndrome: simple decompression versus coverage of the median nerve. *Journal of Hand Surgery (European Volume)*, 46(7), 749-753.
- Eschweiler, J., Li, J., Quack, V., Rath, B., Baroncini, A., Hildebrand, F., & Migliorini, F. (2022). Total Wrist Arthroplasty—A Systematic Review of the Outcome, and an Introduction of FreeMove—An Approach to Improve TWA. *Life*, 12(3), 411.
- Fuller, J. B., Piscoya, A. S., Clark, D. M., Markose, K., & Dunn, J. C. (2022). Surgical management of ulnar metacarpal base fracture-dislocations: a systematic review. *Hand*, 17(3), 405-411.
- Guidi, M., Luchetti, R., Besmens, I., Rothenfluh, E., & Calcagni, M. (2021). Wrist arthrolysis: a systematic review of open and arthroscopic techniques. *Journal of Wrist Surgery*, 10(06), 543-550.
- Hammert, W. C., Chung, K. C., & Miller, L. E. (2024). Best-evidence systematic review and meta-analysis of mini-open carpal tunnel release. *Journal of Hand Surgery Global Online*, 6(1), 35-42.
- Hidayati, H. B., Subadi, I., Fidiana, F., & Puspamanian, V. A. (2022). Current diagnosis and management of carpal tunnel syndrome: A review. *Anaesthesia, Pain & Intensive Care*, 26(3), 394-404.
- Jansen, M. C., Duraku, L. S., Hundepool, C. A., Power, D. M., Rajaratnam, V., Selles, R. W., & Zuidam, J. M. (2022). Management of recurrent carpal tunnel syndrome: systematic review and meta-analysis. *The Journal of hand surgery*, 47(4), 388-e1.
- Liu, E. H., Suen, K., Tham, S. K., & Ek, E. T. (2021). Surgical repair of triangular fibrocartilage complex tears: a systematic review. *Journal of Wrist Surgery*, 10(01), 070-083.

- Meyers, A., Annunziata, M. J., Rampazzo, A., & Gharb, B. B. (2023). A systematic review of the outcomes of carpal ligament release in severe carpal tunnel syndrome. *The Journal of Hand Surgery*, 48(4), 408-e1.
- Nann, S., Kooor, J., Fowler, J., Kieu, J., Gupta, A., Hewitt, J., ... & Maddern, G. (2024). Surgical management of Dupuytren disease: a systematic review and network meta-analyses. *Hand*, 19(8), 1283-1292.
- Owen, D. H., Booth, J. W., Agius, P. A., Perriman, D. M., Smith, P. N., & Roberts, C. J. (2023). Union and complication rates after total wrist arthrodesis: a systematic review and meta-analysis. *The Journal of Hand Surgery*.
- Pace, V., Marzano, F., & Placella, G. (2023). Update on surgical procedures for carpal tunnel syndrome: What is the current evidence and practice? What are the future research directions?. *World Journal of Orthopedics*, 14(1), 6.
- Peters, S. E., Jha, B., & Ross, M. (2021). Rehabilitation following surgery for flexor tendon injuries of the hand. *Cochrane Database of Systematic Reviews*, (1).
- Pripotnev, S., & Mackinnon, S. E. (2022). Revision of carpal tunnel surgery. *Journal of Clinical Medicine*, 11(5), 1386.
- Rodriguez-Merchan, E. C., Tabeayo-Alvarez, E. D., Shojaie, B., & Kachooei, A. R. (2023). Total wrist arthrodesis: an update on indications, technique and outcomes. *Archives of Bone and Joint Surgery*, 11(3), 144.
- Stephens, A. R., Garcia, B. N., Rogers, M. J., Zhang, C., Himbert, C., McFarland, M. M., ... & Tyser, A. R. (2022). Scaphotrapeziotrapezoid arthrodesis: systematic review. *The Journal of Hand Surgery*, 47(3), 218-227.
- Tang, J. B., Lalonde, D., Harhaus, L., Sadek, A. F., Moriya, K., & Pan, Z. J. (2022). Flexor tendon repair: recent changes and current methods. *Journal of Hand Surgery (European Volume)*, 47(1), 31-39.
- Wong, C. R., Huynh, M. N., Fageeh, R., & McRae, M. C. (2022). Outcomes of management of recurrent Dupuytren contracture: a systematic review and meta-analysis. *Hand*, 17(6), 1104-1113.
- Xu, H., Huang, X., Guo, Z., Zhou, H., Jin, H., & Huang, X. (2023). Outcome of surgical repair and rehabilitation of flexor tendon injuries in zone II of the hand: systematic review and meta-analysis. *The Journal of Hand Surgery*, 48(4), 407-e1.
- Zhu, X. M., Perera, E., Gohal, C., Dennis, B., Khan, M., & Alolabi, B. (2021). A systematic review of outcomes of wrist arthrodesis and wrist arthroplasty in patients with rheumatoid arthritis. *Journal of Hand Surgery (European Volume)*, 46(3), 297-303.
- Zijlker, H. J. A., Ritt, M. J. P. F., & Beumer, A. (2022). Fourth-generation total wrist arthroplasty: a systematic review of clinical outcomes. *Journal of wrist surgery*, 11(05), 456-464.