

Shoulder Arthroplasty

Live Interactive Webinar Presented By
 Jodi Gootkin, PT, MEd, CEAS
 jodiemail@comcast.net

1

Copyright Jodi Gootkin 2019

1

Goals and Objectives

1. List and identify all common orthopedic structures of the shoulder girdle.
2. Recognize and define common degenerative and traumatic shoulder pathologies.
3. Define normal and pathologic shoulder arthrokinematics
4. Identify current surgical and non-surgical management strategies for treating shoulder arthropathy
5. Compare and contrast the three most common shoulder arthroplasty surgical procedures.
6. Identify post-surgical complications following shoulder arthroplasty.
7. Compare anatomical and post-arthroplasty shoulder kinematics.
8. Identify the primary goals of post-surgical patient management.
9. Detail factors associated with improved outcomes following total joint replacement.
10. Outline the components of a comprehensive rehabilitation program following shoulder arthroplasty.

4

Copyright Jodi Gootkin 2019

4

Course Overview

- “Shoulder Arthroplasty” is a live (real-time) interactive webinar for rehabilitation professionals that examines surgical management of shoulder pathology through joint arthroplasty. This course includes a review of current literature relating to pathophysiology of shoulder pathology, shoulder arthrokinematics, specific arthroplasty procedures, post-surgical medical management, and anticipated rehabilitation outcomes.

2

Copyright Jodi Gootkin 2019

2

Disclaimer

- Application of concepts presented in this webinar is at the discretion of the individual participant in accordance with federal, state, and professional regulations.

5

Copyright Jodi Gootkin 2019

5

Course Rationale



- The purpose of this course is to provide a comparative analysis of surgical techniques and post-surgical management to understand current prosthetic advances, rehabilitation considerations and maximize outcomes based on current research.

3

Copyright Jodi Gootkin 2019

3

Course Outline and Schedule

Shoulder Anatomy	0:00-0:05
Shoulder Arthrokinematics	0:06-0:10
Shoulder Pathology	0:11-0:15
Traumatic	0:16-0:20
Degenerative	0:21-0:25
Irreparable Rotator Cuff Tear	0:26-0:30
History of Shoulder Replacement Surgery	0:31-0:35
Hemiarthroplasty	0:36-0:40
Anatomic Total Shoulder Arthroplasty	0:41-0:50
Interactive Discussion of Clinical Applications	0:51-1:00
Reverse Shoulder Arthroplasty	1:01-1:10
Surgical Approach	1:11-1:25
Acute Post-Surgical Management	1:26-1:35
Complications	1:36-1:50
Interactive Discussion of Clinical Applications	1:51-2:00
Rehabilitation	2:01-2:05
Arthrokinematics	2:06-2:10
Rehabilitation Phases	2:11-2:25
Functional Outcomes	2:26-2:35
Assessment Tools	2:36-2:45
Prosthetic Survival	2:46-2:50
Interactive Discussion of Clinical Applications	2:51-3:00

6

Copyright Jodi Gootkin 2019

6

Copyright 2020 (c) Innovative Educational Services and Jodi Gootkin.
 All rights reserved. Reproduction, reuse, or republication of all or any part of
 this presentation is strictly prohibited without prior written consent of both
 Innovative Educational Services and Jodi Gootkin.

Convex-Concave Rule

- Normal arthrokinematics of the shoulder follow the convex on concave rule.
- With open chain motions, the convex humeral head moves against the concave glenoid surface with roll and glide occurring in opposite directions.

Motion	Roll	Glide
Abduction	Superior	Inferior
Flexion (Anterior Elevation)	Anterior	Posterior
Internal Rotation	Anterior	Posterior
External Rotation	Posterior	Anterior

Consider This

10
Copyright Jodi Gootkin 2019

10

Shoulder Anatomy

- Functional use of the upper extremity occurs through coordinated movement of the triaxial ball and socket glenohumeral joint with the scapulothoracic, sternoclavicular, and acromioclavicular joints.

8
Copyright Jodi Gootkin 2019

8

Compressive and Shear Forces

The articular surface area of the humeral head is approximately three times greater than that of the glenoid fossa requiring the joint to rely on surrounding soft tissue structures for stability.

Compressive Force + Shear Force → Subluxation Risk Joint Loading

Consider This

11
Copyright Jodi Gootkin 2019

11

Shoulder Musculature

Rotator Cuff: Supraspinatus, Infraspinatus, Teres Minor, Subscapularis "biphasic muscle"

Deltoids

9
Copyright Jodi Gootkin 2019

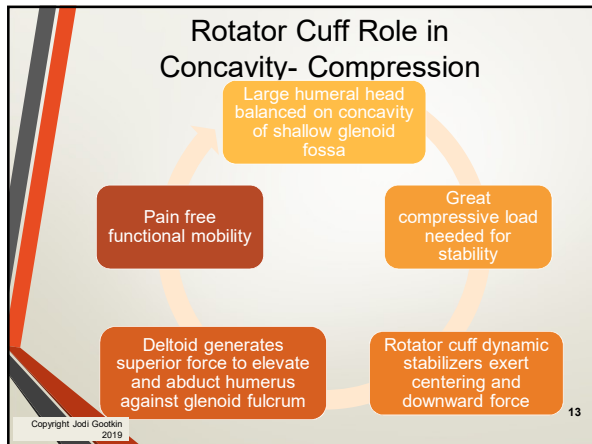
9

Shoulder Arthrokinematics

- The rotator cuff provides inherent joint stability through compression of the humeral head against the glenoid fossa.
- The cuff muscles function as a force couple creating dynamic stabilization so the deltoid can elevate and abduct the shoulder with the glenoid acting as a fulcrum.

12
Copyright Jodi Gootkin 2019

12



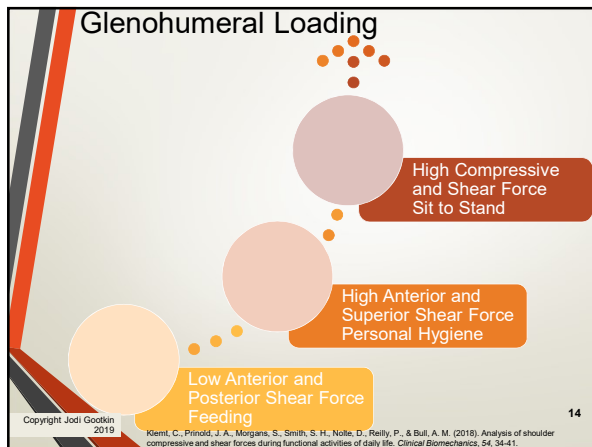
13

Traumatic Shoulder Pathology

- Complications from complex proximal humerus fracture include non-union or displacement of tuberosities and their tendinous insertions.
- In cases at risk for avascular necrosis or where Open Reduction Internal Fixation (ORIF) cannot achieve stable alignment, hemiarthroplasty or arthroplasty may be utilized.

Copyright Jodi Gootkin 2019

16



14

Degenerative Shoulder Pathology Osteoarthritis

- As osteoarthritis progresses significant glenoid bone loss and deterioration of the rotator cuff contribute to additional pain and disability.
- Patients undergoing Total Shoulder Arthroplasty appear to have improved functional and pain scores compared to hemiarthroplasty.
- Reverse Shoulder Arthroplasty may be selected if extensive posterior erosion of the glenoid fossa is present.

Copyright Jodi Gootkin 2019

Soni, S., Bhowmik, M., Blalock, M., Zulfarg, F., Lene, M., Brudner, T., & Raisz, P. (2017). The medium and long-term outcome of total shoulder arthroplasty for primary glenohumeral osteoarthritis in middle-aged patients. *Bone Joint J*, 99(7), 939-943.

Singh, J. A., Spring, J., Buchbinder, R., & McMAKEN, K. E. L. Y. (2011). Surgery for shoulder osteoarthritis: a Cochrane systematic review. *The Journal of Rheumatology*, 38(4), 958-960.

17

Shoulder Pathology

- Common Diagnoses Managed with Shoulder Arthroplasty

Traumatic Shoulder Injuries	Degenerative Shoulder Conditions	Rotator Cuff Arthropathy
<ul style="list-style-type: none"> • Proximal Humerus Fractures • Avascular Necrosis 	<ul style="list-style-type: none"> • Primary Osteoarthritis • Post Traumatic Arthritis 	<ul style="list-style-type: none"> • Irreparable Rotator Cuff Tear

Consider This

Copyright Jodi Gootkin 2019

15

Degenerative Shoulder Pathology Rheumatoid Arthritis

- Several reviews do not support shoulder arthroplasty for patients with rheumatoid arthritis at this time.
- Chronic inflammatory synovitis resulting in poor bone stock, osteopenia, and diminished soft tissue integrity restricts range of motion improvements post operatively.

Copyright Jodi Gootkin 2019

Christie, A., Dagfinrud, H., Ringen, H. O., & Hagen, K. B. (2010). Beneficial and harmful effects of shoulder arthroplasty in patients with rheumatoid arthritis: results from a Cochrane review. *Rheumatology*, 49(3), 509-522.

Christie, A., Dagfinrud, H., Engen, K. M., Flaatten, H. L., Ringen, H. O., & Hagen, K. B. (2010). Surgical interventions for the rheumatoid shoulder: The Cochrane database of systematic reviews. (1). CD006188-CD006188.

18

Copyright 2020 (c) Innovative Educational Services and Jodi Gootkin.
 All rights reserved. Reproduction, reuse, or republication of all or any part of this presentation is strictly prohibited without prior written consent of both Innovative Educational Services and Jodi Gootkin.

Irreparable Rotator Cuff Tear

- Massive rotator cuff tears involve multiple tendons significantly limiting function.
- Anterosuperior tear – subscapularis/supraspinatus
- Posterosuperior tear - supraspinatus/infraspinatus/teres minor

Full thickness rupture of 2 or more tendons or tear dimension > 5 cm

Fatty infiltration of muscles Goutallier stage 3-4

Shoulder pseudoparalysis

19
Copyright Jodi Gootkin 2019

19

Pseudojoint Formation

- Humeral impingement against the acromion leads to degenerative changes referred to as “acetabularization” of the under surface of the acromion and “femoralization” of the humeral head.

22
Copyright Jodi Gootkin 2019

22

Rotator Cuff Arthropathy

- The development of severe shoulder arthritis concurrent with rotator cuff tear is diagnosed in the presence of specific clinical findings:
- Insufficient rotator cuff **Irreparable** = **Massive**
- Glenohumeral osteoarthritis
- Superior migration of humeral head

20
Copyright Jodi Gootkin 2019

20

Radiologic Findings

- Seebauer Classification
 - Type 1 - humeral head and glenoid fossa remain concentric
 - Type 2 - humeral head migrates superiorly
- Hamada Classification

Grade 1	AHI greater than or equal to 6 mm
Grade 2	AHI less than or equal to 5 mm
Grade 3	Grade 2 plus acetabularization of acromion
Grade 4	Grade 3 plus glenohumeral arthritis
Grade 5	Grade 4 plus humeral head collapse

23
Copyright Jodi Gootkin 2019

23

Rotator Cuff Deficiency

- In the absence of the normal concavity compression from a functioning rotator cuff, the humeral head migrates superiorly with deltoid contraction.

21
Copyright Jodi Gootkin 2019

21

Shoulder Pseudoparalysis

Large humeral head balanced on concavity of shallow glenoid fossa

Glenohumeral osteoarthritic changes and painful ROM

Non-functioning rotator cuff

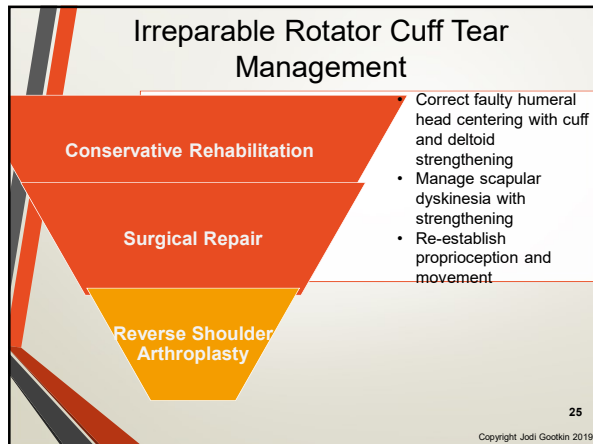
Failure to apply compressive load to humeral head

PSEUDOPARALYSIS
Painless loss of active elevation

Humeral head migrates superiorly with deltoid contraction

24
Copyright Jodi Gootkin 2019

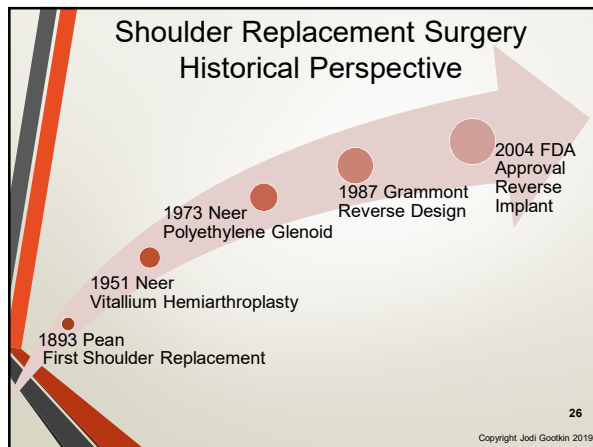
24



25

- ### Shoulder Replacement Surgical Procedures
- Hemiarthroplasty
 - Anatomic Total Shoulder Arthroplasty (TSA)
 - Reverse Shoulder Arthroplasty (RSA)
- 28
Copyright Jodi Gootkin 2019

28



26

- ### Hemiarthroplasty
- Replacement of the humeral head with a prosthetic component.
 - Patient's glenoid fossa typically contains intact cartilage so no glenoid component is utilized.
- Consider This
- 29
Copyright Jodi Gootkin 2019

29

- ### Goal of surgery
- The primary goals of surgery are to relieve pain, provide stability to the joint and restore motion for function.
 - To achieve functional mobility, the surgeon must achieve joint stability, rotator cuff balance, and deltoid force restoration.
- 27
Copyright Jodi Gootkin 2019

27

- ### Hemiarthroplasty Indications
- Severe humeral head and proximal humerus fractures
 - Osteoarthritis when there is a healthy glenoid and intact cartilage
 - Pathologic fracture secondary to neoplasm
 - Rotator Cuff Arthropathy with good shoulder active ROM
- 30
Copyright Jodi Gootkin 2019

30

Copyright 2020 (c) Innovative Educational Services and Jodi Gootkin.
All rights reserved. Reproduction, reuse, or republication of all or any part of this presentation is strictly prohibited without prior written consent of both Innovative Educational Services and Jodi Gootkin.

Cuff Tear Arthroplasty (CTA)

- The prosthetic humeral head has an extended surface to articulate with the deteriorated glenoid fossa and coracoacromial arch.
- The glenoid component is not replaced.

Copyright Jodi Gootkin 2019

31

Anatomic Total Shoulder Arthroplasty Prosthesis

- Metal alloy humeral head with titanium humeral shaft and cross-linked polyethylene glenoid components replace damaged bone surfaces.

Copyright Jodi Gootkin 2019

34

Total Shoulder Arthroplasty Prosthetic Types

- The goal of prosthetic components is to reproduce joint mechanics and restore joint stability and muscle motor function.
- Integrity of rotator cuff is a major factor contributing to the prosthetic selection.

Anatomic Total Shoulder Arthroplasty (TSA)	<ul style="list-style-type: none"> • Neer • Unconstrained Design • Intact rotator cuff required
Reverse Shoulder Arthroplasty (RSA)	<ul style="list-style-type: none"> • Grammont • Constrained design • Deltoid strength required

Copyright Jodi Gootkin 2019

32

Humeral Components

Humeral Implant	Humeral Fixation
<ul style="list-style-type: none"> Stemmed Stemless Short Stem 	<ul style="list-style-type: none"> Cemented Press Fit

Copyright Jodi Gootkin 2019

35

Anatomic Total Shoulder Arthroplasty

- Also known as
 - Anatomic Total Shoulder Arthroplasty ATSA
 - **Total Shoulder Arthroplasty TSA**
 - Neer prosthesis
- Indicated for patients with an intact rotator cuff and
 - Osteoarthritis
 - Rheumatoid Arthritis
 - Post Traumatic Arthritis
 - Avascular Necrosis

Copyright Jodi Gootkin 2019

33

Glenoid Components

Metal Backed	Combination	All polyethylene
<ul style="list-style-type: none"> Uncemented with screws Monoblock platform with central trabecular surface 	<ul style="list-style-type: none"> Metal trabecular surface with peripheral cement 	<ul style="list-style-type: none"> Uncemented fluted deep central peg with cemented peripheral pegs

Copyright Jodi Gootkin 2019

36

Copyright 2020 (c) Innovative Educational Services and Jodi Gootkin. All rights reserved. Reproduction, reuse, or republication of all or any part of this presentation is strictly prohibited without prior written consent of both Innovative Educational Services and Jodi Gootkin.

TSA Unconstrained Prosthesis

- Must have intact rotator cuff as unconstrained design requires stability from native rotator cuff musculature for functional motion of the upper extremity.
- When the rotator cuff is not strong enough to stabilize the humeral head in the glenoid fossa, the deltoid is unopposed and cannot effectively elevate the extremity.

37
Copyright Jodi Gootkin 2019

37

Humeral Component Fixation

Cemented

- Acromial fractures
- Infection
- Nerve injury
- Thromboembolism

Uncemented

- Early humeral stem migration
- Non-progressive radiolucent lines

- Functional outcomes and range of motion equivalent with both uncemented and cemented RSA stems.

Phadnis, J., Huang, T., Watts, A., Krishnan, J., & Bain, G. I. (2016). Cemented or cementless humeral fixation in reverse total shoulder arthroplasty? a systematic review. *The bone & joint journal*, 98(1), 65-74.

40
Copyright Jodi Gootkin 2019

40

Reverse Shoulder Arthroplasty

- Also known as
 - **Reverse Shoulder Arthroplasty RSA**
 - Reverse Total Shoulder Arthroplasty rTSA
 - Reverse Shoulder Replacement RSR
 - Grammont Prosthesis
- Indicated for patients
 - Osteoarthritis WITHOUT an intact rotator cuff
 - Complex proximal humeral fractures
 - Rheumatoid Arthritis
 - Failed Anatomic Total Shoulder Arthroplasty or Hemiarthroplasty

38
Copyright Jodi Gootkin 2019

38

Constrained Design

- The constrained mechanical design of the prosthesis provides joint stability with extremity motion in the absence of a functioning rotator cuff.
- The fixed center of humeral rotation is moved distal and medial in relation to glenoid surface.
 - Converts shear to compressive force

41
Copyright Jodi Gootkin 2019

41

Reverse Shoulder Prosthesis

- Glenohumeral articulation is inverted with the convex prosthesis attached to glenoid fossa and the concave component attached to humerus.
- The glenosphere is attached to a baseplate secured into the fossa by a large central peg and cortical screws.
- The humeral component is a cup shaped body attached to a metal stem that is press fitted or cemented into the humeral medullary canal.
- A polyethylene liner articulates the two components.

Consider This

39
Copyright Jodi Gootkin 2019

39

Fixed Fulcrum

- Creates fixed fulcrum at the glenoid for the humerus to rotate against allowing the deltoid to elevate the arm without impingement.
- Lengthening of the humerus in relation to the scapula enhances the moment arm of the deltoid to perform forward elevation and abduction.
- Prosthetic design allows arm elevation in the absence of a fully functioning rotator cuff.

42
Copyright Jodi Gootkin 2019

42

Copyright 2020 (c) Innovative Educational Services and Jodi Gootkin. All rights reserved. Reproduction, reuse, or republication of all or any part of this presentation is strictly prohibited without prior written consent of both Innovative Educational Services and Jodi Gootkin.

RSA Contraindications

- Axillary nerve damage
- Non-functioning deltoid muscle group
- Infection
- Neuropathic joints
- Inadequate glenoid bone stock

43
Copyright Jodi Gootkin 2019

43

Male vs. Female Shoulder Anatomy

- Surgical alteration of shoulder articular surfaces by 4-5 mm compared to the native joint can significantly impact kinematics of the joint.

Men

- Greater head diameter, glenoid neck length, and greater tuberosity width

Women

- Greater radius of curvature

46
Syed, U. A. M., Davis, D. E., Wei Ko, J., Lee, B. K., Huttman, D. J., et al., & Abboud, J. A. (2017). Quantitative Anatomical Differences in the Shoulder. *Orthopedics*, 40(3), 155-160. Copyright Jodi Gootkin 2019

46

Surgical Considerations

44
Copyright Jodi Gootkin 2019

44

Deltoid Tensioning

- Significant pre-operative deltoid atrophy is associated with diminished functional achievements post surgery.

Over tensioning =
Acromion Fracture

Insufficient
Tension =
Joint Instability

47
Copyright Jodi Gootkin 2019

47

Neck-Shaft Angle

- Alteration of the angle between the humeral head and neck in the prosthetic design influences stability of the joint post operatively.
- Humeral component design creates a neck-shaft angle of 135 degrees.
- Increasing the angle to 155 degrees demonstrates higher instability rates of the new joint.

45
Copyright Jodi Gootkin 2019

45

Component Fixation

- Limited bone stock may present a challenge to achieving fixation of glenoid component.
 - Locking screws with multi-axial designs and hydroxyapatite coatings aid in improving fixation.
- Some surgeons prefer impaction grafting with a humeral press fit component to reduce fracture risk.

48
Copyright Jodi Gootkin 2019

48

Revision Surgery

- Shoulder arthroplasty may fail from loosening, wear, infection, or dislocation requiring revision surgery.

Failed Hemiarthroplasty

- Glenoid Wear
- Intact Rotator Cuff

Total Shoulder Arthroplasty

- Good Results

Failed Hemi or Total Shoulder Arthroplasty

- Rotator Cuff Deficiency
- Glenoid Bone Loss

Reverse Shoulder Arthroplasty

- High Patient Satisfaction
- Increased Complications

49
Copyright Jodi Gootkin 2019

49

- Caution is taken to avoid injury to axillary nerve, musculocutaneous nerve and anterior circumflex vessels.
- The subscapularis must be resected to gain access to glenohumeral joint.

52
Copyright Jodi Gootkin 2019

52

Surgical approach

- The patient is positioned supine on operating table with head elevated 30 – 60 degrees in a “beach chair” position.
- The two primary surgical approaches are Deltopectoral and Anterosuperior

50
Copyright Jodi Gootkin 2019

50

Subscapularis Resection

Inferior Fiber Release	
50% release of lower fibers from lesser tuberosity	Significantly increased load to failure rate compared to 100% peel.
Lesser Tuberosity Osteotomy	
Elevate small fragment of lesser tuberosity	Equivalent or greater function than arthroplasty alone
Subscapularis Peel	
Complete tendon elevation from lesser tuberosity	Equivalent function to lesser tuberosity osteotomy
Mid-substance Tenotomy	
Medial to lesser tuberosity	Rupture risk, decreased functional internal rotation

Mitsche, B. A., & Lajner, P. (2017). Anatomic Shoulder Arthroplasty: Technical Considerations. *The Open Orthopaedic Journal*, 11, 1115-1125.
Simovitch, R. W., Nayak, A., Scalfese, J., Boudreau, R., Omscheid, N., Worhacz, K., ... & Roche, C. (2018). Biomechanical characteristics of subscapularis-sparing approach for anatomic total shoulder arthroplasty. *Journal of Shoulder and Elbow Surgery*, 27(1), 135-140.
Friedman, R. J., Patten, P. H., Wright, T. W., Zuckerman, J. D., & Roche, C. P. (2017). Comparison of reverse total shoulder arthroplasty outcomes with and without subscapularis repair. *Journal of Shoulder and Elbow Surgery*, 26(4), 662-668.

53
Copyright Jodi Gootkin 2019

53

Deltopectoral Approach

- The incision begins slightly medial to acromioclavicular joint and extends distal passing coracoid toward deltoid insertion on lateral humerus.
- Deltoid is elevated with adhesions debrided.

Consider This

51
Copyright Jodi Gootkin 2019

51

Anterosuperior Approach

- Also referred to as the subscapularis sparing approach.
- A vertical incision near posterior margin of acromioclavicular joint descends to split the anterior and middle deltoid.
- The deltoid attachment along clavicle to acromion is released and retracted to expose the joint.

54
Copyright Jodi Gootkin 2019

54

Copyright 2020 (c) Innovative Educational Services and Jodi Gootkin. All rights reserved. Reproduction, reuse, or republication of all or any part of this presentation is strictly prohibited without prior written consent of both Innovative Educational Services and Jodi Gootkin.

Concurrent Procedures

- Release of adhesions under the coracoid and glenohumeral ligament allows mobilization of rotator cuff tendons to reduce the risk of injury.
- Debridement and/or partial or complete rotator cuff repair may improve outcomes in some patients.
- Bone grafting may be utilized for severe glenoid bone loss due to osteoarthritis.

55
Copyright Jodi Gootkin 2019

55

Acute Post Surgical Management

- As future demand increases, management of perioperative factors that influence hospital length of stay can increase discharge disposition to home, improve functional outcomes, and manage health care costs.

Under 55 years old, demand increase 8% per year

Over 55 years, old demand increase 12% per year

2030, younger patients account for 4% of arthroplasties

58
Padegimas, E. M., Matternfort, M., Lazarus, M. D., Ramsey, M. L., Williams, G. R., & Nandori, S. (2015). Future patient demand for shoulder arthroplasty by younger patients: national projections. *Clinical Orthopaedics and Related Research*, 473(6), 1860-1867. Copyright Jodi Gootkin 2019

58

Latissimus Dorsi Tendon Transfer

56
Copyright Jodi Gootkin 2019

56

Patient education

- Preoperative education should focus on pain self-management, activities of daily living training, donning/doffing sling, and mobility in addition to patient expectations of recovery.

59
Copyright Jodi Gootkin 2019

59

Long Head of Biceps Tendon(LHBT) Tenodesis

LHBT tenodesis is indicated in patients with chronic atrophic changes, tendon rupture, and routinely performed by some surgeons in absence of obvious tendonopathy.

Tenodesis is performed with resection of the proximal tendon and resuturing to the insertion of the pectoralis major near the intertubercular groove.

57
Copyright Jodi Gootkin 2019

57

Post Operative Management

60
Copyright Jodi Gootkin 2019

60

Copyright 2020 (c) Innovative Educational Services and Jodi Gootkin. All rights reserved. Reproduction, reuse, or republication of all or any part of this presentation is strictly prohibited without prior written consent of both Innovative Educational Services and Jodi Gootkin.

Surgical Drain

- Some physicians opt to insert a drain prior to closure of the surgical incision to minimize the risk of hematoma formation.
- Typically removed post-operative day 1 when drainage is less than 30mL.

61
Copyright Jodi Gootkin 2019

61

Tobacco Use and Pain Management

- Current tobacco use is associated with a more challenging post-operative course.
 - Higher perceived pain scores
 - Greater narcotic pain medication consumption
 - Slightly longer hospital length of stay

Wells, D. B., Holt, A. M., Smith, R. A., Brolin, T. J., Azar, F. M., & Throckmorton, T. W. (2018). Tobacco use predicts a more difficult episode of care after anatomic total shoulder arthroplasty. *Journal of shoulder and elbow surgery*, 27(1), 23-28.

64
Copyright Jodi Gootkin 2019

64

Pain Management

- Peripheral Nerve Block (PNB)**
 - Intraoperative interscalene or supraclavicular injection
- Patient Controlled Analgesia (PCA)**
 - Patient dispensed at preset dosage
- Intraoperative Injections**
 - Periarticular injection of extended-release liposomal bupivacaine

62
Copyright Jodi Gootkin 2019

62

Breathing Exercises

- In addition to reducing the risk of atelectasis and pneumonia, breathing exercises emphasizing postural alignment can assist in reducing protective muscle spasms.

65
Copyright Jodi Gootkin 2019

65

Interscalene and Supraclavicular PNB Side Effects

- Horner's Syndrome**
 - Myosis
 - Ptosis
 - Anhidrosis
- Bezold-Jarisch Reflex**
 - Bradycardia
 - Hypotension
- Recurrent Laryngeal Nerve Block**
 - Hoarseness
- Diaphragmatic Hemiparesis**
 - Decreased Respiratory Capacity
- Hand Motor Block**
 - Decreased Grip Strength

63
Copyright Jodi Gootkin 2019

63

Complications

- Revision arthroplasty demonstrates greater complication rates compared to primary arthroplasty.

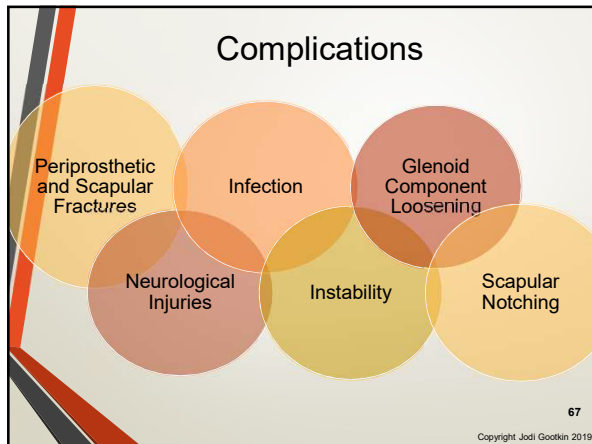
Category	Hemiarthroplasty	Total Shoulder	Reverse Shoulder
PROCEDURES	20	43	37
COMPLICATIONS	17	14	9
READMISSION	7	5	4

Floyd, S. B., Chapman, C. G., Thigpen, C. A., Brooks, J. M., Hawkins, R. J., & Tokish, J. M. (2018). Shoulder arthroplasty in the US Medicare population: a 1-year evaluation of surgical complications, hospital admissions, and revision surgery. *JSES Open Access*, 2(1), 40-47.

66
Copyright Jodi Gootkin

66

Copyright 2020 (c) Innovative Educational Services and Jodi Gootkin.
All rights reserved. Reproduction, reuse, or republication of all or any part of this presentation is strictly prohibited without prior written consent of both Innovative Educational Services and Jodi Gootkin.



67

Infection

- Higher infection rates occur with the RSA potentially due to greater unoccupied joint space post prosthetic implant.
- Common pathogens are Propionobacterium acnes and Staphylococcus.
- Increased incidence of infections in patients with rheumatoid arthritis, diabetes mellitus, history of oral steroid use, shoulder trauma, smoking or failed shoulder hemiarthroplasty.

70
Copyright Jodi Gootkin 2019

70

Periprosthetic Fractures

- Over reaming of a glenoid that has minimal sclerosis can result in fracture and instability of the component fixation.
- Tuberosity and shaft fractures may be accommodated by altering stem length.

68
Copyright Jodi Gootkin 2019

68

Infection Diagnosis

<p>Patient Symptoms</p> <ul style="list-style-type: none"> • Pain • Stiffness • Fever • Night sweats • Chills
<p>Clinical Signs</p> <ul style="list-style-type: none"> • Draining sinus • Erythema • Effusion
<p>Diagnostic Testing</p> <ul style="list-style-type: none"> • Arthrography and culture • Radiographic changes • Serologic markers

71
Copyright Jodi Gootkin 2019

71

Scapular Fractures

- Acromion fractures may occur at the base of the spine of the scapula or through the acromion.
- May result from pre-operative deterioration of the acromion from superior humeral head translation or pseudoparalysis combined with over tensioning of the deltoids during repair.

69
Copyright Jodi Gootkin 2019

69

Neurological Injuries

- Intraoperative nerve injury may result from cement thermal reaction or over penetration of glenoid baseplate screws.
- Lengthening of the upper extremity greater than 2 cm may increase risk of nerve injury.

72
Copyright Jodi Gootkin 2019

72

Neurological Injuries Clinical Presentation

- Post-operative assessment should distinguish sensory changes originating from the healing incision and tissues from neuropraxia.

Nerve	Motor	Sensory
Musculocutaneous	Biceps Brachialis Coracobrachialis	Lateral Forearm
Axillary	Deltoids	Lateral Shoulder
Suprascapular	Supraspinatus Infraspinatus	Posterior Superior Scapula
Radial	Triceps Wrist Extensors	Posterior Distal Arm, Posterior Forearm, Dorsum of Hand Thumb Side

73
Copyright Jodi Gootkin 2019

73

Joint Protection

- No glenohumeral extension beyond neutral

76
Copyright Jodi Gootkin 2019

76

Instability

- Instability can occur with both types of arthroplasty.
- Surgical technique and prosthetic design factors contribute to dislocation risk.

Patient Risk Factors	Surgical Risk Factors
<ul style="list-style-type: none"> BMI > 30 Male Gender Previous Surgery 	<ul style="list-style-type: none"> Inadequate Deltoid Tensioning Malpositioned Implants Mechanical Impingement Subscapularis Deficiency Deltopectoral Approach Axillary Nerve Injury

74
Copyright Jodi Gootkin 2019

74

Post Operative Immobilization

- Immobilization balances optimizing healing of the tendon bone interface with avoiding stiffness.
- Subscapularis protection is critical for healing of the tendon reattachment and to avoid joint subluxation.

77
Copyright Jodi Gootkin 2019

77

Instability

- Conservative management with closed reduction is often successful, but recurrent instability may require revision surgery.

75
Copyright Jodi Gootkin 2019

75

Shoulder Sling

- Patient and family education should emphasize correct donning procedure and alignment to ensure alignment of upper extremity in neutral extension with scapular retraction avoiding excessive cervical stress.
- RSA will use abduction pillow along with sling.

78
Copyright Jodi Gootkin 2019

78

Copyright 2020 (c) Innovative Educational Services and Jodi Gootkin. All rights reserved. Reproduction, reuse, or republication of all or any part of this presentation is strictly prohibited without prior written consent of both Innovative Educational Services and Jodi Gootkin.

Positioning

- In supine add support behind shoulder for humerus to remain neutral aligned with trunk.
 - 10-20 degrees of forward flexion, slight ABDuction and internal rotation
 - Head of bed elevated 30-60 degrees
- In sitting arm supported in sling or on pillow in lap with elbow visible.

79
Copyright Jodi Gootkin 2019

79

Rocking Horse Phenomena

- In the TSA, with shoulder flexion and abduction the point of contact of the humeral head in the glenoid fossa shifts superiorly.
- Without accurate glenoid prosthetic orientation and sufficient rotator cuff strength the glenoid baseplate undergoes eccentric loading.

82
Copyright Jodi Gootkin 2019

82

Mobility Precautions

- Early Rehab
 - Avoid combination of active or passive shoulder internal rotation, ADDuction, extension
 - No pushing, pulling, lifting
- Later Rehab
 - Avoid combination of active shoulder ABDuction above 80 degrees and external rotation

80
Copyright Jodi Gootkin 2019

80

Aseptic Loosening

- Poor implant alignment, rotator cuff dysfunction, and humeral head instability contribute to loosening.

83
Copyright Jodi Gootkin 2019

83

Glenoid Component Loosening

- Loosening of the glenoid component is the most common long term complication associated with TSA as a consequence of the unconstrained design combined with a deficient rotator cuff.
- The shallow glenoid migrates and loosens against the unopposed force of the deltoid contraction.
- Additional contributing factors:
 - Eroded or medialized glenoid
 - Component malposition that increases stress forces
 - Excessive reaming reducing bone stock
 - Underlying infection
 - Rotator cuff tear
 - Instability

81
Copyright Jodi Gootkin 2019

81

Scapular Notching

- Over time following RSA, humeral component impingement causes erosion of the inferior scapular neck.

84
Copyright Jodi Gootkin 2019

84

Copyright 2020 (c) Innovative Educational Services and Jodi Gootkin. All rights reserved. Reproduction, reuse, or republication of all or any part of this presentation is strictly prohibited without prior written consent of both Innovative Educational Services and Jodi Gootkin.

Scapular Notching Implications

Does not impact clinical outcomes and is not prognostic of function.

May lead to baseplate failure and worse clinical outcomes.

Smith, C. D., Guyver, P., & Bunker, T. D. (2012). Indications for reverse shoulder replacement: a systematic review. *The Journal of bone and joint surgery, British volume*, 94(5), 577-583.
Familar, F., Rojas, J., Nedim Doral, M., Huri, G., & McFarland, E. G. (2018). Reverse total shoulder arthroplasty. *EFORT open reviews*, 3(2), 54-60.
Singhal, K., & Ramnathan, R. (2018). Going forward with reverse shoulder arthroplasty. *Journal of Clinical Orthopaedics & Trauma*, 9(5), 27-33.
Favard, L., Lavigne, C., Nerot, C., Gerber, C., De Wilde, L., & Mole, D. (2011). Reverse Prostheses in Arthroplasties With Cuff Tear: Are Survivorship and Function Maintained Over Time? *Clinical Orthopaedics and Related Research*, 469(9), 2469-2479.

Copyright Jodi Gootkin 2019

85

Kinematic Analysis of Motion

- Scapulohumeral rhythm is typically reduced with the overall scapular kinematic pattern preserved.
- The patient may substitute with increased scapular motion to compensate for decreased glenohumeral mobility for the performance of activities of daily living.

Copyright Jodi Gootkin 2019

88

Rehabilitation

Arthrokinematics

Rehab Phases

Functional Progression

Return to Sport and Work

Outcome Assessment

Copyright Jodi Gootkin 2019

86

Range of Motion Expectations

- Full ROM is NOT expected** upon discharge from rehabilitation.
- Upon discharge from therapy most patients achieve approximately 80-120 degrees flexion and 30 degrees external rotation.

Consider This

Smith, C. D., Guyver, P., & Bunker, T. D. (2012). Indications for reverse shoulder replacement: a systematic review. *The Journal of bone and joint surgery, British volume*, 94(5), 577-583.
Favard, L., Lavigne, C., Nerot, C. et al. Reverse prostheses in arthroplasties with cuff tear: Are survivorship and function maintained over time? *Clin Orthop Relat Res* 2011;469:2469-75.
Familar, F., Rojas, J., Nedim Doral, M., Huri, G., & McFarland, E. G. (2018). Reverse total shoulder arthroplasty. *EFORT Open Reviews*, 3(2), 58-69.
Chun YM, Kim DS, Lee DH, Shin SJ. Reverse shoulder arthroplasty for four-part proximal humerus fracture in elderly patients: Can a healed tuberosity improve the functional outcomes? *J Shoulder Elbow Surg* 2017;26:1216-21.
Sanchez-Soleto, J., Nguyen, N. T. V., & Morrey, M. (2018). Anatomic Total Shoulder Arthroplasty Using a Self-Pressurizing Pegged Bone-Preserving Cemented Glenoid Component: A 2-to 5-Year Follow-up Study. *Journal of Shoulder and Elbow Arthroplasty*, 2, 2471549217750478.

Copyright Jodi Gootkin 2019

89

Post Operative Arthrokinematics

- The goal of reconstruction is to replicate normal articular anatomy restoring soft tissue length tension relationships, kinematics, and function.

Copyright Jodi Gootkin 2019

87

ROM Continued

Procedure	Outcomes
Severe fracture	Abduction 90°-100°, poor internal rotation, significant variance in external rotation
Major rotator cuff tear	Elevation improved from 71° to 130°
Irreparable rotator cuff deficiency	Improved anterior elevation from 42° to 100°, abduction 43° to 90°
Acute proximal humerus fractures	Abduction limited to 90°-100° ER/IR varied
Osteoarthritis	Mean 154° elevation, 18° ER, IR to T10

Consider This

Smith, C. D., Guyver, P., & Bunker, T. D. (2012). Indications for reverse shoulder replacement: a systematic review. *The Journal of bone and joint surgery, British volume*, 94(5), 577-583.
Favard, L., Lavigne, C., Nerot, C. et al. Reverse prostheses in arthroplasties with cuff tear: Are survivorship and function maintained over time? *Clin Orthop Relat Res* 2011;469:2469-75.
Familar, F., Rojas, J., Nedim Doral, M., Huri, G., & McFarland, E. G. (2018). Reverse total shoulder arthroplasty. *EFORT Open Reviews*, 3(2), 58-69.
Chun YM, Kim DS, Lee DH, Shin SJ. Reverse shoulder arthroplasty for four-part proximal humerus fracture in elderly patients: Can a healed tuberosity improve the functional outcomes? *J Shoulder Elbow Surg* 2017;26:1216-21.
Sanchez-Soleto, J., Nguyen, N. T. V., & Morrey, M. (2018). Anatomic Total Shoulder Arthroplasty Using a Self-Pressurizing Pegged Bone-Preserving Cemented Glenoid Component: A 2-to 5-Year Follow-up Study. *Journal of Shoulder and Elbow Arthroplasty*, 2, 2471549217750478.

Copyright Jodi Gootkin 2019

90

RSA Strength

Medialization increases deltoid moment arm

+

Distalization increases deltoid resting tone

=

Improved Deltoid mechanical advantage

- Non-anatomic design reduces ability of subscapularis and teres minor (if intact) to perform rotation.
- Latissimus dorsi tendon transfer can improve external rotation strength.

91
Copyright Jodi Gootkin 2019

91

Sample Phases

Phase I: Start Pos-op Day 1	Phase II: Start 4 Weeks	Phase III: Start 6 Weeks	Phase IV: Start 12 Weeks
<ul style="list-style-type: none"> • Allow tissue healing • Maintain new joint integrity • Increase shoulder PROM • Restore elbow/wrist/h and AROM • Reduce pain, inflammation • ADL Modification 	<ul style="list-style-type: none"> • Restore arthrokinematics, muscle balance, and motor control • Restore full PROM • Restore AROM • Control pain, inflammation • Activity Retraining 	<ul style="list-style-type: none"> • Restore shoulder strength, power, and endurance • Optimize neuromuscular control • Return to functional activities with operative extremity 	<ul style="list-style-type: none"> • Maintain AROM • Enhance functional use of operative extremity • Improve shoulder strength, power, and endurance • Progress weight bearing exercises

94
Copyright Jodi Gootkin 2019

94

Rehabilitation Phases

- Progression must be based on clinical findings not timeframes and consider concomitant rotator cuff repair, biceps tenodesis, latissimus dorsi transfer, subscapularis reattachment, and humeral fracture healing.
- **Communication with the physician** regarding the patient's risk factors for complications can assist the clinician in progressing the patient.

92
Copyright Jodi Gootkin 2019

92

Sample Phase 1 Precautions

+

Wear Sling

Ask for help with activities

Always be able to see elbow with positioning

Avoid shoulder AROM

No driving

Avoid sudden movements especially rotation

No combined shoulder internal rotation, extension, and adduction

No lifting, pulling, pushing objects

No supporting of body weight by hand on the operative side

Keep incision clean and dry

95
Copyright Jodi Gootkin 2019

95

Rehabilitation Protocols

Timelines & Interventions Vary Follow the Physician Protocol

RSA Progression is typically slower

93
Copyright Jodi Gootkin 2019

93

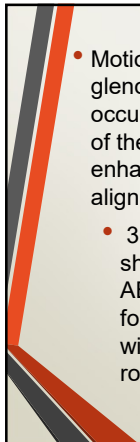
Sample Phase I : Begins POD 1

- Patient education joint protection and positioning
- PROM
 - Forward flexion in supine to tolerance
 - ER in scaption
 - IR to chest
- AROM elbow, hand, wrist, and forearm
- Pendulum exercise
- Scapular setting
- Cryotherapy

96
Copyright Jodi Gootkin 2019

96

Copyright 2020 (c) Innovative Educational Services and Jodi Gootkin.
All rights reserved. Reproduction, reuse, or republication of all or any part of this presentation is strictly prohibited without prior written consent of both Innovative Educational Services and Jodi Gootkin.

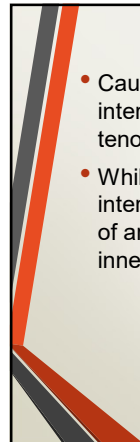


Scaption

- Motion of the glenohumeral joint occurring in the plane of the scapula that enhances shoulder alignment.
- 30 degrees shoulder ABDuction and forward flexion with neutral rotation.

97
Copyright Jodi Gootkin 2019

97

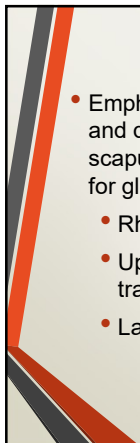


Dynamic Hug

- Caution should be taken when strengthening internal rotation as the subscapularis tenotomy or osteotomy is healing.
- While the entire subscapularis activates with internal rotation, the upper and lower portions of are now recognized as having individual innervations and actions.

100
Copyright Jodi Gootkin 2019

100

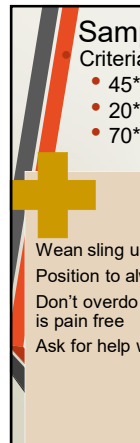


Scapular Strengthening

- Emphasizing alignment and quality motion of the scapula is the foundation for glenohumeral motion.
- Rhomboids
- Upper/middle/lower trapezius
- Latissimus dorsi

98
Copyright Jodi Gootkin 2019

98



Sample Phase II: Begins at 4 Weeks

Criteria for progression: PROM at least

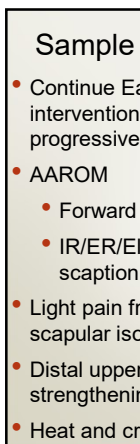
- 45° - 90° Forward flexion and elevation in scaption
- 20° - 45° ER in scaption or at side
- 70° IR in scaption at 30° ABDuction

Precautions

<ul style="list-style-type: none"> • Wean sling use • Position to always see elbow • Don't overdo it now that motion is pain free • Ask for help with activities 	<ul style="list-style-type: none"> • Avoid shoulder AROM against gravity in standing • No pushing up in bed or from a chair • No supporting body weight by hand on operative side • No lifting anything heavier than glass of water • No reaching across or behind your body • No sudden jerking movements
------------------------------------------------------------------------------------------------------------------------------------------------------------------------------------------------------------	------------------------------------------------------------------------------------------------------------------------------------------------------------------------------------------------------------------------------------------------------------------------------------------------------------------------------------------------------------------------

101
Copyright Jodi Gootkin 2019

101




Sample Late Phase I

- Continue Early Phase I interventions with progressive PROM
- AAROM
 - Forward flexion
 - IR/ER/Elevation in scaption
- Light pain free shoulder and scapular isometrics in neutral
- Distal upper extremity strengthening
- Heat and cryotherapy

99
Copyright Jodi Gootkin 2019

99

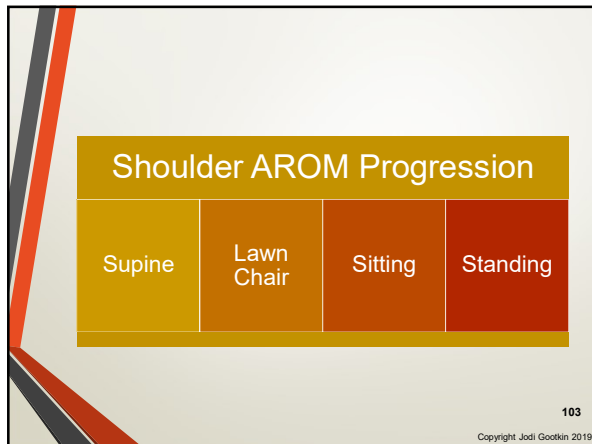


Sample Phase II

- Continue P/AAROM shoulder
- Pain free AROM Flexion, IR/ER/elevation in scaption
- Overhead pulley flexion and elevation in scaption
- Distal upper extremity strengthening with light resistance
- Gentle scapulothoracic mobilizations
- Scapular strengthening
- Submaximal shoulder and scapular isometrics
- Cryotherapy

102
Copyright Jodi Gootkin 2019

102



103

Sample Late Phase III

- Progressive scapular strengthening
- A/AROM shoulder internal rotation behind back and extension
- Supine shoulder flexion with light resistance
- Theraband shoulder flexion and elevation in scaption
 - Check with physician on shoulder extension and internal rotation

106
Copyright Jodi Gootkin 2019

106

Sample Phase III: Begins at 6 Weeks

Criteria for progression: PROM in scaption at least

- 120° -140° Forward flexion and elevation
- 40° -60° ER
- 70° IR at 30 ABDuction
- 100° Active against gravity elevation with good mechanics

Precautions

<ul style="list-style-type: none"> • Wean from sling completely • Utilize operative extremity for light functional tasks 	<ul style="list-style-type: none"> • No heavy lifting objects over 6 pounds • No sudden lifting or pushing activities • No sudden jerking motions
--------------------------------------------------------------------------------------------------------------------------------------------------	------------------------------------------------------------------------------------------------------------------------------------------------------------------------------------

104
Copyright Jodi Gootkin 2019

104

Sample Phase IV: Begins at 12 Weeks

Criteria for progression:

- AROM At least
 - 140° Forward flexion
 - 120° ABDduction
 - 60° ER in scaption
 - 70° IR in scaption at 30 ABD
- 100°- 120° Active against gravity shoulder elevation with good mechanics

Precautions

<ul style="list-style-type: none"> • Gradually progress strengthening 	<ul style="list-style-type: none"> • Avoid functional activities stressing anterior capsule
--------------------------------------------------------------------------------------	------------------------------------------------------------------------------------------------------------

107
Copyright Jodi Gootkin 2019

107

Sample Early Phase III

- Progress shoulder AROM
- Advance PROM to stretching
- Resisted shoulder ER in scapular plane
- Begin endurance training

105
Copyright Jodi Gootkin 2019

105

Sample Phase IV

- End ROM stretching
- Progressive strengthening
- Return to moderately challenging functional activities and recreation

108
Copyright Jodi Gootkin 2019

108

Copyright 2020 (c) Innovative Educational Services and Jodi Gootkin.
All rights reserved. Reproduction, reuse, or republication of all or any part of this presentation is strictly prohibited without prior written consent of both Innovative Educational Services and Jodi Gootkin.

Exercises to Avoid

- Horizontal extension, ABDuction and external rotation combination

109

Copyright Jodi Gootkin 2019

109

Activities of Daily Living (ADLs)

- During early rehab, encourage self care by providing dressing and hygiene instruction and reassurance of performance that protects the healing tissues.
 - One handed donning and doffing of button-up shirt one to two sizes larger than usual size.
 - Seated donning of elastic waist loose bottom pants/shorts using dressing stick.
 - Pop-top toothpaste, pump soap and shampoo dispensers.

112

Copyright Jodi Gootkin 2019

112

Discharge from Therapy

- Maintain non-painful full AROM
- Restored use of upper extremity for advanced functional activities
- Maximized strength, power, and endurance

110

Copyright Jodi Gootkin 2019

110

Hygiene and Toileting

- Washing underarm and torso on surgical side can be performed using Codman's position or by placing hand of operative arm gently in closed chain position on stable counter/sink at 30*-45* degrees of forward flexion or scaption.
- Raised toilet seat, commode over toilet, or grab bar on non-operative side assists with sit to stand.

113

Copyright Jodi Gootkin 2019

113

Functional Outcomes

Follow-up time frame	Procedure	Outcome
5 years	RSA	All Constant scores improved AROM forward elevation and ER improved
3 years	TSA	Able to perform combing hair, washing opposite armpit, tying apron, taking book from shelf using less flexion and abduction compared to controls.
1 year	RSA	

Favard, L., Lavigne, C., Nerot, C., Gerber, C., De Wilde, L., & Mota, D. (2011). Reverse Prostheses in Arthroplasties With Cuff Tear: Are Survivorship and Function Maintained Over Time? *Clinical Orthopaedics and Related Research*, 469(9), 2469-2475.
 Maier, M. W., Nikišić, M., Dreher, T., Ziefang, F., Rattig, O., Klotz, M. C., ... & Kasten, P. (2014). Motion patterns in activities of daily living: 3-year longitudinal follow-up after total shoulder arthroplasty using an optical 3D motion analysis system. *BMC musculoskeletal disorders*, 15(1), 244.
 Maier, M. W., Caspers, M., Ziefang, F., Dreher, T., Klotz, M. C., Wolf, S. I., & Kasten, P. (2014). How does reverse shoulder replacement change the range of motion in activities of daily living in patients with cuff tear arthropathy? A prospective optical 3D motion analysis study. *Archives of orthopaedic and trauma surgery*, 134(8), 1065-1071.

111

Copyright Jodi Gootkin 2019

111

TSA Functional Progression

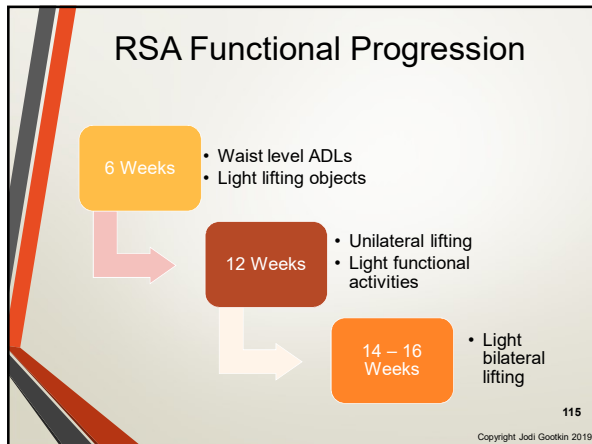
- TSA 2 - 4 Weeks**
 - Waist level ADLs
 - Light lifting objects
 - Driving
- 6 Weeks**
 - Driving
 - Sedentary job
 - Unilateral lifting
 - Light meal prep
- 12 Weeks**
 - Light bilateral lifting, carrying, pushing, pulling
- 6 Months**
 - Heavy Lifting

114

Copyright Jodi Gootkin 2019

114

Copyright 2020 (c) Innovative Educational Services and Jodi Gootkin.
All rights reserved. Reproduction, reuse, or republication of all or any part of this presentation is strictly prohibited without prior written consent of both Innovative Educational Services and Jodi Gootkin.



115

Shoulder Arthroplasty Clinical Outcomes

- Research is supporting similar outcomes can be expected from patients following total and reverse shoulder arthroplasty.
- The majority of the ROM and function gains occur within the first six months.

Sinowich, R., Flurin, P. H., Marczuk, Y., Friedman, R., Weigh, T. W., Zuckerman, J. D., & Roche, C. P. (2015). Rate of improvement in clinical outcomes with anatomic and reverse total shoulder arthroplasty. *Journal of Bone and Joint Surgery*, 99-1901-11

Copyright Jodi Gootkin 2019

118

Return to Sport and Work

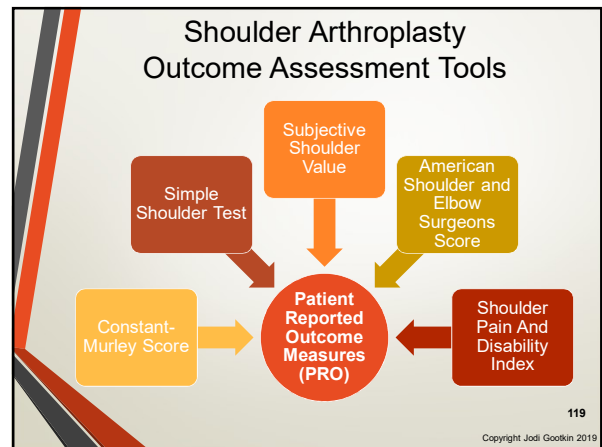
- Total Shoulder Arthroplasty appears to have better outcomes with ability to return to pre-operative recreational sports.

<p>Greater ease with variety of sports and work activities requiring shoulder function.</p> <p>Higher sport and work specific ASES scores</p> <p>Increased frequency of sport participation.</p> <p>Small proportion report persistent restrictions.</p>	<p>TSA</p>	<p>RSA</p> <p>Able to participate in work and low to mid-impact sports.</p> <p>Improved duration and intensity of participation.</p> <p>More restricted guidelines on return to certain sports.</p> <p>Longer recovery period before return permitted.</p>	<p>Consider This</p>
--------------------------------------------------------------------------------------------------------------------------------------------------------------------------------------------------------------------------------------------------------------------------------------	-------------------	-------------------------------------------------------------------------------------------------------------------------------------------------------------------------------------------------------------------------------------------------------------------	-----------------------------

Kurawicki, J., Rosas, S., Law, Y., Levy, J. (2018). Participation in Work and Sport Following Reverse and Total Shoulder Arthroplasty. *Am J Orthop*, May 23, 2018
Johnson, C. C., Johnson, D. J., Liu, J. N., Dines, J. S., Dines, D. M., Galotta, L. V., & Garcia, G. H. (2016). Return to sports after shoulder arthroplasty. *World Journal of Orthopedics*, 7(9), 519.

Copyright Jodi Gootkin 2019

116



119

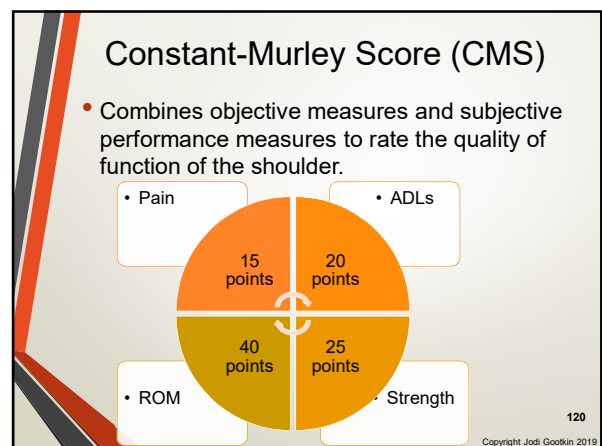
Sample Physician Sport Recommendations

Recommended and Allowed	Allowed with Experience	Not Recommended	No Consensus
Swimming Dancing Bowling Running Bicycling	Golf Ice Skating Downhill Skiing	Hockey Rock climbing Gymnastics Football	Baseball Softball Lacrosse Rowing Soccer Weight Lifting Singles Tennis

Johnson, C. C., Johnson, D. J., Liu, J. N., Dines, J. S., Dines, D. M., Galotta, L. V., & Garcia, G. H. (2016). Return to sports after shoulder arthroplasty. *World Journal of Orthopedics*, 7(9), 519.

Copyright Jodi Gootkin 2019

117



120

Copyright 2020 (c) Innovative Educational Services and Jodi Gootkin.
 All rights reserved. Reproduction, reuse, or republication of all or any part of this presentation is strictly prohibited without prior written consent of both Innovative Educational Services and Jodi Gootkin.

Simple Shoulder Test (SST)

- Reflecting on past week, patient answers yes/no questions regarding shoulder comfort and function.
- Minimal Clinically Important Difference (MCID) for shoulder arthroplasty is 3 points.

Roy, J. S., Macdermid, J. C., Faber, K. J., Drowsowech, D. S., & Athwal, G. S. (2010). The simple shoulder test is responsive in assessing change following shoulder arthroplasty. *Journal Of Orthopaedic & Sports Physical Therapy*, 40(7), 413-421.

121 Copyright Jodi Gootkin 2019

121

Subjective Shoulder Value (SSV)

- This tool is an example of a Single Assessment Numeric Evaluation (SANE).

On a scale of 0% -100% where 0% is abnormal and 100% is normal, how would you rate your shoulder?

Sabesan, V. J., Lombardo, D. J., Khan, J., & Walter, J. M. (2015). Assessment of the optimal shoulder outcome score for reverse shoulder arthroplasty. *Journal of Shoulder and Elbow Surgery*, 24(10), 1653-1659.

124 Copyright Jodi Gootkin 2019

124

American Shoulder and Elbow Surgeons Score (ASES)

Patient Reported

- Pain VAS
- Functional Questions

Physician Assessed

- ROM: Flexion, ER, IR, Horizontal Adduction
- Strength: 0-5 MMT Scale
- Instability: Anterior, inferior, posterior
- Subjective: Tenderness, scarring, atrophy

- Patient rating of pain and function using 0-50 point scale for each.
- MCID 12 -17 point change

Copyright Jodi Gootkin 2019

122

122

Prosthetic Survival

- Implants are surviving at short and midterm follow-up with assessment of long term durability and longevity needed.
- Historical use of shoulder arthroplasty in patients of advanced age with advanced arthritis and irreparable rotator cuff tears limits the research cohort for long term studies as patients often outlive the prosthesis.

Bacle, G., Nové-Josserand, L., Garaud, P., & Walch, G. (2017). Long-term outcomes of reverse total shoulder arthroplasty: a follow-up of a previous study. *JBJS*, 99(6), 454-461.

125 Copyright Jodi Gootkin 2019

125

Shoulder Pain And Disability Index (SPADI)

- Patient ranking on 0 to 10 scale of pain level with specific activities and difficulty with ADLs.
- Pain and Disability scores total to 130 with a score of 0 indicating no disability or pain.

Copyright Jodi Gootkin 2019

123

123

Research Considerations

- Retrospective analysis of patients undergoing shoulder arthroplasty between 1990 and 2015 concludes that more specific study analyzing specific patient data is necessary to determine if outcomes are improving as prosthetic design and surgical technique advances.

Procedure	Studies	Cohort Size	Follow-up
TSA	42 studies	20- 705 patients	3-5 years
RSA	37 studies	20-174 patients	4-5 years

Somerson, J. S., Neradilek, M. B., Hsu, J. E., Gee, A. O., & Matsen, F. A. (2017). Is there evidence that the outcomes of primary anatomic and reverse shoulder arthroplasty are getting better?. *International Orthopaedics*, 41(6), 1235-1244.

126 Copyright Jodi Gootkin 2019

126

Copyright 2020 (c) Innovative Educational Services and Jodi Gootkin. All rights reserved. Reproduction, reuse, or republication of all or any part of this presentation is strictly prohibited without prior written consent of both Innovative Educational Services and Jodi Gootkin.

RSA Long Term Outcomes

Cohort	Outcome
Initial: 186 patients followed 40 months	Midterm: Increased Constant Score and Anterior Elevation
Follow-up: 84 patients followed 150 months	Long term: Overall prosthetic survival 93% 73% scapular notching Greater degradation of function in patients who had surgery prior to age 76

Bade, G., Nové-Josserand, L., Garaud, P., & Walch, G. (2017). Long-term outcomes of 127 reverse total shoulder arthroplasty: a follow-up of a previous study. *JBSJ*, 99(6), 454-461. Copyright Jodi Gootkin 2019

127

Patient Satisfaction

Procedure and Population	Satisfaction
TSA Patients under 50	95% at 5 years
Hemiarthroplasty Patients under 50	71% at 5 years
TSA for Osteoarthritis	Mean 10/10 at 3 years
RSA for Rotator Cuff Arthropaty	90% at 4 years
RSA Workers Compensations Patients	57% at 2 years
RSA Non-workers Compensation Patients	95% at 2 years

Eichinger, Josef & R. Miller, Lindsay & Hartshorn, Timothy & L.L. Xinning & J.P. Warner, Jon & D Higgins, Laurence. (2015). Evaluation of satisfaction and durability after hemiarthroplasty and total shoulder arthroplasty in a cohort of patients aged 50 years or younger: An analysis of discordance of patient satisfaction and implant survival. *Journal of shoulder and elbow surgery*. American Shoulder and Elbow Surgeons. 25, 10.1016/j.jse.2015.09.028.
Petri, M., Euler, S. A., Dornan, G. J., Greenspoon, J. A., Horan, M. P., Kathagen, J. C., & Millet, P. J. (2016). Predictors for satisfaction after anatomic total shoulder arthroplasty for idiopathic glenohumeral osteoarthritis. *Archives of Orthopaedic and Trauma Surgery*, 136(6), 756-762.
Favard, L., Levigne, C., Nivet, C. et al. Reverse prostheses in arthroplasties with cuff tear: Are survivorship and function maintained over time? *Clin Orthop Relat Res* 2011;469:2469-75.
Morris, B. J., Hagler, R. E., Laughlin, M. S., Elkousy, H. A., Gartsman, G. M., & Edwards, T. B. (2015). Workers' compensation claims and outcomes after reverse shoulder arthroplasty. *Journal of Shoulder and Elbow Surgery*, 24(3), 453-459. Copyright Jodi Gootkin 2019

130

Rotator Cuff Tear Outcomes

- Long term high functional outcome scores associated with RSA in young patients with rotator cuff arthropathy.

Population	Outcome
Previous Rotator Cuff Repair	Lower ASES score, higher pain score, less ROM improvement
Younger patients	Excellent clinical improvement, high 12 year survivorship
506 patients	89% survivorship free of revision at 10 years with minimal functional deterioration
Under 60 years old	Significant ROM, pain and strength improvement without deterioration

Shields, E. J., Koueiter, D. M., Maerz, T., Schwark, A., & Wialer, J. M. (2017). Previous Rotator Cuff Repair Is Associated With Inferior Clinical Outcomes After Reverse Total Shoulder Arthroplasty. *Orthopaedic Journal of Sports Medicine*, 5(10), 232596711730311.
Familton, F., Rojas, J., Nadim Dorai, M., Huri, G., & McFarland, E. G. (2018). Reverse total shoulder arthroplasty. *EFORT Open Reviews*, 3(2), 58-69.
Favard, L., Levigne, C., Nivet, C., Gerber, C., De Wilde, L., & Moir, D. (2011). Reverse Prostheses in Arthroplasties With Cuff Tear. *Archives of Orthopaedic and Trauma Surgery*, 131(9), 2469-2475.
Ernsberger, L., Suter, A., Colaninno, S., Rahm, S., & Gerber, C. (2017). Reverse Total Shoulder Arthroplasty for Massive, Irreparable Rotator Cuff Tears Before the Age of 60 Years: Long-Term Results. *JBSJ*, 99(20), 1721-1729. Copyright Jodi Gootkin 2019

128

Future of Shoulder Arthroplasty

- Enhancing design of the reverse shoulder components to restore greater external rotation is expected to improve functional outcomes.
- Monitoring long term implications of scapular notching on prosthetic survival is needed.

131

Post Traumatic Outcomes

Diagnosis	Procedure	Outcome
38 patients with previous ORIF for fracture	RSA	Constant score improved from 25* to 57* Shoulder forward elevation increased from 73* to 117* degrees
23 patients with displaced proximal humeral fracture	ORIF with Plate and screws or RSA	Good clinical outcomes and fewer complications in both. Better ADL results with RSA.
Systematic review of patients with complex proximal humeral fracture	Hemiarthroplasty or RSA	Constant score, ASES score, ROM similar. Greater complications with RSA.


Raisz, P., Alami, G., Brockner, T., Magosch, P., Habermeyer, P., Boileau, P., & Walch, G. (2016). Reverse shoulder arthroplasty for type 1 sequelae of a fracture of the proximal humerus. *Bone Joint J*, 100(3), 318-323.
Giardella, A., Assiome, F., Mocchi, M., Berlusconi, M., Romano, A. M., Oliva, F., & Maradei, L. (2017). Reverse total shoulder versus angular stable plate treatment for proximal humeral fractures in over 65 years old patients. *Muscles, Ligaments and Tendon Journal*, 7(2), 271.
Namdari, S., Horneff, J. G., & Balkwain, K. (2013). Comparison of hemiarthroplasty and reverse arthroplasty for treatment of proximal humeral fracture: a systematic review. *JBSJ*, 95(18), 1701-1709. Copyright Jodi Gootkin 2019

129

Conclusion

Shoulder arthroplasty has proven to improve joint stability, patient comfort and function. Future advances focus on expanding surgical indications and prosthetic design for enhanced clinical outcomes.

132




1. Normal arthrokinematics of the glenohumeral joint follows the _____ rule.

- A. Convex on Concave
- B. Concave on Convex
- C. Superior on Inferior
- D. Inferior on Superior

133
Copyright Jodi Gootkin 2019

133




4. Which anatomical structure is replaced in a shoulder hemiarthroplasty?

- A. Humeral head
- B. Glenoid fossa
- C. Acromial-clavicular joint
- D. Coracoid process

136
Copyright Jodi Gootkin 2019

136




2. The articular surface area of the humeral head is approximately _____ times greater than that of the glenoid fossa.

- A. 2
- B. 3
- C. 4
- D. 5

134
Copyright Jodi Gootkin 2019

134




5. Which of the following is TRUE regarding a reverse shoulder arthroplasty (RSA)?

- A. The glenoid is concave
- B. The humeral head is concave
- C. The deltoid insertion is relocated to the medial humeral shaft
- D. All of the above

137
Copyright Jodi Gootkin 2019

137




3. Which of the following is NOT commonly treated surgically with a shoulder arthroplasty?

- A. Proximal humerus fracture
- B. Severe glenohumeral osteoarthritis
- C. Irreparable rotator cuff tear
- D. Chronic impingement syndrome

135
Copyright Jodi Gootkin 2019

135



6. Which of the following is commonly utilized surgical approach for shoulder arthroplasty?

- A. Latissimus sparing
- B. Posterosuperior
- C. Deltopectoral
- D. Superior Acromial

138
Copyright Jodi Gootkin 2019

138

7. Which muscle typically requires additional protection during the early stages of arthroplasty rehabilitation?

- A. Subscapularis
- B. Deltoid
- C. Supraspinatus
- D. Infraspinatus

139

Copyright Jodi Gootkin 2019

10. Which surgical intervention generally produces superior functional outcomes as it relates to return to sport?

- A. Hemiarthroplasty
- B. Total Shoulder Arthroplasty (TSA)
- C. Reverse Shoulder Arthroplasty (RSA)
- D. Outcomes for all are equal

142

Copyright Jodi Gootkin 2019

8. What is the most common long-term complication associated with anatomic total shoulder arthroplasty (TSA)?

- A. Humeral shaft fracture
- B. Supraspinatus avulsion
- C. Radial nerve neuropathy
- D. Loosening of the glenoid component

140

Copyright Jodi Gootkin 2019

References

Alta, T. D. W. (2014). Reverse Shoulder Arthroplasty, Does it Work?: Kinematic Analyses, Clinical Evaluation and New Developments. <https://research.vu.nl/ws/portafiles/portal/42127568/complete%20dissertation.pdf>

Angerame, M. R., Ruder, J. A., Odum, S. M., & Hamid, N. (2017). Pain and opioid use after total shoulder arthroplasty with injectable liposomal bupivacaine versus interscalene block. *Orthopedics*, 40(5), e809-e811.

Anstuf, S. A., Sperling, J. W., & Cofield, R. H. (2008). Shoulder hemiarthroplasty for acute fractures of the proximal humerus: a minimum five-year follow-up. *Journal of shoulder and elbow surgery*, 17(2), 202-209.

Bacle, G., Nové-Josserand, L., Garaud, P., & Walch, G. (2017). Long-term outcomes of reverse total shoulder arthroplasty: a follow-up of a previous study. *JBSJ*, 9(6), 454-461.

Baertig, S. J., Wieser, K., & Gerber, C. (2017). Determinants of patient satisfaction following reconstructive shoulder surgery. *BMC Musculoskeletal Disorders*, 18(1), 458.

Barco, R., Savkovic, O. D., Sperling, J. W., Sanchez-Sotelo, J., & Cofield, R. H. (2016). Complications in reverse shoulder arthroplasty. *EFORT open reviews*, 1(3), 72-80.

Baulot, E., Sirveaux, F., & Boileau, P. (2011). Grammont's idea: the story of Paul Grammont's functional surgery concept and the development of the reverse principle. *Clinical Orthopaedics and Related Research*, 469(9), 2425-2431.

Belmont Jr, P. J., Kusnezov, N. A., Dunn, J. C., Bader, J. O., Klicynka, K., & Waterman, B. R. (2017). Predictors of hospital readmission after total shoulder arthroplasty. *Orthopedics*, 40(11), e1-e10.

Berglund, D. D., Kurovicki, J., Triplett, J. J., Rosas, S., Moor, M., Horn, B., & Levy, J. C. (2018). Comparative Outcomes Between the First and Second Operated Shoulders in Bilateral Shoulder Arthroplasty. *JAOS Global Research & Reviews*, 2(4), e073.

Berglund, D. D., Rosas, S., & Levy, J. C. (2017). American Shoulder and Elbow Surgeons membership and its association with primary and revision shoulder arthroplasty volume. *JSES Open Access*, 1(2), 51-54.

Berglund, D. D., Rosas, S., Triplett, J. J., Kurovicki, J., Horn, B., & Levy, J. C. (2018). Restoration of External Rotation Following Reverse Shoulder Arthroplasty without Latissimus Dorsi Transfer. *JSES Open Access*.

Boddapati, V. V., Fu, M. C., Schärer, W. W., Gulotta, L. V., Dines, D. M., & Dines, J. S. (2018). Revision Total Shoulder Arthroplasty is Associated with Increased Thirty-Day Postoperative Complications and Wound Infections Relative to Primary Total Shoulder Arthroplasty. *HSS Journal*, 14(1), 23-28.

Bohsali, K. I., Bois, A. J., & Wirth, M. A. (2017). Complications of shoulder arthroplasty. *JBSJ*, 9(3), 256-269.

Booker, S., Alifhad, N., Scott, M., Gooding, B., & Wallace, W. A. (2015). Use of scoring systems for assessing and reporting the outcome results from shoulder surgery and arthroplasty. *World Journal of Orthopedics*, 6(2), 244-251. <http://dx.doi.org/10.5312/wjo.v6.i2.244>

Boudreau, S., Boudreau, E. D., Higgins, L. D., & Wilcox III, R. B. (2007). Rehabilitation following reverse total shoulder arthroplasty. *Journal of Orthopaedic & Sports Physical Therapy*, 37(12), 734-743.

143

Copyright Jodi Gootkin 2019

9. Approximately, how much functional AROM should a patient have at therapeutic discharge?

- A. 30-60 degrees flexion; 15 degrees ER
- B. 60-90 degrees flexion; 30 degrees ER
- C. 80-120 degrees flexion; 30 degrees ER
- D. 120-150 degrees flexion; 60 degrees ER

141

Copyright Jodi Gootkin 2019

Boughebr, O., Kilinc, A., & Valenti, P. (2013). Reverse shoulder arthroplasty combined with a latissimus dorsal and teres major transfer for a deficit of both active elevation and external rotation. Results of 15 cases with a minimum of 2-year follow-up. *Orthopaedics & Traumatology: Surgery & Research*, 99(2), 131-137.

Buraimoh, M. A., Okoroha, K. R., Oravec, D. J., Peltz, C. D., Yeni, Y. N., & Muh, S. J. (2018). A biomechanical comparison of subscapularis repair techniques in total shoulder arthroplasty: lesser tuberosity osteotomy versus subscapularis peel. *JSES Open Access*, 2(1), 8-12.

Cancienne, J. M., Brockmeier, S. F., Gulotta, L. V., Dines, D. M., & Werner, B. C. (2017). Ambulatory total shoulder arthroplasty: a comprehensive analysis of current trends, complications, readmissions, and costs. *JBSJ*, 9(8), 629-637.

Carvalho, C. D., Andreoli, C. V., Pochini, A., de C., & Ejlertsen, B. (2016). Use of cuff tear arthroplasty head prosthesis for rotator cuff arthroplasty treatment in elderly patients with comorbidities. *Graefes*, 14(4), 502-527. <http://dx.doi.org/10.15805/S1679-45062016A03372>

Chalmers, B. P., Wagner, E. R., Houdek, M. T., Sperling, J. W., Cofield, R. H., & Sanchez-Sotelo, J. (2017). Outcomes of Primary Reverse Shoulder Arthroplasty for Dislocation Arthropathy. *Journal of Shoulder and Elbow Arthroplasty*, 1, 247154921717165.

Christie, A., Dagfinrud, H., Engen, K. M., Flaatten, H. I., Ringen, H. O., & Hagen, K. B. (2010). Surgical interventions for the rheumatoid shoulder. *The Cochrane database of systematic reviews*, (1), CD006188-CD006188.

Christie, A., Dagfinrud, H., Ringen, H. O., & Hagen, K. B. (2010). Beneficial and harmful effects of shoulder arthroplasty in patients with rheumatoid arthritis: results from a Cochrane review. *Rheumatology*, 50(5), 898-902.

Chun YM, Kim DS, Lee DH, Shin SJ. Reverse shoulder arthroplasty for four-part proximal humerus fracture in elderly patients: Can a healed tuberosity improve the functional outcomes? *J Shoulder Elbow Surg* 2017;26:1216-21

Collin, P. G., Gain, S., Huu, F. N., & Lädermann, A. (2015). Is rehabilitation effective in massive rotator cuff tears?. *Orthopaedics & Traumatology: Surgery & Research*, 101(4), S203-S205.

Cryder, S. C., Perry, S. E., & Beverly, E. A. (2018). Current Outcomes Following Reverse Total Shoulder Arthroplasty: A Composite. *Cvetanovich, G. L., Fillingham, V. A., O'Brien, M., Forsythe, E., Cole, B. J., Verma, N. N., ... & Nicholson, G. P. (2018). Transaminic acid reduces blood loss after primary shoulder arthroplasty: a double-blind, placebo-controlled, prospective, randomized controlled trial. JSES Open Access*, 2(1), 23-27.

Decker, M. J., Tokish, J. M., Ellis, H. B., Torry, M. R., & Hawkins, R. J. (2003). Subscapularis muscle activity during selected rehabilitation exercises. *The American journal of sports medicine*, 31(1), 126-134.

Dorman, G. J., Kothragel, J. C., Tantal, D. S., Patel, M., Greenopson, J. A., Denari, P. J., & Milliet, P. J. (2017). Cost-effectiveness of arthroscopic rotator cuff repair versus reverse total shoulder arthroplasty for the treatment of massive rotator cuff tears in patients with pseudoparalysis and nonarthritic shoulders. *Arthroscopy: The Journal of Arthroscopic & Related Surgery*, 33(4), 716-725.

Dowdle, S. B., Glass, N., Anthony, C. A., & Heltrich, C. M. (2017). Use of PROMIS for Patients Undergoing Primary Total Shoulder Arthroplasty. *Orthopaedic Journal of Sports Medicine*, 5(9), 232596717726044.

144

Copyright Jodi Gootkin 2019

Eichinger, Josef & R Miller, Lindsay & Harshorn, Timothy & Li, Xinming & J.P. Warner, Jon & D Higgins, Laurence. (2015). Evaluation of satisfaction and durability after hemiarthroplasty and total shoulder arthroplasty in a cohort of patients aged 50 years or younger: An analysis of discordance of patient satisfaction and implant survival. *Journal of shoulder and elbow surgery*. *Journal of Shoulder and Elbow Surgery* 25, 10.1016/j.jse.2015.09.028.

Ekelund, A. L., & Seebauer, L. (2016). Acromial and scapular spine fractures after reverse shoulder arthroplasty. *Obere Extremität*, 12(1), 32-37.

Ernstbrunner, L., Suter, A., Catanzaro, S., Rahm, S., & Gerber, C. (2017). Reverse Total Shoulder Arthroplasty for Massive, Irreparable Rotator Cuff Tears Before the Age of 60 Years: Long-Term Results. *JBJS*, 99(20), 1721-1729.

Famillet, F., Rojas, J., Nedim Doral, M., Huri, G., & McFarland, E. G. (2018). Reverse total shoulder arthroplasty. *EFORT Open Reviews*, 3(2), 58-69.

Favard L, LeVigne C, Nerot Cet al. Reverse prostheses in arthropathies with cuff tear: Are survivorship and function maintained over time? *Clin Orthop Relat Res* 2011;469:2469-75.

Favard, L., LeVigne, C., Nerot, C., Gerber, C., De Wilde, L., & Mole, D. (2011). Reverse Prostheses in Arthropathies With Cuff Tear: Are Survivorship and Function Maintained Over Time? *Clinical Orthopaedics and Related Research*, 469(9), 2469-2475.

Fischer, C. A., Weber, M. A., Neubecker, C., Bruckner, T., Tanner, M., & Zellfang, F. (2015). Ultrasound vs. MRI in the assessment of rotator cuff structure prior to shoulder arthroplasty. *Journal of orthopaedics*, 12(1), 23-30.

Floyd, S. B., Chapman, C. G., Thigpen, C. A., Brooks, J. M., Hawkins, R. J., & Tokish, J. M. (2018). Shoulder arthroplasty in the US Medicare population: a 1-year evaluation of surgical complications, hospital admissions, and revision surgery. *JSES Open Access*, 2(1), 40-47.

Friedman, R. J., Flurin, P. H., Wright, T. W., Zuckerman, J. D., & Roche, C. P. (2017). Comparison of reverse total shoulder arthroplasty outcomes with and without subscapularis repair. *Journal of Shoulder and Elbow Surgery*, 26(4), 662-668.

Garcia, G. H., Gausden, E., Taylor, S. A., Dines, D. M., & Dines, J. S. (2013). Arthroplasty for Proximal Humerus Fractures: A Review of Current Management. *Techniques in Orthopaedics*, 28(4), 334-332.

Giardella, A., Ascione, F., Mocchi, M., Berlusconi, M., Romano, A. M., Oliva, F., & Maradei, L. (2017). Reverse total shoulder versus angular stable plate treatment for proximal humeral fractures in over 65 years old patients. *Muscles, ligaments and tendons journal*, 7(2), 271.

Goodman, J., Lau, B. C., Krupp, R. J., Getz, C. L., Feeley, B. T., Ma, C. P. (2017). Clinical measurements versus patient-reported outcomes: analysis of the American Shoulder and Elbow Surgeons physical assessment in patients undergoing reverse total shoulder arthroplasty. *JSES Open Access*.

Gregory, T. M., Boukous, B., Gregory, J., Pierrat, J., & Masmeejan, E. (2017). Suppl-6, MS: Short, Medium and Long Term Complications After Total Anatomical Shoulder Arthroplasty. *The Open Orthopaedics Journal*, 11, 1133.

145

Morris, B. J., Hägler, R. E., Laughlin, M. S., Elkousy, H. A., Gartsman, G. M., & Edwards, T. B. (2015). Workers' compensation claims and outcomes after reverse shoulder arthroplasty. *Journal of Shoulder and Elbow Surgery*, 24(3), 453-459.

Namdari, S., Horneff, J. G., & Baldwin, K. (2013). Comparison of hemiarthroplasty and reverse arthroplasty for treatment of proximal humeral fractures: a systematic review. *JBJS*, 95(16), 1701-1708.

Nicholson, T., Maltenfort, M., Getz, C., Lissner, M., Williams, G., & Namdari, S. (2018). Multimodal Pain Management Protocol Versus Patient Controlled Narcotic Analgesia for Postoperative Pain Control after Shoulder Arthroplasty. *The Archives of Bone and Joint Surgery*, 6(3), 196-202.

Oquist, M., Hallberg, K., Rahme, H., Salomonsson, B., & Rosso, A. (2018). Lower age increases the risk of revision for stemmed and resurfacing shoulder hemiarthroplasty: A study from the Swedish shoulder arthroplasty register. *Acta orthopaedica*, 89(1), 3-9.

Pastora-Bernell, J. M., Martín-Valeiro, R., Barón-López, F. J., & Estebano-Ruiz, M. J. (2017). Evidence of benefit of telehabilitation after orthopaedic surgery: a systematic review. *Journal of medical Internet research*, 19(4).

Peiri, M., Euler, S. A., Dornan, G. J., Greenspoon, J. A., Horan, M. P., Kathagan, J. C., & Millett, P. J. (2016). Predictors for satisfaction after anatomic total shoulder arthroplasty for idiopathic glenohumeral osteoarthritis. *Archives of Orthopaedic and Trauma Surgery*, 136(6), 755-762.

Phadnis, J., Huang, T., Watts, A., Krishnan, J., & Bain, G. I. (2016). Cemented or cementless humeral fixation in reverse total shoulder arthroplasty? a systematic review. *Bone Joint J*, 98(1), 65-74.

Pinkas, D., Wiater, B., & Wiater, J. M. (2015). The glenoid component in anatomic shoulder arthroplasty. *JAOS-Journal of the American Academy of Orthopaedic Surgeons*, 23(5), 317-326.

Raisz, P., Alami, G., Bruckner, T., Magosch, P., Habermeyer, P., Boileau, P., & Walch, G. (2018). Reverse shoulder arthroplasty for type 1 sequelae of a fracture of the proximal humerus. *Bone Joint J*, 100(3), 316-323.

Ramano, A. M., Oliva, F., Nastucci, G., Castelli, P., Di Giunta, A., Susanna, M., & Ascione, F. (2017). Reverse shoulder arthroplasty patient personalized rehabilitation protocol. Preliminary results according to prognostic groups. *Muscles, Ligaments and Tendons Journal*, 7(2), 263.

Roren, A., Nguyen, C., Palazzo, C., Fayad, F., Revel, M., Gregory, T., ... & Lefevre-Colau, M. M. (2017). Kinematic analysis of the shoulder complex after anatomic and reverse total shoulder arthroplasty: A cross-sectional study. *Musculoskeletal Science and Practice*, 29, 84-90.

Rosas, S., Kurovicki, J., Triplett, J. J., Berglund, D. D., Horn, B., & Levy, J. C. (2016). Discharge Disposition Costs Following Total Shoulder Arthroplasty: A Comprehensive National Analysis. *Journal of Shoulder and Elbow Arthroplasty*, 1, 2471549217740242.

Routman, H. D. (2013). The role of subscapularis repair in reverse total shoulder arthroplasty. *Bulletin of the Hospital for Joint Diseases*, 71.

Roy, J. S., Macdarmid, J. C., Faber, K. J., Drosowich, D. S., & Athwal, G. S. (2010). The simple shoulder test is responsive in assessing change following shoulder arthroplasty. *Journal Of Orthopaedic & Sports Physical Therapy*, 40(7), 413-421.

148

Gregory, T. M., Gregory, J., Nicolas, E., Pierrat, J., & Masmeejan, E. (2017). Suppl-6, MS: Shoulder Arthroplasty Imaging: What's New. *The Open Orthopaedics Journal*, 11, 1126.

Grewe, R. M. (2017). Posterior Rotator Cuff-Sparing Total Shoulder Arthroplasty: Three Cases. *JAAOS Global Research & Reviews*, 1(1), e002.

Hamden, C. T. (2016). Occupational Therapy in the Acute Rehabilitation of Post-Surgical Shoulder Arthroplasty. *OT Practice*, 21(07).

Haw, N., Magosch, P., Tauber, M., Lichtenberg, S., & Habermeyer, P. (2017). Nine-year outcome after anatomic stemless total shoulder arthroplasty: clinical and radiologic results. *Journal of Shoulder and Elbow Surgery*, 26(9), 1609-1615.

Hawi, Nael, Mark Tauber, Michael Joseph Messina, Peter Habermeyer, and Frank Marietschläger. 2016. "Anatomic stemless shoulder arthroplasty and related outcomes: a systematic review." *BMC Musculoskeletal Disorders* 17 (1): 376.

Johnson, C. C., Johnson, D. J., Liu, J. N., Dines, J. S., Dines, D. M., Gulotta, L. V., & Garcia, G. H. (2016). Return to sports after shoulder arthroplasty. *World Journal of Orthopaedics*, 7(9), 519.

Kadum, B. (2015). Total Shoulder Arthroplasty: clinical and radiological studies on the implant positioning and fixation (Doctoral dissertation, Umeå university).

Kadum, B., Ingul, C., Irmann, R., Spöden, G. O., & Sayed-Noor, A. S. (2018). Higher preoperative sensitivity to pain and pain at rest are associated with worse functional outcome after stemless total shoulder arthroplasty: a prospective cohort study. *Bone Joint J*, 100(4), 480-484.

Kany, J., Jose, J., Katz, D., Wertheil, J. D., Sekaran, P., Amaravathi, R. S., & Valenti, P. (2017). The main cause of instability after unconstrained shoulder prosthesis is soft tissue deficiency. *Journal of Shoulder and Elbow Surgery*, 26(8), e245-e251.

Keener, R. J., Chalmers, P. N., & Yamaguchi, K. (2017). The humeral implant in shoulder arthroplasty. *JAAOS-Journal of the American Academy of Orthopaedic Surgeons*, 25(6), 427-438.

Kim, B. G., Han, J. U., Song, J. H., Yang, C., Lee, B. W., & Baek, J. S. (2017). A comparison of ultrasound-guided interscalene and suprascapular blocks for post-operative analgesia after shoulder surgery. *Acta Anaesthesiologica Scandinavica*, 61(4), 427-435.

King, J. J., Patrick, M. R., Strub, A. M., Schneider, R. E., Farmer, K. W., Garvan, C., & Wright, T. W. (2017). Perioperative Factors Affecting the Length of Hospitalization After Shoulder Arthroplasty. *JAAOS Global Research & Reviews*, 1(6), e026.

Klem, C., Prindl, J. A., Morgans, S., Smith, S. H., Nohle, D., Reilly, P., & Bull, A. M. (2018). Analysis of shoulder compressive and shear forces during functional activities of daily life. *Clinical Biomechanics*, 54, 34-41.

Kurovicki, J., Rosas, S., Law, V., Levy, J. (2018). Participation in Work and Sport Following Reverse and Total Shoulder Arthroplasty. *Am J Orthop*, May 23, 2018.

Liedermann, A., Denard, P. J., Trefort, J., Collin, P., Nowak, A., & Schwitzgebel, A. J. P. (2017). Subscapularis and deltoid-sparing vs traditional deltoid-sparing approach in reverse shoulder arthroplasty: a prospective case-control study. *Journal of Orthopaedic Surgery and Research*, 12(1), 112.

146

Sabesan, V. J., Lombardo, D. J., Khan, J., & Wiater, J. M. (2015). Assessment of the optimal shoulder outcome score for reverse shoulder arthroplasty. *Journal of shoulder and elbow surgery*, 24(10), 1653-1659.

Sabesan, V. J., Lombardo, D. J., Khan, J., & Wiater, J. M. (2015). Assessment of the optimal shoulder outcome score for reverse shoulder arthroplasty. *Journal of shoulder and elbow surgery*, 24(10), 1653-1659.

Salami, P., & Speer, K. P. (2013). Post-rehabilitation exercise considerations following total shoulder arthroplasty. *Strength & Conditioning Journal*, 35(4), 56-63.

Sanchez-Sotelo, J. (2017). Subscapularis Tenotomy in Anatomic Total Shoulder Arthroplasty. *Journal of Shoulder and Elbow Arthroplasty*, 1, 2471549217743805.

Sanchez-Sotelo, J., Nguyen, N. T. V., & Morey, M. (2018). Anatomic Total Shoulder Arthroplasty Using a Self-Pressurizing Pegged Bone-Preserving Cemented Glenoid Component: A 2-to-5-Year Follow-up Study. *Journal of Shoulder and Elbow Arthroplasty*, 2, 2471549217750478.

Saviole III, F. H., Charles, R., Casselton, J., O'Brien, M. J., & Hart III, J. A. (2015). The subscapularis-sparing approach in humeral head replacement. *Journal of shoulder and elbow surgery*, 24(4), 605-612.

Sciascia, A. D., Morris, B. J., Jacobs, C. A., & Edwards, T. B. (2017). Responsiveness and internal validity of common patient-reported outcome measures following total shoulder arthroplasty. *Orthopaedics*, 40(3), e513-e519.

Sevian, N., Ferreira, N., Andrade, R., Moreira, P., Portugal, R., Alves, D., ... & Espregueira-Mendes, J. (2017). Reverse shoulder arthroplasty for irreparable massive rotator cuff tears: a systematic review with meta-analysis and meta-regression. *Journal of Shoulder and Elbow Surgery*, 26(9), e265-e277.

Shields, E. J., Koueiter, D. M., Mierz, T., Schwark, A., & Wiater, J. M. (2017). Previous Rotator Cuff Repair Is Associated With Inferior Outcomes After Reverse Total Shoulder Arthroplasty. *Journal of Sports Medicine*, 51(10), 2325967117730311.

Simovitch, R. W., Nayak, A., Scalis, J., Boudreaux, R., Olmscheid, N., Worhaz, K., ... & Roche, C. (2018). Biomechanical characteristics of subscapularis-sparing approach for anatomic total shoulder arthroplasty. *Journal of Shoulder and Elbow Surgery*, 27(1), 133-140.

Simovitch, R., Flurin, P. H., Marczuk, V., Friedman, R., Wright, T. W., Zuckerman, J. D., & Roche, C. P. (2015). Rate of improvement in clinical outcomes with anatomic and reverse total shoulder arthroplasty. *Journal of Bone and Joint Surgery*, 98, 1501-11.

Singh, J. A., Sperling, J., Buchbinder, R., & McMAKEN, K. E. L. L. Y. (2011). Surgery for shoulder osteoarthritis: A Cochrane systematic review. *The Journal of Rheumatology*, 38(4), 598-605.

Singhal, K., & Ramnathan, R. (2018). Going forward with reverse shoulder arthroplasty. *Journal of Clinical Orthopaedics & Trauma*, 9(1), 87-93.

Smith, C. D., Guyver, P., & Bunker, T. D. (2012). Indications for reverse shoulder replacement: a systematic review. *The Journal of bone and joint surgery British volume*, 94(5), 577-583.

Somerson, J. S., Naratleik, M. B., Hsu, J. E., Gee, A. O., & Matsen, F. A. (2017). Is there evidence that the outcomes of primary anatomic and reverse shoulder arthroplasty are getting better?. *International Orthopaedics*, 41(6), 1235-1244.

149

Liedermann, A., Lüdtke, A., Meis, B., Siem, R., Christofopoulos, P., Bacle, G., & Walch, G. (2011). Prevalence of neurologic lesions after total shoulder arthroplasty. *JBJS*, 93(14), 1288-1293.

Lefevre-Colau, M. M., Nguyen, C., Palazzo, C., Strouf, F., Paris, G., Vuillemin, V., ... & Roren, A. (2018). Recent advances in kinematics of the shoulder complex in healthy people. *Annals of physical and rehabilitation medicine*, 61(1), 56.

Lefevre-Colau, M. M., Nguyen, C., Strouf, F., Paris, G., Vuillemin, V., ... & Roren, A. (2017). Kinematic patterns in normal and degenerative shoulders. Part II: Review of 3-D scapular kinematic patterns in patients with shoulder pain and clinical implications. *Annals of physical and rehabilitation medicine*.

Leroux, T. S., Zuke, W. A., Saltzman, B. M., Ga, B., Verma, N. N., Romeo, A. A., ... & Forsythe, B. (2018). Safety and patient satisfaction of outpatient shoulder arthroplasty. *JSES Open Access*, 2(1), 13-17.

Lin, D. J., Wong, T. T., & Kazam, J. K. (2016). Shoulder arthroplasty, from indications to complications: what the radiologist needs to know. *Radiographics*, 36(1), 192-208.

Maier, M. W., Caspers, M., Zellfang, F., Dreher, T., Klotz, M. C., Wolf, S. I., & Kasten, P. (2014). How does reverse shoulder replacement change the range of motion in activities of daily living in patients with cuff tear arthropathy? A prospective optical 3D motion analysis study. *Archives of orthopaedic and trauma surgery*, 134(8), 1065-1071.

Maier, M. W., Niklasch, M., Dreher, T., Zellfang, F., Rettig, O., Klotz, M. C., ... & Kasten, P. (2014). Motion patterns in activities of daily living: 3-year longitudinal follow-up after total shoulder arthroplasty using an optical 3D motion analysis system. *BMC Musculoskeletal Disorders*, 15(1), 244.

Mannava, S., Horan, M. P., Frangiamore, S. J., Fritz, E. M., Godin, J. A., Pogorzelski, J., & Millett, P. J. (2017). Return to Recreational Sporting Activities Following Total Shoulder Arthroplasty. *Orthopaedic Journal of Sports Medicine*, 5(7, suppl6), 2325967117300296.

Manske, R. C. (2006). Electromyographically based rehabilitation exercises for the scapular muscles.

Matache, B. A., & Lapner, P. (2017). Suppl-6, M4: Anatomic Shoulder Arthroplasty: Technical Considerations. *The Open Orthopaedics Journal*, 11, 1115.

Mason III, F. A., Clinton, J., Lynch, J., Bertelsen, A., & Richardson, M. L. (2008). Glenoid component failure in total shoulder arthroplasty. *JBJS*, 90(4), 885-896.

Matteli, L., Mortera, S., Arngoni, C., & Castoldi, F. (2015). Anatomic shoulder arthroplasty: an update on indications, technique, results and complication rates. *Joins*, 3(2), 72-77.

Mayne, I. P., Bell, S. N., Wright, W., & Coghlan, J. A. (2016). Acromial and scapular spine fractures after reverse total shoulder arthroplasty. *Shoulder & Elbow*, 8(2), 90-100.

Merolla, G. (2013). Shoulder replacement in advanced glenohumeral osteoarthritis: current concepts review. *OA Orthopaedics*, 1, 7.

Merolla, G., Nastucci, G., & Porcellini, G. (2013). Shoulder arthroplasty in osteoarthritis: current concepts in biomechanics and surgical technique. *Translational Medicine - Umeå*, 6, 16 - 26.

147

Sowa, B., Bochenek, M., Böhlhoff, M., Zellfang, F., Loew, M., Bruckner, T., & Raisz, P. (2017). The medium- and long-term outcome of total shoulder arthroplasty for primary glenohumeral osteoarthritis in middle-aged patients. *Bone Joint J*, 99(7), 930-943.

Syed, U. A. M., Davis, D. E., Wei, Ko, J., Lee, B. K., Huttman, D., Seidi, A., ... & Abboud, J. A. (2017). Quantitative Anatomical Differences in the Shoulder. *Orthopaedics*, 40(3), 155-160.

Szerlip, B. W., Morris, B. J., Laughlin, M. S., Killan, C. M., & Edwards, T. B. (2018). Clinical and radiographic outcomes after total shoulder arthroplasty with an anatomic press-fit short stem. *Journal of Shoulder and Elbow Surgery*, 27(1), 10-16.

Tenier, A., Medel, F., Pioletti, D. P., & Farron, A. (2009). Comparison of polyethylene wear in anatomical and reverse shoulder prostheses. *The Journal of bone and joint surgery British volume*, 91(7), 977-982.

Tenier, A., Scheuber, P., Pioletti, D. P., & Farron, A. (2013). Activities of daily living with reverse prostheses: importance of scapular compensation for functional mobility of the shoulder. *Journal of shoulder and elbow surgery*, 22(7), 948-953.

Teusink, M. J., Pappou, I. P., Schwartz, D. G., Cottrell, B. J., & Franke, M. A. (2015). Results of closed management of acute dislocation after reverse shoulder arthroplasty. *Journal of shoulder and elbow surgery*, 24(4), 621-627.

Tha, A., Hardy, P., & Bak, K. (2015). Decision-making in massive rotator cuff tear. *Knee Surgery, Sports Traumatology, Arthroscopy*, 23(2), 448-459.

Throckmorton, T. W. (2016). Glenohumeral Arthritis: Current Indications for Hemiarthroplasty Versus Total Shoulder Arthroplasty. *Techniques in Shoulder & Elbow Surgery*, 17(1), 25-26.

Vivik, M. S., Nicholson, G. P., & Romeo, A. A. (2018). Suppl 1, MS: Irreparable Rotator Cuff Tears Without Arthritis Treated With Reverse Total Shoulder Arthroplasty. *The Open Orthopaedics Journal*, 10, 296.

Wells, D. B., Holt, A. M., Smith, R. A., Brolin, T. J., Azar, F. M., & Throckmorton, T. W. (2018). Tobacco use predicts a more difficult episode of care after anatomic total shoulder arthroplasty. *Journal of Shoulder and Elbow Surgery*, 27(1), 23-28.

Werner CML, Steinmann PA, Gibart M, Gerber C. Treatment of painful pseudoparalysis due to irreparable rotator cuff dysfunction with the Delta III reverse-ball-and-socket total shoulder prosthesis. *J Bone Joint Surg [Am]* 2005;87:1476-8.

Werthel, J. D., Lonjon, G., Jo, S., Colled, R., Sperling, J. W., & Elhasan, B. T. (2017). Long-term outcomes of cemented versus cementless humeral components in arthroplasty of the shoulder: a propensity score-matched analysis. *Bone Joint J*, 99(5), 666-673.

Wiater, J.M. (2011). Shoulder Joint Replacement. *American Academy of Orthopaedic Surgeons*.

http://orthoinfo.aaos.org/en/treatment/shoulder-joint-replacement/

Woff, A. L., & Rosenzweig, L. (2017). Anatomical and biomechanical framework for shoulder arthroplasty rehabilitation. *Journal of Hand Therapy*, 30(2), 167-174.

Yang, Y., Zuo, J., Liu, T., Shao, P., Wu, H., Gao, Z., & Xiao, J. (2018). Glenoid morphology and the safe zone for protecting the suprascapular nerve during baseplate fixation in reverse shoulder arthroplasty. *International Orthopaedics*, 42(3), 587-593.

Yoon, J. P., Seo, A., Kim, J. G., Lee, C. H., Baek, S. H., Kim, S. Y., ... & Chung, S. W. (2017). Deltoid muscle volume affects clinical outcome of reverse total shoulder arthroplasty in patients with cuff tear arthropathy or irreparable cuff tears. *PLoS one*, 12(3), e0174361.

Zilber, S. (2017). Suppl-6, M2: Shoulder Arthroplasty: Historical Considerations. *The Open Orthopaedics Journal*, 11, 1100.

150

Shoulder Arthroplasty Resource Links

American Shoulder and Elbow Surgeons Score (ASES)

[https://journals.lww.com/jorthotrauma/Fulltext/2006/09001/American Shoulder and Elbow Surgeons ASES .33.aspx](https://journals.lww.com/jorthotrauma/Fulltext/2006/09001/American_Shoulder_and_Elbow_Surgeons_ASES_33.aspx)

Constant Murley Score (CMS)

<http://orthotoolkit.com/constant-shoulder/>

Shoulder Pain and Disability Index (SPADI)

<https://www.tac.vic.gov.au/files-to-move/media/upload/spi.pdf>

Simple Shoulder Test (SST)

<http://orthodoc.aaos.org/rickmatsen/SST.doc>