

Shoulder Arthroplasty

Goals and Objectives

Course Description

"Shoulder Arthroplasty is an online recorded video of a previously presented live CE webinar for physical therapists and physical therapist assistants that examines surgical management of shoulder pathology through joint arthroplasty. This course includes a review of current literature relating to shoulder pathophysiology, arthrokinematics, arthroplasty procedures, and post-surgical care.

Course Rationale

The purpose of this course is to provide physical therapy professionals with contemporary information about degenerative shoulder pathophysiology, arthroplasty procedures, post-operative arthrokinematics, precautions, and potential complications.

Course Goals and Objectives

Upon completion of this course, participants will be able to:

1. List and identify all common orthopedic structures of the shoulder girdle.
2. Recognize and define common degenerative and traumatic shoulder pathologies.
3. Define normal and pathologic shoulder arthrokinematics
4. Identify the three most common shoulder arthroplasty surgical procedures.
5. Identify possible post-surgical complications following shoulder arthroplasty.
6. Recognize anatomical and post-arthroplasty shoulder kinematics.
7. Identify expected functional outcomes following shoulder arthroplasty.
8. Identify post-operative precautions

Course Provider – Innovative Educational Services

Provider Contact Information – information@cheapceus.com

Course Instructor – Jodi Gootkin, PT, Med, CEAS

Financial/Non-financial Disclosure - Neither the Provider nor the instructor have any financial or non-financial conflict of interest related to the presentation of this CE program.

Target Audience – Physical Therapists, Physical Therapist Assistants

Course Educational Level – This course is applicable for introductory learners.

Course Prerequisites – None

Instructional Method – Distance Learning – Independent; Asynchronous online video-based home study

Location - Cheapceus.com

Date – Continuously available on-demand

PD Activity Completion Requirements / Criteria for Issuance of CE Credits – Completion of viewing of 1 hour recorded video, and a score of 70% correct or greater on the course post-test.

Continuing Education Credits – Three (3) contact hours

Course Fee - \$34.95

Registration Information – No pre-registration required; available on-demand at Cheapceus.com

Special Needs Requests – Email: information@cheapceus.com or phone: 954-663-4101

Cancellation by the Learner – Learners may cancel their participation at any time and receive a full refund of all paid fees.

Cancellation by the Provider – Registrants for the cancelled activity will be contacted by an IES staff member via phone call or email within 12 hours of the cancellation decision. If the decision to cancel is made less than 14 hours prior to the event, each participant will be contacted no later than 2 hours prior to the scheduled start time of the activity. Registrants will receive a full refund if an activity is cancelled by the Provider. The refund will be processed back to the Registrant within 12 hours of the cancellation.

Complaint Resolution – Please call 954-663-4101 (24 hours/day, 7 days/week) to speak with a live customer service agent. Our goal is to work with our customers to resolve all issues to the customer's satisfaction with just one phone call whenever possible.

Refund Policy - Unrestricted 100% refund upon request. The request for a refund by the learner shall be honored in full without penalty or other consideration of any kind. The request for a refund may be made by the learner at any time without limitations before, during, or after course participation.

Shoulder Arthroplasty

Presented By
Jodi Gootkin, PT, MED, CEAS
jodiemail@comcast.net

1

Copyright Jodi Gootkin

1

Course Overview

- “Shoulder Arthroplasty” examines surgical management of shoulder pathology through joint arthroplasty. This course includes a review of current literature relating to pathophysiology of shoulder pathology, shoulder arthrokinematics, specific arthroplasty procedures, post-surgical medical management, and anticipated rehabilitation outcomes.

2

Copyright Jodi Gootkin

2

Course Rationale

- The purpose of this course is to provide a comparative analysis of surgical techniques and post-surgical management to understand current prosthetic advances, rehabilitation considerations and maximize outcomes based on current research.

3

Copyright Jodi Gootkin

3

Goals and Objectives

1. List and identify all common orthopedic structures of the shoulder girdle.
2. Recognize and define common degenerative and traumatic shoulder pathologies.
3. Define normal and pathologic shoulder arthrokinematics
4. Identify current surgical and non-surgical management strategies for treating shoulder arthropathy
5. Compare and contrast the three most common shoulder arthroplasty surgical procedures.
6. Identify post-surgical complications following shoulder arthroplasty.
7. Compare anatomical and post-arthroplasty shoulder kinematics.
8. Identify the primary goals of post-surgical patient management.
9. Detail factors associated with improved outcomes following total joint replacement.
10. Outline the components of a comprehensive rehabilitation program following shoulder arthroplasty.

4

Copyright Jodi Gootkin

4

Disclaimer

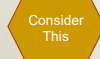- Application of concepts presented in this webinar is at the discretion of the individual participant in accordance with federal, state, and professional regulations.

5

Copyright Jodi Gootkin

Shoulder Arthroplasty

Course Outline and Schedule



Topic	Time
Shoulder Anatomy	0:00-0:05
Shoulder Arthrokinematics	0:06-0:10
Shoulder Pathology	0:11-0:15
Traumatic	0:16-0:20
Degenerative	0:21-0:25
Irreparable Rotator Cuff Tear	0:26-0:30
History of Shoulder Replacement Surgery	0:31-0:35
Hemiarthroplasty	0:36-0:40
Anatomic Total Shoulder Arthroplasty	0:41-0:50
Interactive Discussion of Clinical Applications	0:51-1:00
Reverse Shoulder Arthroplasty	1:01-1:10
Surgical Approach	1:11-1:25
Acute Post-Surgical Management	1:26-1:35
Complications	1:36-1:50
Interactive Discussion of Clinical Applications	1:51-2:00
Rehabilitation	2:01-2:05
Arthrokinematics	2:06-2:10
Rehabilitation Phases	2:11-2:25
Functional Outcomes	2:26-2:35
Assessment Tools	2:36-2:45
Prosthetic Survival	2:46-2:50
Interactive Discussion of Clinical Applications	2:51-3:00

Copyright Jodi Gootkin

6

Copyright Innovative Educational Services and Jodi Gootkin. All rights reserved.

Reproduction, reuse, or republication of all or any part of this presentation is strictly prohibited without prior written consent of both Innovative Educational Services and Jodi Gootkin.

How To Obtain CEUs For This Course

- After watching the video go to www.cheapceus.com
- Complete the post test with score of at least 70%
 - May be retaken multiple times
- Submit online payment for course
- Print certificate
- **Course review and summary for post test at the end of the webinar.**



Consider This

7

Copyright Jodi Gootkin

7

Shoulder Anatomy

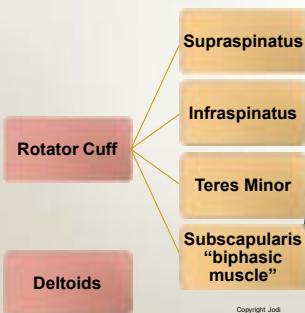
- Functional use of the upper extremity occurs through coordinated movement of the triaxial ball and socket glenohumeral joint with the scapulothoracic, sternoclavicular, and acromioclavicular joints.

8

Copyright Jodi Gootkin

8

Shoulder Musculature



9

Copyright Jodi Gootkin

9

Convex-Concave Rule

- Normal arthrokinematics of the shoulder follow the convex on concave rule.
- With open chain motions, the convex humeral head moves against the concave glenoid surface with roll and glide occurring in opposite directions.

Motion	Roll	Glide
Abduction	Superior	Inferior
Flexion (Anterior Elevation)	Anterior	Posterior
Internal Rotation	Anterior	Posterior
External Rotation	Posterior	Anterior

Consider This

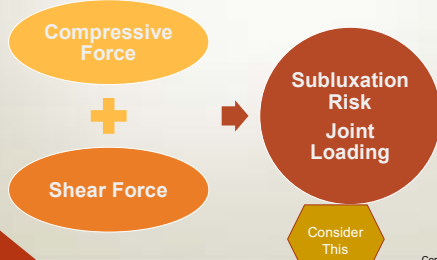
10

Copyright Jodi Gootkin

10

Compressive and Shear Forces

The articular surface area of the humeral head is approximately three times greater than that of the glenoid fossa requiring the joint to rely on surrounding soft tissue structures for stability.



Consider This

11

Copyright Jodi Gootkin

Shoulder¹¹ Arthroplasty

Shoulder Arthrokinematics

- The rotator cuff provides inherent joint stability through compression of the humeral head against the glenoid fossa.
- The cuff muscles function as a force couple creating dynamic stabilization so the deltoid can elevate and abduct the shoulder with the glenoid acting as a fulcrum.

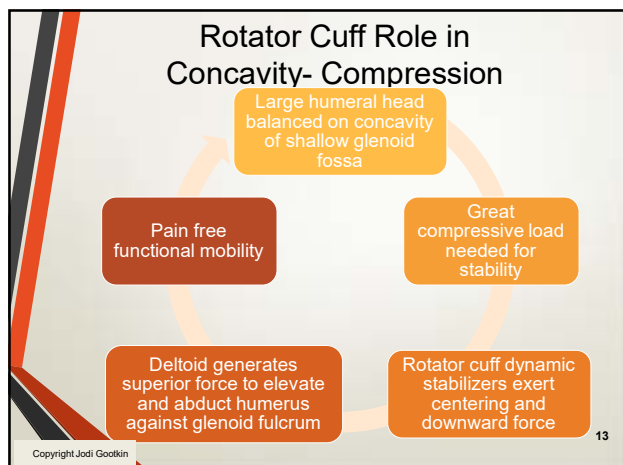
12

Copyright Jodi Gootkin

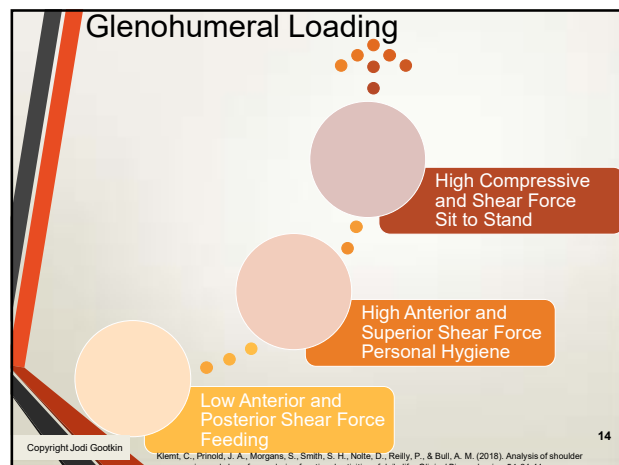
12

Copyright Innovative Educational Services and Jodi Gootkin. All rights reserved.

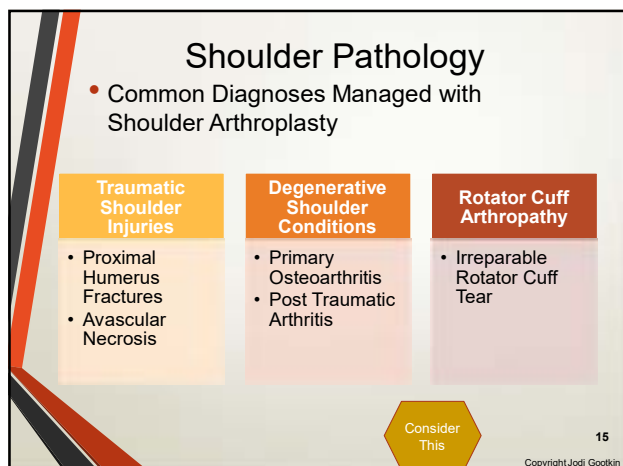
Reproduction, reuse, or republication of all or any part of this presentation is strictly prohibited without prior written consent of both Innovative Educational Services and Jodi Gootkin.



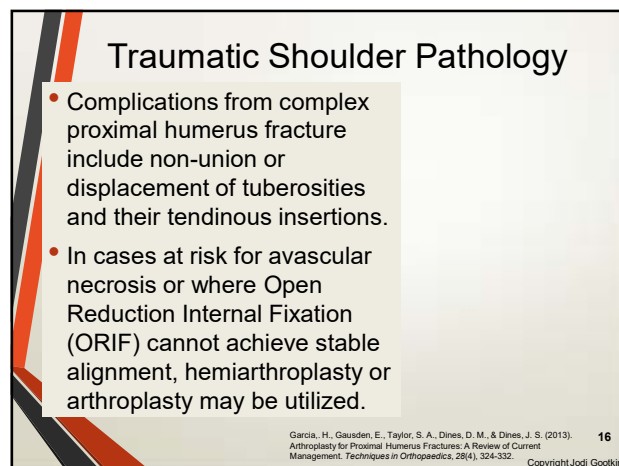
13



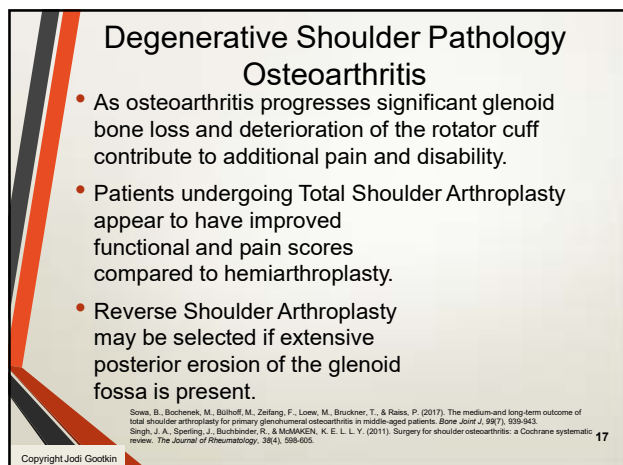14



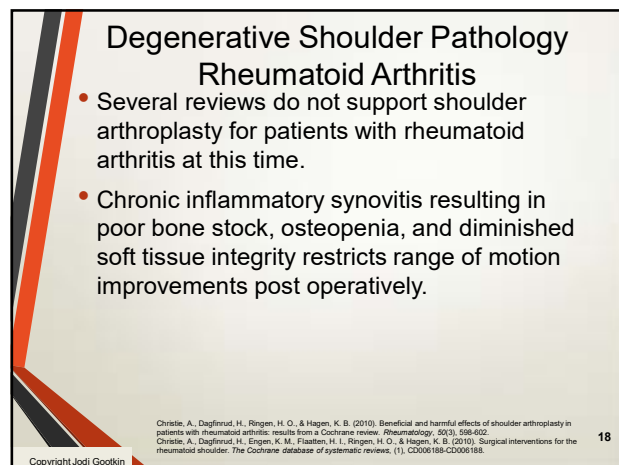
15



16



17



18

Shoulder Arthroplasty

Copyright Innovative Educational Services and Jodi Gootkin. All rights reserved.

Reproduction, reuse, or republication of all or any part of this presentation is strictly prohibited without prior written consent of both Innovative Educational Services and Jodi Gootkin.

Irreparable Rotator Cuff Tear

- Massive rotator cuff tears involve multiple tendons significantly limiting function.
- Anterosuperior tear – subscapularis/supraspinatus
- Posterosuperior tear – supraspinatus/infraspinatus/teres minor

Full thickness rupture of 2 or more tendons or tear dimension > 5 cm

Fatty infiltration of muscles Goutallier stage 3-4

Shoulder pseudoparalysis

19 Copyright Jodi Gootkin

19

Rotator Cuff Arthropathy

- The development of severe shoulder arthritis concurrent with rotator cuff tear is diagnosed in the presence of specific clinical findings:
- Insufficient rotator cuff **Irreparable** = **Massive**
- Glenohumeral osteoarthritis
- Superior migration of humeral head

20 Copyright Jodi Gootkin

20

Rotator Cuff Deficiency

- In the absence of the normal concavity compression from a functioning rotator cuff, the humeral head migrates superiorly with deltoid contraction.

21 Copyright Jodi Gootkin

21

Pseudojoint Formation

- Humeral impingement against the acromion leads to degenerative changes referred to as “acetabularization” of the under surface of the acromion and “femoralization” of the humeral head.

22 Copyright Jodi Gootkin

22

Radiologic Findings

- Seebauer Classification
 - Type I - humeral head and glenoid fossa remain concentric
 - Type 2 - humeral head migrates superiorly
- Hamada Classification

Grade 1	AHI greater than or equal to 6 mm
Grade 2	AHI less than or equal to 5 mm
Grade 3	Grade 2 plus acetabularization of acromion
Grade 4	Grade 3 plus glenohumeral arthritis
Grade 5	Grade 4 plus humeral head collapse

23 Copyright Jodi Gootkin

Shoulder Arthroplasty

Shoulder Pseudoparalysis

Large humeral head balanced on concavity of shallow glenoid fossa

Glenohumeral osteoarthritic changes and painful ROM

Non-functioning rotator cuff

Failure to apply compressive load to humeral head

PSEUDOPARALYSIS
Painless loss of active elevation

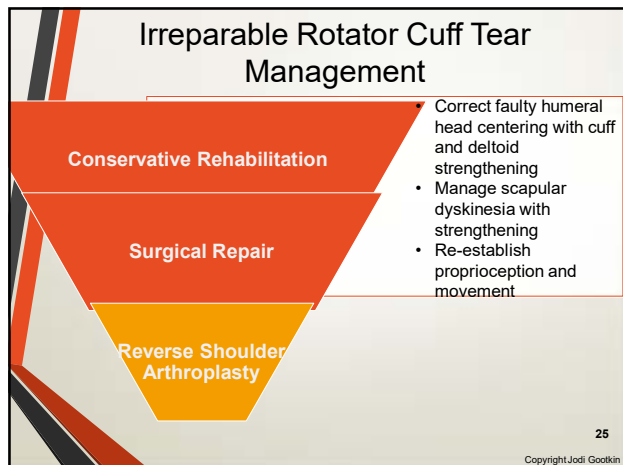
Humeral head migrates superiorly with deltoid contraction

24 Copyright Jodi Gootkin

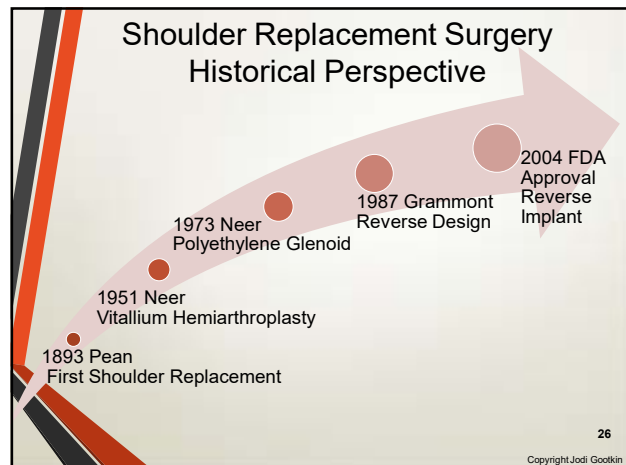
24

Copyright Innovative Educational Services and Jodi Gootkin. All rights reserved.

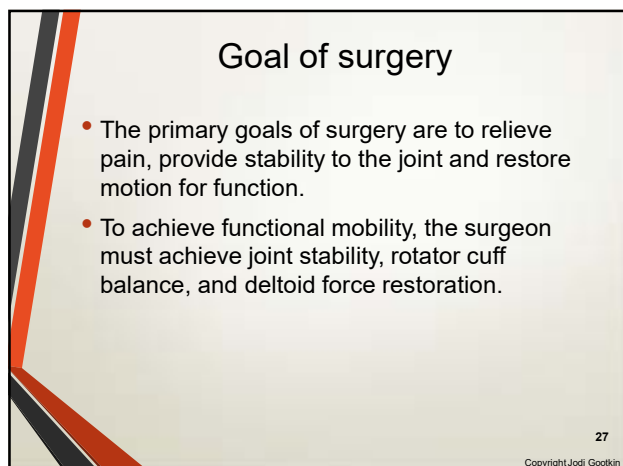
Reproduction, reuse, or republication of all or any part of this presentation is strictly prohibited without prior written consent of both Innovative Educational Services and Jodi Gootkin.



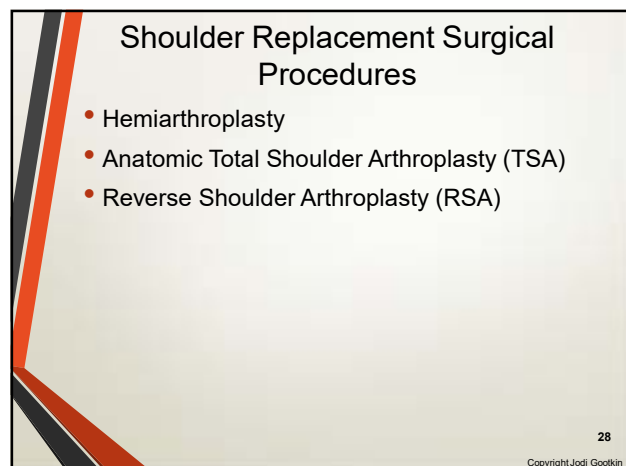25



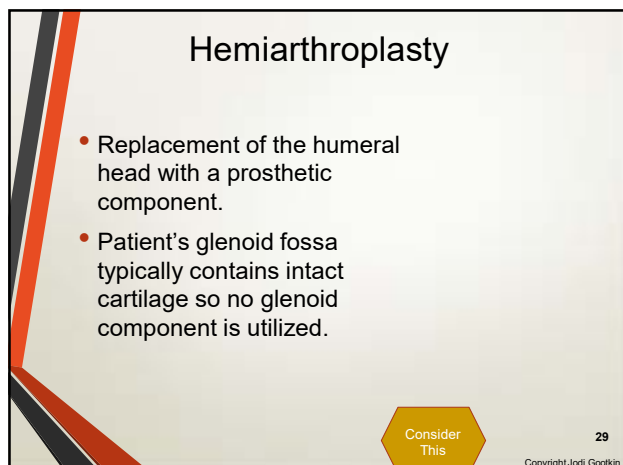
26



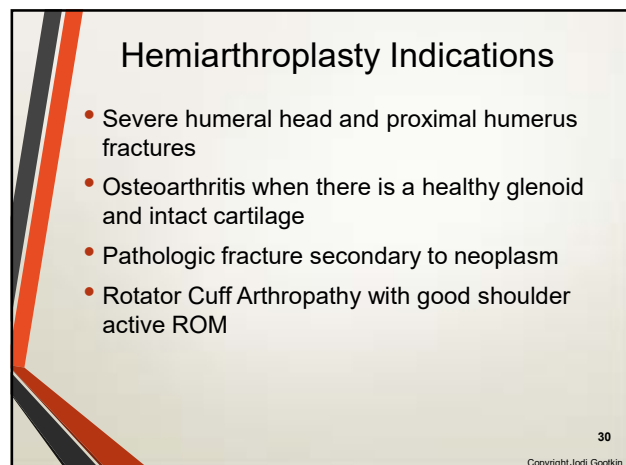
27



28



Shoulder Arthroplasty



30

Cuff Tear Arthroplasty (CTA)

- The prosthetic humeral head has an extended surface to articulate with the deteriorated glenoid fossa and coracoacromial arch.
- The glenoid component is not replaced.

Copyright Jodi Gootkin

32

31

Total Shoulder Arthroplasty Prosthetic Types

- The goal of prosthetic components is to reproduce joint mechanics and restore joint stability and muscle motor function.
- Integrity of rotator cuff is a major factor contributing to the prosthetic selection.

Anatomic Total Shoulder Arthroplasty (TSA)

- Neer
- Unconstrained Design
- Intact rotator cuff required

Reverse Shoulder Arthroplasty (RSA)

- Grammont
- Constrained design
- Deltoid strength required

Copyright Jodi Gootkin

32

32

Anatomic Total Shoulder Arthroplasty

- Also known as
 - Anatomic Total Shoulder Arthroplasty ATSA
 - **Total Shoulder Arthroplasty TSA**
 - Neer prosthesis
- Indicated for patients with an intact rotator cuff and
 - Osteoarthritis
 - Rheumatoid Arthritis
 - Post Traumatic Arthritis
 - Avascular Necrosis

33

Copyright Jodi Gootkin

33

Anatomic Total Shoulder Arthroplasty Prosthesis

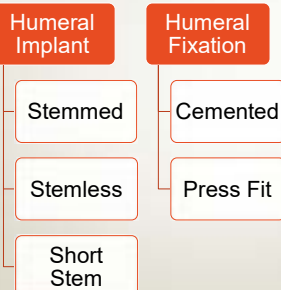
- Metal alloy humeral head with titanium humeral shaft and cross-linked polyethylene glenoid components replace damaged bone surfaces.

34

Copyright Jodi Gootkin

34

Humeral Components



35

Copyright Jodi Gootkin

Shoulder Arthroplasty

Glenoid Components

Metal Backed

Uncemented with screws

Monoblock platform with central trabecular surface

Combination

Metal trabecular surface with peripheral cement

All polyethylene

Uncemented fluted deep central peg with cemented peripheral pegs

36

Copyright Jodi Gootkin

36

Copyright Innovative Educational Services and Jodi Gootkin. All rights reserved.

Reproduction, reuse, or republication of all or any part of this presentation is strictly prohibited without prior written consent of both Innovative Educational Services and Jodi Gootkin.

TSA Unconstrained Prosthesis

- Must have intact rotator cuff as unconstrained design requires stability from native rotator cuff musculature for functional motion of the upper extremity.
- When the rotator cuff is not strong enough to stabilize the humeral head in the glenoid fossa, the deltoid is unopposed and cannot effectively elevate the extremity.

37

Copyright Jodi Gootkin

Reverse Shoulder Arthroplasty

- Also known as
 - **Reverse Shoulder Arthroplasty RSA**
 - Reverse Total Shoulder Arthroplasty rTSA
 - Reverse Shoulder Replacement RSR
 - Grammont Prosthesis
- Indicated for patients
 - Osteoarthritis WITHOUT an intact rotator cuff
 - Complex proximal humeral fractures
 - Rheumatoid Arthritis
 - Failed Anatomic Total Shoulder Arthroplasty or Hemiarthroplasty

38

Copyright Jodi Gootkin

Reverse Shoulder Prosthesis

- Glenohumeral articulation is inverted with the convex prosthesis attached to glenoid fossa and the concave component attached to humerus.
- The glenosphere is attached to a baseplate secured into the fossa by a large central peg and cortical screws.
- The humeral component is a cup shaped body attached to a metal stem that is press fitted or cemented into the humeral medullary canal.
- A polyethylene liner articulates the two components.

Consider This

39

Copyright Jodi Gootkin

Humeral Component Fixation

Cemented

- Acromial fractures
- Infection
- Nerve injury
- Thromboembolism

Uncemented

- Early humeral stem migration
- Non-progressive radiolucent lines

- Functional outcomes and range of motion equivalent with both uncemented and cemented RSA stems.

40

Phadnis, J., Huang, T., Watts, A., Krishnan, J., & Bain, G. I. (2016). Cemented or cementless humeral fixation in reverse total shoulder arthroplasty? a systematic review. *The bone & joint journal*, 98(1), 65-74.

Copyright Jodi Gootkin

Constrained Design

- The constrained mechanical design of the prosthesis provides joint stability with extremity motion in the absence of a functioning rotator cuff.
- The fixed center of humeral rotation is moved distal and medial in relation to glenoid surface.
 - Converts shear to compressive force

41

Copyright Jodi Gootkin

Fixed Fulcrum

- Creates fixed fulcrum at the glenoid for the humerus to rotate against allowing the deltoid to elevate the arm without impingement.
- Lengthening of the humerus in relation to the scapula enhances the moment arm of the deltoid to perform forward elevation and abduction.
- Prosthetic design allows arm elevation in the absence of a fully functioning rotator cuff.

42

Copyright Jodi Gootkin

Shoulder⁴¹ Arthroplasty

42

Copyright Innovative Educational Services and Jodi Gootkin. All rights reserved.

Reproduction, reuse, or republication of all or any part of this presentation is strictly prohibited without prior written consent of both Innovative Educational Services and Jodi Gootkin.

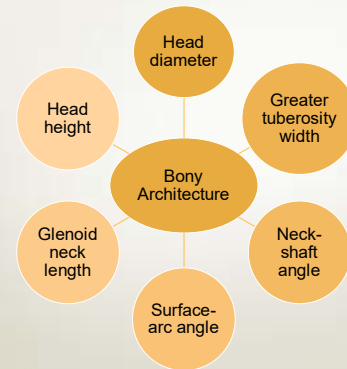
RSA Contraindications

- Axillary nerve damage
- Non-functioning deltoid muscle group
- Infection
- Neuropathic joints
- Inadequate glenoid bone stock

43

Copyright Jodi Gootkin

Surgical Considerations



44

Copyright Jodi Gootkin

Neck-Shaft Angle

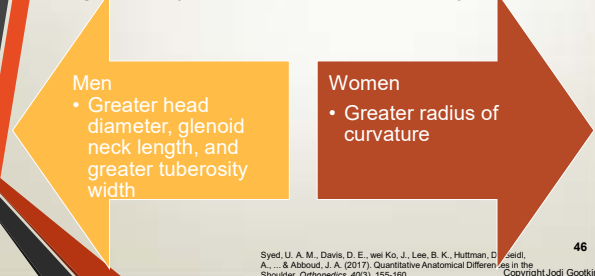
- Alteration of the angle between the humeral head and neck in the prosthetic design influences stability of the joint post operatively.
- Humeral component design creates a neck-shaft angle of 135 degrees.
- Increasing the angle to 155 degrees demonstrates higher instability rates of the new joint.

45

Copyright Jodi Gootkin

Male vs. Female Shoulder Anatomy

- Surgical alteration of shoulder articular surfaces by 4-5 mm compared to the native joint can significantly impact kinematics of the joint.



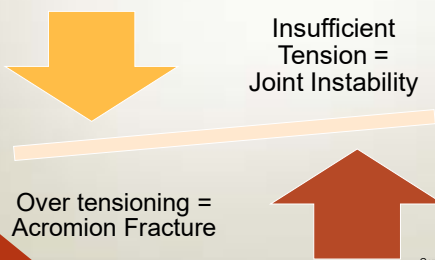
Syed, U. A. M., Davis, D. E., Wei Ko, J., Lee, B. K., Huttman, D., Seidi, A., ... & Abboud, J. A. (2017). Quantitative Anatomical Differences in the Shoulder. *Orthopedics*, 40(3), 155-160.

46

Copyright Jodi Gootkin

Deltoid Tensioning

- Significant pre-operative deltoid atrophy is associated with diminished functional achievements post surgery.



47

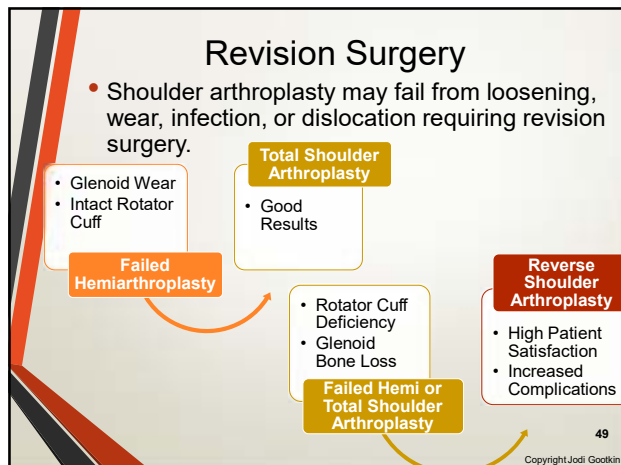
Copyright Jodi Gootkin

Component Fixation

- Limited bone stock may present a challenge to achieving fixation of glenoid component.
 - Locking screws with multi-axial designs and hydroxyapatite coatings aid in improving fixation.
- Some surgeons prefer impaction grafting with a humeral press fit component to reduce fracture risk.

48

Copyright Jodi Gootkin



49

Surgical approach

- The patient is positioned supine on operating table with head elevated 30 – 60 degrees in a “beach chair” position.
- The two primary surgical approaches are Deltopectoral and Anterosuperior

Copyright Jodi Gootkin

50

Deltopectoral Approach

- The incision begins slightly medial to acromioclavicular joint and extends distal passing coracoid toward deltoid insertion on lateral humerus.
- Deltoid is elevated with adhesions debrided.

Consider This

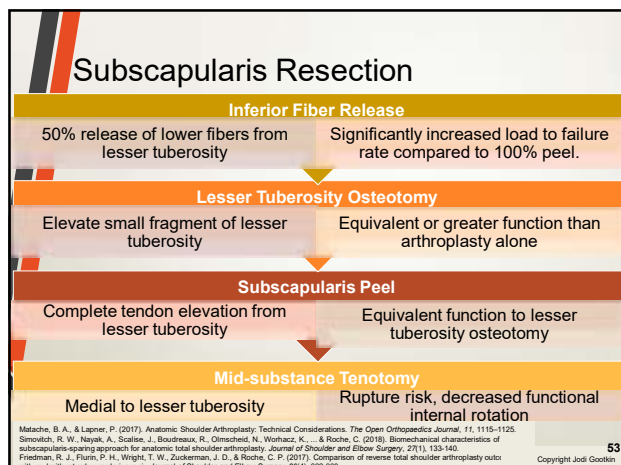
Copyright Jodi Gootkin

51

- Caution is taken to avoid injury to axillary nerve, musculocutaneous nerve and anterior circumflex vessels.
- The subscapularis must be resected to gain access to glenohumeral joint.

Copyright Jodi Gootkin

52



53

Shoulder Arthroplasty

Anterosuperior Approach

- Also referred to as the subscapularis sparing approach.
- A vertical incision near posterior margin of acromioclavicular joint descends to split the anterior and middle deltoid.
- The deltoid attachment along clavicle to acromion is released and retracted to expose the joint.

Copyright Jodi Gootkin

54

Copyright Innovative Educational Services and Jodi Gootkin. All rights reserved.

Reproduction, reuse, or republication of all or any part of this presentation is strictly prohibited without prior written consent of both Innovative Educational Services and Jodi Gootkin.

Concurrent Procedures

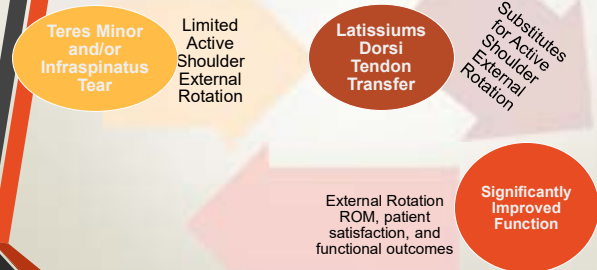
- Release of adhesions under the coracoid and glenohumeral ligament allows mobilization of rotator cuff tendons to reduce the risk of injury.
- Debridement and/or partial or complete rotator cuff repair may improve outcomes in some patients.
- Bone grafting may be utilized for severe glenoid bone loss due to osteoarthritis.

55

Copyright Jodi Gootkin

55

Latissimus Dorsi Tendon Transfer



56

Copyright Jodi Gootkin

56

Long Head of Biceps Tendon(LHBT) Tenodesis

LHBT tenodesis is indicated in patients with chronic atrophic changes, tendon rupture, and routinely performed by some surgeons in absence of obvious tendonopathy.

Tenodesis is performed with resection of the proximal tendon and resuturing to the insertion of the pectoralis major near the intertubercular groove.

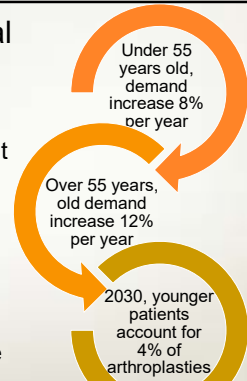
57

Copyright Jodi Gootkin

57

Acute Post Surgical Management

- As future demand increases, management of perioperative factors that influence hospital length of stay can increase discharge disposition to home, improve functional outcomes, and manage health care costs.



Padeigimas, E. M., Matterfort, M., Lazarus, M. D., Ramsey, M. L., Williams, G. R., & Namdari, S. (2015). Future patient demand for shoulder arthroplasty by younger patients: national projections. *Clinical Orthopaedics and Related Research*, 473(3), 1860-1867.

58

Copyright Jodi Gootkin

58

Patient education

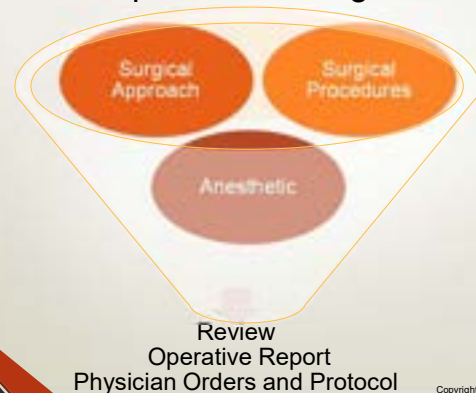- Preoperative education should focus on pain self-management, activities of daily living training, donning/doffing sling, and mobility in addition to patient expectations of recovery.

59

Copyright Jodi Gootkin

Shoulder Arthroplasty

Post Operative Management



60

Copyright Jodi Gootkin

60

Copyright Innovative Educational Services and Jodi Gootkin. All rights reserved.

Reproduction, reuse, or republication of all or any part of this presentation is strictly prohibited without prior written consent of both Innovative Educational Services and Jodi Gootkin.

Surgical Drain

- Some physicians opt to insert a drain prior to closure of the surgical incision to minimize the risk of hematoma formation.
- Typically removed post-operative day 1 when drainage is less than 30mL.

61

Copyright Jodi Gootkin

61

Pain Management

Peripheral Nerve Block (PNB)

- Intraoperative interscalene or supraclavicular injection

Patient Controlled Analgesia (PCA)

- Patient dispensed at preset dosage

Intraoperative Injections

- Periarticular injection of extended-release liposomal bupivacaine

62

Copyright Jodi Gootkin

62

Interscalene and Supraclavicular PNB Side Effects

Horner's Syndrome

- Myosis
- Ptosis
- Anhidrosis

Bezold-Jarisch Reflex

- Bradycardia
- Hypotension

Recurrent Laryngeal Nerve Block

- Hoarseness

Diaphragmatic Hemiparesis

- Decreased Respiratory Capacity

Hand Motor Block

- Decreased Grip Strength

63

Copyright Jodi Gootkin

63

Tobacco Use and Pain Management

- Current tobacco use is associated with a more challenging post-operative course.
 - Higher perceived pain scores
 - Greater narcotic pain medication consumption
 - Slightly longer hospital length of stay

Wells, D. B., Holt, A. M., Smith, R. A., Breslin, T. J., Azar, F. M., & Throckmorton, T. W. (2018). Tobacco use predicts a more difficult episode of care after anatomic total shoulder arthroplasty. *Journal of shoulder and elbow surgery*, 27(1), 23-28.

64

Copyright Jodi Gootkin

64

Breathing Exercises

- In addition to reducing the risk of atelectasis and pneumonia, breathing exercises emphasizing postural alignment can assist in reducing protective muscle spasms.

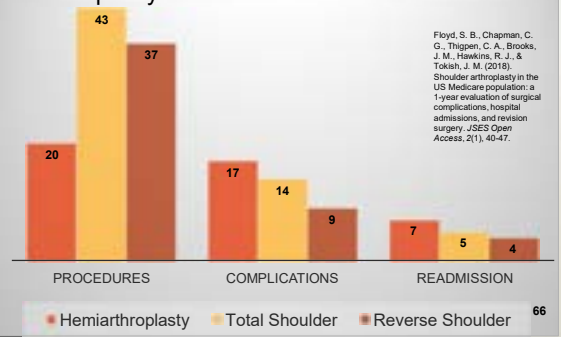
65

Copyright Jodi Gootkin

Shoulder Arthroplasty

Complications

- Revision arthroplasty demonstrates greater complication rates compared to primary arthroplasty.

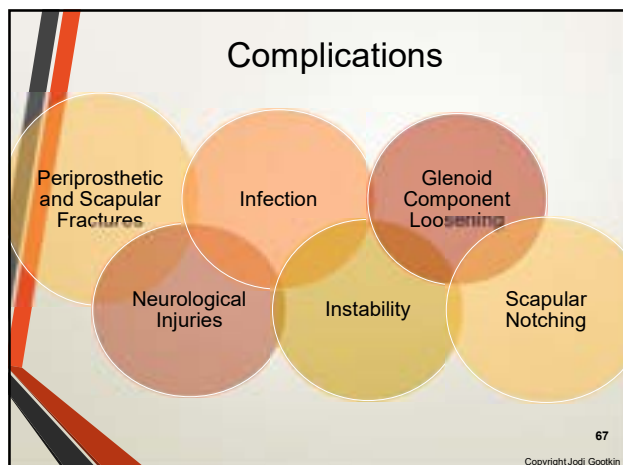


66

66

Copyright Innovative Educational Services and Jodi Gootkin. All rights reserved.

Reproduction, reuse, or republication of all or any part of this presentation is strictly prohibited without prior written consent of both Innovative Educational Services and Jodi Gootkin.



67

Periprosthetic Fractures

- Over reaming of a glenoid that has minimal sclerosis can result in fracture and instability of the component fixation.
- Tuberosity and shaft fractures may be accommodated by altering stem length.

68
Copyright Jodi Gootkin

68

Scapular Fractures

- Acromion fractures may occur at the base of the spine of the scapula or through the acromion.
- May result from pre-operative deterioration of the acromion from superior humeral head translation or pseudoparalysis combined with over tensioning of the deltoids during repair.

69
Copyright Jodi Gootkin

69

Infection

- Higher infection rates occur with the RSA potentially due to greater unoccupied joint space post prosthetic implant.
- Common pathogens are Propionobacterium acnes and Staphylococcus.
- Increased incidence of infections in patients with rheumatoid arthritis, diabetes mellitus, history of oral steroid use, shoulder trauma, smoking or failed shoulder hemiarthroplasty.

70
Copyright Jodi Gootkin

70

Infection Diagnosis

Patient Symptoms

- Pain
- Stiffness
- Fever
- Night sweats
- Chills

Clinical Signs

- Draining sinus
- Erythema
- Effusion

Diagnostic Testing

- Arthrography and culture
- Radiographic changes
- Serologic markers

71
Copyright Jodi Gootkin

Shoulder Arthroplasty

Neurological Injuries

- Intraoperative nerve injury may result from cement thermal reaction or over penetration of glenoid baseplate screws.
- Lengthening of the upper extremity greater than 2 cm may increase risk of nerve injury.

72
Copyright Jodi Gootkin

72

Neurological Injuries Clinical Presentation

- Post-operative assessment should distinguish sensory changes originating from the healing incision and tissues from neuropraxia.

Nerve	Motor	Sensory
Musculocutaneous	Biceps Brachialis Coracobrachialis	Lateral Forearm
Axillary	Deltoids	Lateral Shoulder
Suprascapular	Supraspinatus Infraspinatus	Posterior Superior Scapula
Radial	Triceps Wrist Extensors	Posterior Distal Arm, Posterior Forearm, Dorsum of Hand Thumb Side

73

Copyright Jodi Gootkin

73

Instability

- Instability can occur with both types of arthroplasty.
- Surgical technique and prosthetic design factors contribute to dislocation risk.

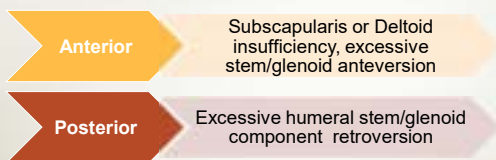Patient Risk Factors	Surgical Risk Factors
<ul style="list-style-type: none"> BMI > 30 Male Gender Previous Surgery 	<ul style="list-style-type: none"> Inadequate Deltoid Tensioning Malpositioned Implants Mechanical Impingement Subscapularis Deficiency Deltopectoral Approach Axillary Nerve Injury

74

Copyright Jodi Gootkin

74

Instability



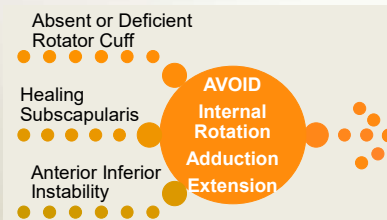
- Conservative management with closed reduction is often successful, but recurrent instability may require revision surgery.

75

Copyright Jodi Gootkin

75

Joint Protection



- No glenohumeral extension beyond neutral

76

Copyright Jodi Gootkin

76

Post Operative Immobilization

- Immobilization balances optimizing healing of the tendon bone interface with avoiding stiffness.
- Subscapularis protection is critical for healing of the tendon reattachment and to avoid joint subluxation.

Deltopectoral Approach and Rotator Cuff Repair Sling up to 6 weeks

Subscapularis Sparing Approach Earlier Weaning for ROM

Consider This

77

Copyright Jodi Gootkin

Shoulder Arthroplasty

Shoulder Sling

- Patient and family education should emphasize correct donning procedure and alignment to ensure alignment of upper extremity in neutral extension with scapular retraction avoiding excessive cervical stress.
- RSA will use abduction pillow along with sling.

78

Copyright Jodi Gootkin

78

Copyright Innovative Educational Services and Jodi Gootkin. All rights reserved.

Reproduction, reuse, or republication of all or any part of this presentation is strictly prohibited without prior written consent of both Innovative Educational Services and Jodi Gootkin.

Positioning

- In supine add support behind shoulder for humerus to remain neutral aligned with trunk.
 - 10-20 degrees of forward flexion, slight ABDuction and internal rotation
 - Head of bed elevated 30-60 degrees
- In sitting arm supported in sling or on pillow in lap with elbow visible.

79

Copyright Jodi Gootkin

79

Mobility Precautions

- Early Rehab
 - Avoid combination of active or passive shoulder internal rotation, ADDuction, extension
 - No pushing, pulling, lifting
- Later Rehab
 - Avoid combination of active shoulder ABDuction above 80 degrees and external rotation

80

Copyright Jodi Gootkin

80

Glenoid Component Loosening

- Loosening of the glenoid component is the most common long term complication associated with TSA as a consequence of the unconstrained design combined with a deficient rotator cuff.
- The shallow glenoid migrates and loosens against the unopposed force of the deltoid contraction.
- Additional contributing factors:
 - Eroded or medialized glenoid
 - Component malposition that increases stress forces
 - Excessive reaming reducing bone stock
 - Underlying infection
 - Rotator cuff tear
 - Instability

Consider This

81

Copyright Jodi Gootkin

81

Rocking Horse Phenomena

- In the TSA, with shoulder flexion and abduction the point of contact of the humeral head in the glenoid fossa shifts superiorly.
- Without accurate glenoid prosthetic orientation and sufficient rotator cuff strength the glenoid baseplate undergoes eccentric loading.

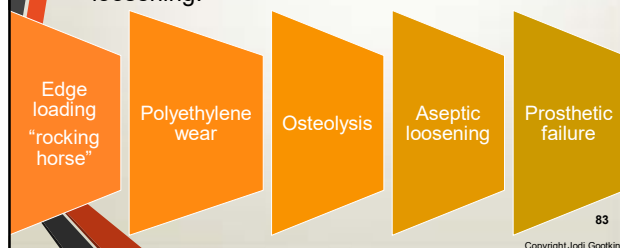82

Copyright Jodi Gootkin

82

Aseptic Loosening

- Poor implant alignment, rotator cuff dysfunction, and humeral head instability contribute to loosening.



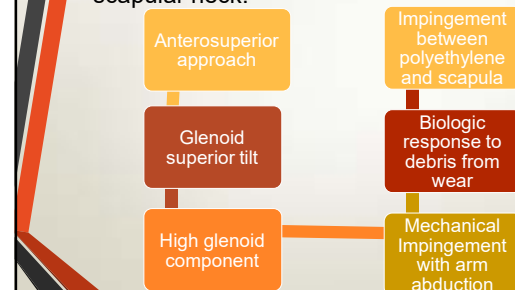
83

Copyright Jodi Gootkin

Shoulder Arthroplasty

Scapular Notching

- Over time following RSA, humeral component impingement causes erosion of the inferior scapular neck.



84

Copyright Jodi Gootkin

84

Copyright Innovative Educational Services and Jodi Gootkin. All rights reserved.

Reproduction, reuse, or republication of all or any part of this presentation is strictly prohibited without prior written consent of both Innovative Educational Services and Jodi Gootkin.

Scapular Notching Implications

Does not impact clinical outcomes and is not prognostic of function.

May lead to baseplate failure and worse clinical outcomes.

Smith, C. D., Guyver, P., & Bunker, T. D. (2012). Indications for reverse shoulder replacement: a systematic review. *The Journal of bone and joint surgery, British volume*, 94(5), 577-583.
 Famillari, F., Rojas, J., Nedim Dorzi, M., Huri, G., & McFarland, E. G. (2018). Reverse total shoulder arthroplasty. *EFORT open reviews*, 3(2), 58-69.
 Singhal, K., & Ramnathan, R. (2018). Going forward with reverse shoulder arthroplasty. *Journal of Clinical Orthopaedics & Trauma*, 9(1), 87-93.
 Favard, L., Lavigne, C., Nerot, C., Gerber, C., De Wilde, L., & Moia, D. (2011). Reverse Prostheses in Arthroplasties With Cuff Tear: Are Survivorship and Function Maintained Over Time? *Clinical Orthopaedics and Related Research*, 469(9), 2469-2475.

CopyrightJodi Gootkin

85

Rehabilitation

Arthro-kinematics

Rehab Phases

Functional Progression

Return to Sport and Work

Outcome Assessment

CopyrightJodi Gootkin

86

Post Operative Arthrokinematics

- The goal of reconstruction is to replicate normal articular anatomy restoring soft tissue length tension relationships, kinematics, and function.

CopyrightJodi Gootkin

87

Kinematic Analysis of Motion

- Scapulohumeral rhythm is typically reduced with the overall scapular kinematic pattern preserved.
- The patient may substitute with increased scapular motion to compensate for decreased glenohumeral mobility for the performance of activities of daily living.

CopyrightJodi Gootkin

88

Range of Motion Expectations

- Full ROM is NOT expected** upon discharge from rehabilitation.
- Upon discharge from therapy most patients achieve approximately 80-120 degrees flexion and 30 degrees external rotation.

Smith, C. D., Guyver, P., & Bunker, T. D. (2012). Indications for reverse shoulder replacement: a systematic review. *The Journal of bone and joint surgery, British volume*, 94(5), 577-583.
 Favard L., Lavigne C., Nerot C et al., Reverse prostheses in arthroplasties with cuff tear: Are survivorship and function maintained over time? *Clin Orthop Relat Res* 2011;469:2469-75.
 Famillari, F., Rojas, J., Nedim Dorzi, M., Huri, G., & McFarland, E. G. (2018). Reverse total shoulder arthroplasty. *EFORT Open Reviews*, 3(2), 58-69.
 Chun YM, Kim DS, Lee DH, Shin SJ. Reverse shoulder arthroplasty for four-part proximal humerus fracture in elderly patients: Can a healed tuberosity improve the functional outcomes? *J Shoulder Elbow Surg* 2017;26:1216-21
 Sanchez-Sotelo, J., Nguyen, N. T. V., & Morrey, M. (2018). Anatomic Total Shoulder Arthroplasty Using a Self-Pressurizing Pegged Bone-Preserving Cemented Glenoid Component: A 2-to 5-Year Follow-up Study. *Journal of Shoulder and Elbow Arthroplasty*, 2, 2471549217750478.

Consider This

CopyrightJodi Gootkin

89

Shoulder Arthroplasty

ROM Continued

Procedure	Outcomes
Severe fracture	Abduction 90*-100*, poor internal rotation, significant variance in external rotation
Major rotator cuff tear	Elevation improved from 71* to 130*
Irreparable rotator cuff deficiency	Improved anterior elevation from 42* to 100*, abduction 43* to 90*
Acute proximal humerus fractures	Abduction limited to 90*-100* ER/IR varied
Osteoarthritis	Mean 154* elevation, 18* ER, IR to T10

Smith, C. D., Guyver, P., & Bunker, T. D. (2012). Indications for reverse shoulder replacement: a systematic review. *The Journal of bone and joint surgery, British volume*, 94(5), 577-583.
 Favard L., Lavigne C., Nerot C et al., Reverse prostheses in arthroplasties with cuff tear: Are survivorship and function maintained over time? *Clin Orthop Relat Res* 2011;469:2469-75.
 Famillari, F., Rojas, J., Nedim Dorzi, M., Huri, G., & McFarland, E. G. (2018). Reverse total shoulder arthroplasty. *EFORT Open Reviews*, 3(2), 58-69.
 Chun YM, Kim DS, Lee DH, Shin SJ. Reverse shoulder arthroplasty for four-part proximal humerus fracture in elderly patients: Can a healed tuberosity improve the functional outcomes? *J Shoulder Elbow Surg* 2017;26:1216-21
 Sanchez-Sotelo, J., Nguyen, N. T. V., & Morrey, M. (2018). Anatomic Total Shoulder Arthroplasty Using a Self-Pressurizing Pegged Bone-Preserving Cemented Glenoid Component: A 2-to 5-Year Follow-up Study. *Journal of Shoulder and Elbow Arthroplasty*, 2, 2471549217750478.

Consider This

CopyrightJodi Gootkin

90

Copyright Innovative Educational Services and Jodi Gootkin. All rights reserved.

Reproduction, reuse, or republication of all or any part of this presentation is strictly prohibited without prior written consent of both Innovative Educational Services and Jodi Gootkin.

RSA Strength

Medialization
increases
deltoid
moment arm

+

Distalization
increases
deltoid
resting tone

=

Improved
Deltoid
mechanical
advantage

- Non-anatomic design reduces ability of subscapularis and teres minor (if intact) to perform rotation.
- Latissimus dorsi tendon transfer can improve external rotation strength.

91
Copyright Jodi Gootkin

91

Rehabilitation Phases

- Progression must be based on clinical findings not timeframes and consider concomitant rotator cuff repair, biceps tenodesis, latissimus dorsi transfer, subscapularis reattachment, and humeral fracture healing.
- **Communication with the physician** regarding the patient's risk factors for complications can assist the clinician in progressing the patient.

92
Copyright Jodi Gootkin

92

Rehabilitation Protocols

Timelines & Interventions Vary
Follow the Physician Protocol

RSA
Progression
is typically
slower

93
Copyright Jodi Gootkin

93

Sample Phases

Phase I: Start Pos-op Day 1	Phase II: Start 4 Weeks	Phase III: Start 6 Weeks	Phase IV: Start 12 Weeks
<ul style="list-style-type: none"> • Allow tissue healing • Maintain new joint integrity • Increase shoulder PROM • Restore elbow/wrist/h and AROM • Reduce pain, inflammation • ADL Modification 	<ul style="list-style-type: none"> • Restore arthrokinematics, muscle balance, and motor control • Restore full PROM • Restore AROM • Control pain, inflammation • Activity Retraining 	<ul style="list-style-type: none"> • Restore shoulder strength, power, and endurance • Optimize neuromuscular control • Return to functional activities with operative extremity 	<ul style="list-style-type: none"> • Maintain AROM • Enhance functional use of operative extremity • Improve shoulder strength, power, and endurance • Progress weight bearing exercises

94
Copyright Jodi Gootkin

94

Sample Phase 1 Precautions

Wear Sling
Ask for help with activities
Always be able to see elbow with positioning

Avoid shoulder AROM
No driving
Avoid sudden movements especially rotation
No combined shoulder internal rotation, extension, and adduction
No lifting, pulling, pushing objects
No supporting of body weight by hand on the operative side
Keep incision clean and dry

95
Copyright Jodi Gootkin


Shoulder Arthroplasty

Sample Phase I : Begins POD 1

- Patient education joint protection and positioning
- PROM
 - Forward flexion in supine to tolerance
 - ER in scaption
 - IR to chest
- AROM elbow, hand, wrist, and forearm
- Pendulum exercise
- Scapular setting
- Cryotherapy

96
Copyright Jodi Gootkin

96




Scaption

- Motion of the glenohumeral joint occurring in the plane of the scapula that enhances shoulder alignment.
 - 30 degrees shoulder ABDuction and forward flexion with neutral rotation.

97

Copyright Jodi Gootkin



Scapular Strengthening

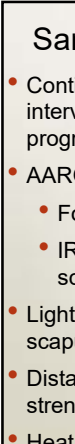
- Emphasizing alignment and quality motion of the scapula is the foundation for glenohumeral motion.
 - Rhomboids
 - Upper/middle/lower trapezius
 - Latissimus dorsi

98

Copyright Jodi Gootkin

97

98




Sample Late Phase I

- Continue Early Phase I interventions with progressive PROM
- AAROM
 - Forward flexion
 - IR/ER/Elevation in scaption
- Light pain free shoulder and scapular isometrics in neutral
- Distal upper extremity strengthening
- Heat and cryotherapy

99

Copyright Jodi Gootkin



Dynamic Hug


- Caution should be taken when strengthening internal rotation as the subscapularis tenotomy or osteotomy is healing.
- While the entire subscapularis activates with internal rotation, the upper and lower portions of are now recognized as having individual innervations and actions.

100

Copyright Jodi Gootkin

99

100




Sample Phase II: Begins at 4 Weeks

Criteria for progression: PROM at least

- 45° - 90° Forward flexion and elevation in scaption
- 20° - 45° ER in scaption or at side
- 70° IR in scaption at 30 ABDuction

Precautions




- Wean sling use
- Position to always see elbow
- Don't overdo it now that motion is pain free
- Ask for help with activities

- Avoid shoulder AROM against gravity in standing
- No pushing up in bed or from a chair
- No supporting body weight by hand on operative side
- No lifting anything heavier than glass of water
- No reaching across or behind your body
- No sudden jerking movements

101

Copyright Jodi Gootkin



Sample Phase II

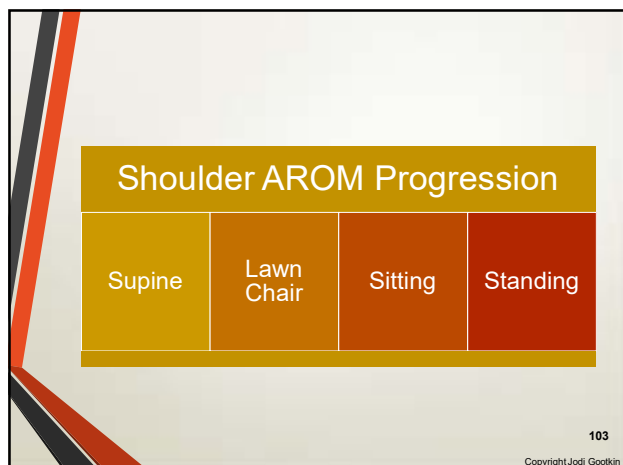
- Continue P/AAROM shoulder
- Pain free AROM Flexion, IR/ER/elevation in scaption
- Overhead pulley flexion and elevation in scaption
- Distal upper extremity strengthening with light resistance
- Gentle scapulothoracic mobilizations
- Scapular strengthening
- Submaximal shoulder and scapular isometrics
- Cryotherapy

102

Copyright Jodi Gootkin

Shoulder Arthroplasty

102



103

Sample Phase III: Begins at 6 Weeks

Criteria for progression: PROM in scaption at least

- 120° -140° Forward flexion and elevation
- 40° -60° ER
- 70° IR at 30 ABDuction
- 100° Active against gravity elevation with good mechanics

Precautions

✚

Wean from sling completely
Utilize operative extremity for light functional tasks

No heavy lifting objects over 6 pounds
No sudden lifting or pushing activities
No sudden jerking motions

104
Copyright Jodi Gootkin

104

Sample Early Phase III

- Progress shoulder AROM
- Advance PROM to stretching
- Resisted shoulder ER in scapular plane
- Begin endurance training

105
Copyright Jodi Gootkin

105

Sample Late Phase III

- Progressive scapular strengthening
- A/AROM shoulder internal rotation behind back and extension
- Supine shoulder flexion with light resistance
- Theraband shoulder flexion and elevation in scaption
- Check with physician on shoulder extension and internal rotation

106
Copyright Jodi Gootkin

106

Sample Phase IV: Begins at 12 Weeks

Criteria for progression:

- AROM At least
 - 140° Forward flexion
 - 120° ABDuction
 - 60° ER in scaption
 - 70° IR in scaption at 30 ABD
- 100°- 120° Active against gravity shoulder elevation with good mechanics

Precautions

✚

Gradually progress strengthening

Avoid functional activities stressing anterior capsule

107
Copyright Jodi Gootkin

107

Sample Phase IV

- End ROM stretching
- Progressive strengthening
- Return to moderately challenging functional activities and recreation

108
Copyright Jodi Gootkin

108

Shoulder Arthroplasty

Copyright Innovative Educational Services and Jodi Gootkin. All rights reserved.

Reproduction, reuse, or republication of all or any part of this presentation is strictly prohibited without prior written consent of both Innovative Educational Services and Jodi Gootkin.

Exercises to Avoid

- Horizontal extension, ABDuction and external rotation combination

Copyright Jodi Gootkin

109

109

Discharge from Therapy

- Maintain non-painful full AROM
- Restored use of upper extremity for advanced functional activities
- Maximized strength, power, and endurance

Copyright Jodi Gootkin

110

110

Functional Outcomes

Follow-up time frame	Procedure	Outcome
5 years	RSA	All Constant scores improved AROM forward elevation and ER improved
3 years	TSA	Able to perform combing hair, washing opposite armpit, tying apron, taking book from shelf using less flexion and abduction compared to controls.
1 year	RSA	

Favard, L., Lewigne, C., Nerot, C., Gerber, C., De Wilde, L., & Mole, D. (2011). Reverse Prostheses in Arthroplasties With Cuff Tear: Are Survivorship and Function Maintained Over Time? *Clinical Orthopaedics and Related Research*, 459(9), 2469-2475.
 Maier, M. W., Niklasch, M., Dreher, T., Zeifang, F., Rettig, O., Klotz, M. C., ... & Kasten, P. (2014). Motion patterns in activities of daily living: 3-year longitudinal follow-up after total shoulder arthroplasty using an optical 3D motion analysis system. *BMC musculoskeletal disorders*, 15(1), 244.
 Maier, M. W., Caspers, M., Zeifang, F., Dreher, T., Klotz, M. C., Wolf, S. I., & Kasten, P. (2014). How does reverse shoulder replacement change the range of motion in activities of daily living in patients with cuff tear arthropathy? A prospective optical 3D motion analysis study. *Archives of orthopaedic and trauma surgery*, 134(8), 1065-1071.

111

Copyright Jodi Gootkin

111

Activities of Daily Living (ADLs)

- During early rehab, encourage self care by providing dressing and hygiene instruction and reassurance of performance that protects the healing tissues.
- One handed donning and doffing of button-up shirt one to two sizes larger than usual size.
- Seated donning of elastic waist loose bottom pants/shorts using dressing stick.
- Pop-top toothpaste, pump soap and shampoo dispensers.

Copyright Jodi Gootkin

112

112

Hygiene and Toileting

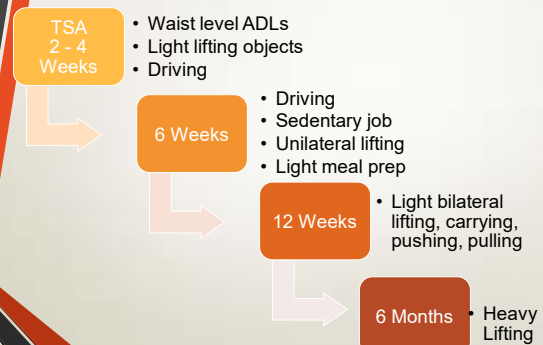- Washing underarm and torso on surgical side can be performed using Codman's position or by placing hand of operative arm gently in closed chain position on stable counter/sink at 30*-45* degrees of forward flexion or scaption.
- Raised toilet seat, commode over toilet, or grab bar on non-operative side assists with sit to stand.

113

Copyright Jodi Gootkin

Shoulder Arthroplasty

TSA Functional Progression



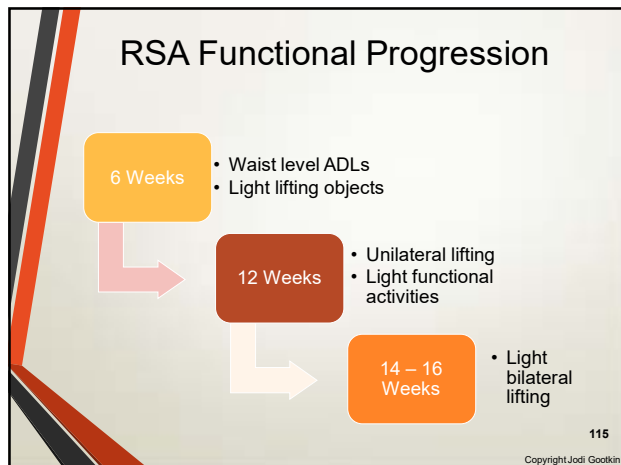
Copyright Jodi Gootkin

114

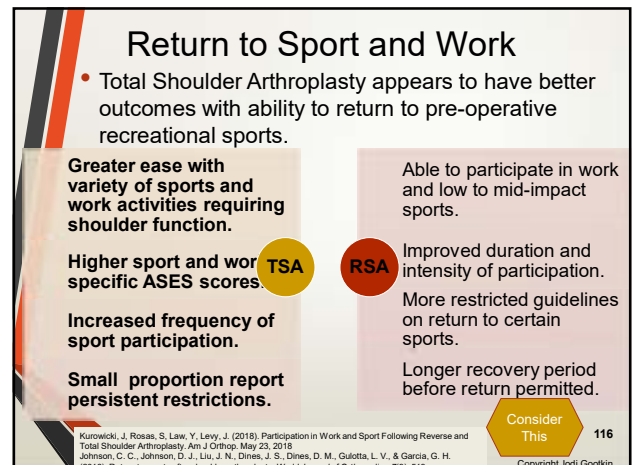
114

Copyright Innovative Educational Services and Jodi Gootkin. All rights reserved.

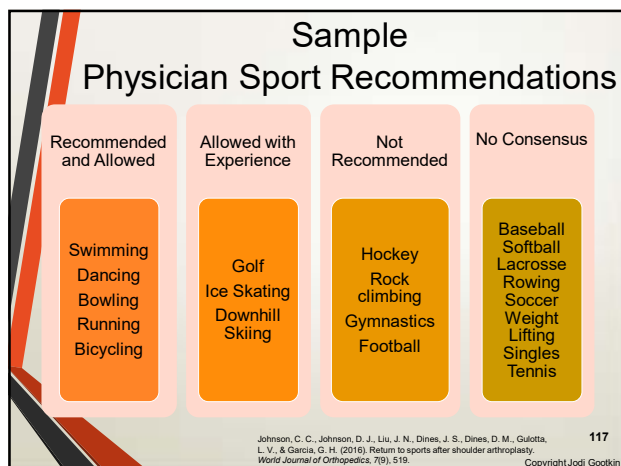
Reproduction, reuse, or republication of all or any part of this presentation is strictly prohibited without prior written consent of both Innovative Educational Services and Jodi Gootkin.



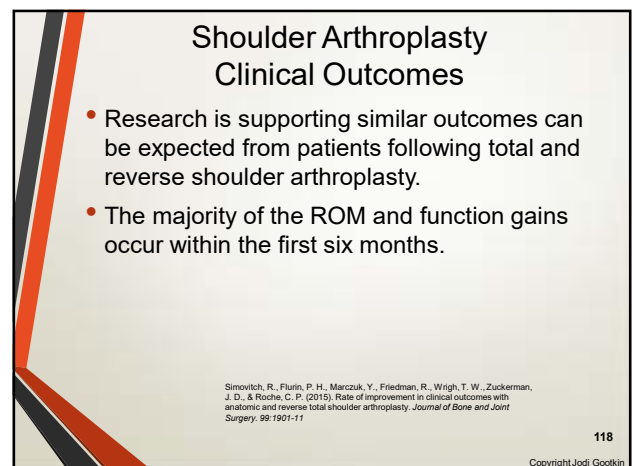
115



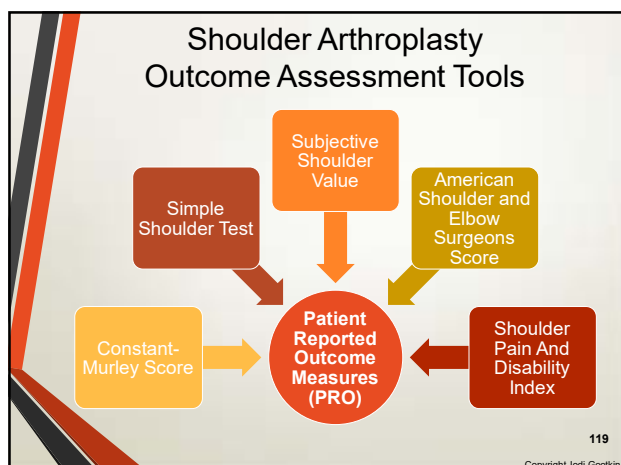
116



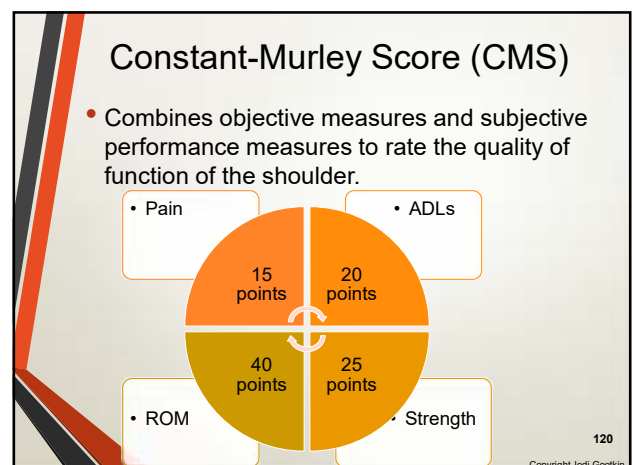
117



118



Shoulder Arthroplasty



120

Copyright Innovative Educational Services and Jodi Gootkin. All rights reserved.

Reproduction, reuse, or republication of all or any part of this presentation is strictly prohibited without prior written consent of both Innovative Educational Services and Jodi Gootkin.

Simple Shoulder Test (SST)

- Reflecting on past week, patient answers yes/no questions regarding shoulder comfort and function.
- Minimal Clinically Important Difference (MCID) for shoulder arthroplasty is 3 points.

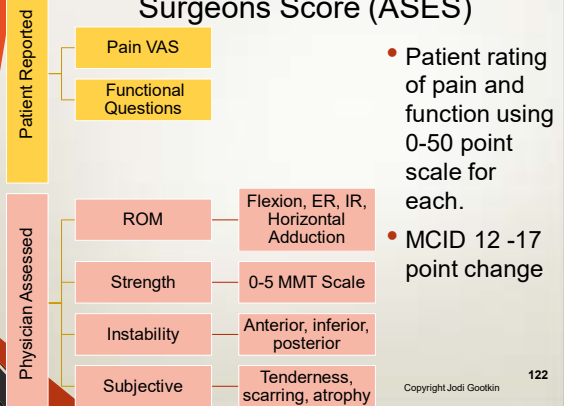
Roy, J. S., Macdermid, J. C., Faber, K. J., Drosdowech, D. S., & Athwal, G. S. (2010). The simple shoulder test is responsive in assessing change following shoulder arthroplasty. *Journal Of Orthopaedic & Sports Physical Therapy*, 40(7), 413-421.

121

Copyright Jodi Gootkin

121

American Shoulder and Elbow Surgeons Score (ASES)



122

Copyright Jodi Gootkin

122

Shoulder Pain And Disability Index (SPADI)

- Patient ranking on 0 to 10 scale of pain level with specific activities and difficulty with ADLs.
- Pain and Disability scores total to 130 with a score of 0 indicating no disability or pain.

123

Copyright Jodi Gootkin

123

Subjective Shoulder Value (SSV)

- This tool is an example of a Single Assessment Numeric Evaluation (SANE).

On a scale of 0% -100% where 0% is abnormal and 100% is normal, how would you rate your shoulder?



Sabesan, V. J., Lombardo, D. J., Khan, J., & Wister, J. M. (2015). Assessment of the optimal shoulder outcome score for reverse shoulder arthroplasty. *Journal of Shoulder and Elbow Surgery*, 24(10), 1653-1659.

124

Copyright Jodi Gootkin

124

Prosthetic Survival

- Implants are surviving at short and midterm follow-up with assessment of long term durability and longevity needed.
- Historical use of shoulder arthroplasty in patients of advanced age with advanced arthritis and irreparable rotator cuff tears limits the research cohort for long term studies as patients often outlive the prosthesis.

Bacle, G., Nové-Josserand, L., Garaud, P., & Walch, G. (2017). Long-term outcomes of reverse total shoulder arthroplasty: a follow-up of a previous study. *JBJS*, 99(6), 454-461.

125

Copyright Jodi Gootkin

Shoulder Arthroplasty

Research Considerations

- Retrospective analysis of patients undergoing shoulder arthroplasty between 1990 and 2015 concludes that more specific study analyzing specific patient data is necessary to determine if outcomes are improving as prosthetic design and surgical technique advances.

Procedure	Studies	Cohort Size	Follow-up
TSA	42 studies	20- 705 patients	3-5 years
RSA	37 studies	20-174 patients	4-5 years

Somerson, J. S., Neradilek, M. B., Hsu, J. E., Gee, A. O., & Matsen, F. A. (2017). Is there evidence that the outcomes of primary anatomic and reverse shoulder arthroplasty are getting better? *International Orthopaedics*, 41(8), 1235-1244.

126

Copyright Jodi Gootkin

126

Copyright Innovative Educational Services and Jodi Gootkin. All rights reserved.

Reproduction, reuse, or republication of all or any part of this presentation is strictly prohibited without prior written consent of both Innovative Educational Services and Jodi Gootkin.

RSA Long Term Outcomes

Cohort	Outcome
Initial: 186 patients followed 40 months	Midterm: Increased Constant Score and Anterior Elevation
Follow-up: 84 patients followed 150 months	Long term: Overall prosthetic survival 93% 73% scapular notching Greater degradation of function in patients who had surgery prior to age 76

Bacle, G., Nové-Josserand, L., Garaud, P., & Walch, G. (2017). Long-term outcomes of reverse total shoulder arthroplasty: a follow-up of a previous study. *JBJS*, 99(6), 454-461.

Copyright Jodi Gootkin

127

Rotator Cuff Tear Outcomes

- Long term high functional outcome scores associated with RSA in young patients with rotator cuff arthropathy.

Population	Outcome
Previous Rotator Cuff Repair	Lower ASES score, higher pain score, less ROM improvement
Younger patients	Excellent clinical improvement, high 12 year survivorship
506 patients	89% survivorship free of revision at 10 years with minimal functional deterioration
Under 60 years old	Significant ROM, pain and strength improvement without deterioration

Shields, E. J., Koueiter, D. M., Maerz, T., Schwark, A., & Wiater, J. M. (2017). Previous Rotator Cuff Repair Is Associated With Inferior Clinical Outcomes After Reverse Total Shoulder Arthroplasty. *Orthopaedic Journal of Sports Medicine*, 5(10), 2325967117730311.
Familar, F., Rojas, J., Nedim Doral, M., Huri, G., & McFarland, E. G. (2018). Reverse total shoulder arthroplasty. *EFORT Open Reviews*, 3(2), 58-69.
Favard, L., Leveigne, C., Nerot, C., Gerber, C., De Wilde, L., & Mole, D. (2011). Reverse Prosthesis in Arthroplasties With Cuff Tear: Are Survivorship and Function Maintained Over Time? *Clinical Orthopaedics and Related Research*, 469(9), 2469-2475.
Ernstbrunner, L., Suter, A., Catanzaro, S., Rahm, S., & Gerber, C. (2017). Reverse Total Shoulder Arthroplasty for Massive, Irreparable Rotator Cuff Tears Before the Age of 60 Years: Long-Term Results. *JBJS*, 99(20), 1721-1729.

Copyright Jodi Gootkin

128

Post Traumatic Outcomes

Diagnosis	Procedure	Outcome
38 patients with previous ORIF for fracture	RSA	Constant score improved from 25* to 57* Shoulder forward elevation increased from 73* to 117* degrees
23 patients with displaced proximal humeral fracture	ORIF with Plate and screws or RSA	Good clinical outcomes and fewer complications in both. Better ADL results with RSA.
Systematic review of patients with complex proximal humeral fracture	Hemiarthroplasty or RSA	Constant score, ASES score, ROM similar. Greater complications with RSA.

Rais, P., Alami, G., Bruckner, T., Magosch, P., Habermeyer, P., Boileau, P., & Walch, G. (2018). Reverse shoulder arthroplasty for type 1 sequelae of a fracture of the proximal humerus. *Bone Joint J*, 100(3), 318-323.
Giardella, A., Ascione, F., Mocchi, M., Berlusconi, M., Romano, A. M., Oliva, F., & Maradei, L. (2017). Reverse total shoulder versus angular stable plate treatment for proximal humeral fractures in over 65 years old patients. *Muscles, Ligaments and Tendon Journal*, 7(2), 271.
Namdari, S., Homeff, J. G., & Baldwin, K. (2013). Comparison of hemiarthroplasty and reverse arthroplasty for treatment of proximal humeral fractures: a systematic review. *JBJS*, 95(18), 1701-1708.

Copyright Jodi Gootkin

129

Patient Satisfaction

Procedure and Population	Satisfaction
TSA Patients under 50	95% at 5 years
Hemiarthroplasty Patients under 50	71% at 5 years
TSA for Osteoarthritis	Mean 10/10 at 3 years
RSA for Rotator Cuff Arthropaty	90% at 4 years
RSA Workers Compensations Patients	57% at 2 years
RSA Non-workers Compensation Patients	95% at 2 years

Eichinger, Josef & R Miller, Lindsay & Hartshorn, Timothy & Li, Xinning & J.P. Warner, Jon & D Higgins, Laurence. (2015). Evaluation of satisfaction and durability after hemiarthroplasty and total shoulder arthroplasty in a cohort of patients aged 50 years or younger: An analysis of discordance of patient satisfaction and implant survival. *Journal of shoulder and elbow surgery*. American Shoulder and Elbow Surgeons. 25, 10, 10161 (see 2015:09:028).
Petit, M., Euler, S. A., Doman, G. J., Greenspoon, J. A., Horan, M. P., Kathhagen, J. C., & Milet, P. J. (2016). Predictors for satisfaction after anatomic total shoulder arthroplasty for idiopathic glenohumeral osteoarthritis. *Archives of Orthopaedic and Trauma Surgery*, 136(6), 755-762.
Favard, L., Leveigne, C., Nerot, C. et al., Reverse Prosthesis in arthroplasties with cuff tear: Are survivorship and function maintained over time? *Clin Orthop Relat Res* 2011;469:2469-75.
Morris, B. J., Hagler, R. E., Laughlin, M. S., Elkousy, H. A., Gartsman, G. M., & Edwards, T. B. (2015). Workers' compensation claims and outcomes after reverse shoulder arthroplasty. *Journal of Shoulder and Elbow Surgery*, 24(3), 453-459.

Copyright Jodi Gootkin

130

Future of Shoulder Arthroplasty

- Enhancing design of the reverse shoulder components to restore greater external rotation is expected to improve functional outcomes.
- Monitoring long term implications of scapular notching on prosthetic survival is needed.

131

Copyright Jodi Gootkin

Shoulder Arthroplasty

Conclusion

Shoulder arthroplasty has proven to improve joint stability, patient comfort and function. Future advances focus on expanding surgical indications and prosthetic design for enhanced clinical outcomes.

132

Copyright Jodi Gootkin

132

Copyright Innovative Educational Services and Jodi Gootkin. All rights reserved.

Reproduction, reuse, or republication of all or any part of this presentation is strictly prohibited without prior written consent of both Innovative Educational Services and Jodi Gootkin.

1. Normal arthrokinematics of the glenohumeral joint follows the _____ rule.

- A. Convex on Concave
- B. Concave on Convex
- C. Superior on Inferior
- D. Inferior on Superior

133

Copyright Jodi Gootkin

133

2. The articular surface area of the humeral head is approximately _____ times greater than that of the glenoid fossa.

- A. 2
- B. 3
- C. 4
- D. 5

134

Copyright Jodi Gootkin

134

3. Which of the following is NOT commonly treated surgically with a shoulder arthroplasty?

- A. Proximal humerus fracture
- B. Severe glenohumeral osteoarthritis
- C. Irreparable rotator cuff tear
- D. Chronic impingement syndrome

135

Copyright Jodi Gootkin

135

4. Which anatomical structure is replaced in a shoulder hemiarthroplasty?

- A. Humeral head
- B. Glenoid fossa
- C. Acromial-clavicular joint
- D. Coracoid process

136

Copyright Jodi Gootkin

136

5. Which of the following is TRUE regarding a reverse shoulder arthroplasty (RSA)?

- A. The glenoid is concave
- B. The humeral head is concave
- C. The deltoid insertion is relocated to the medial humeral shaft
- D. All of the above

137

Copyright Jodi Gootkin

Shoulder Arthroplasty

6. Which of the following is commonly utilized surgical approach for shoulder arthroplasty?

- A. Latissimus sparing
- B. Posterosuperior
- C. Deltopectoral
- D. Superior Acromial

138

Copyright Jodi Gootkin

138

Copyright Innovative Educational Services and Jodi Gootkin. All rights reserved.

Reproduction, reuse, or republication of all or any part of this presentation is strictly prohibited without prior written consent of both Innovative Educational Services and Jodi Gootkin.

7. Which muscle typically requires additional protection during the early stages of arthroplasty rehabilitation?

- A. Subscapularis
- B. Deltoid
- C. Supraspinatus
- D. Infraspinatus

139

Copyright Jodi Gootkin

139

8. What is the most common long-term complication associated with anatomic total shoulder arthroplasty (TSA)?

- A. Humeral shaft fracture
- B. Supraspinatus avulsion
- C. Radial nerve neuropathy
- D. Loosening of the glenoid component

140

Copyright Jodi Gootkin

140

9. Approximately, how much functional AROM should a patient have at therapeutic discharge?

- A. 30-60 degrees flexion; 15 degrees ER
- B. 60-90 degrees flexion; 30 degrees ER
- C. 80-120 degrees flexion; 30 degrees ER
- D. 120-150 degrees flexion; 60 degrees ER

141

Copyright Jodi Gootkin

141

10. Which surgical intervention generally produces superior functional outcomes as it relates to return to sport?

- A. Hemiarthroplasty
- B. Total Shoulder Arthroplasty (TSA)
- C. Reverse Shoulder Arthroplasty (RSA)
- D. Outcomes for all are equal

142

Copyright Jodi Gootkin

142

Shoulder Arthroplasty

Copyright Innovative Educational Services and Jodi Gootkin. All rights reserved.

Reproduction, reuse, or republication of all or any part of this presentation is strictly prohibited without prior written consent of both Innovative Educational Services and Jodi Gootkin.

Shoulder Arthroplasty

References

- Ahmed, Abdulaziz F., et al. "The safety of outpatient total shoulder arthroplasty: a systematic review and meta-analysis." *International Orthopaedics* 45 (2021): 697-710.
- Allahabadi, S., Cheung, E. C., Hodax, J. D., Feeley, B. T., Ma, C. B., & Lansdown, D. A. (2021). Outpatient shoulder arthroplasty—a systematic review. *Journal of Shoulder and Elbow Arthroplasty*, 5, 24715492211028025.
- Burden, E. G., Batten, T. J., Smith, C. D., & Evans, J. P. (2021). Reverse total shoulder arthroplasty: a systematic review and meta-analysis of complications and patient outcomes dependent on prosthesis design. *The bone & joint journal*, 103(5), 813-821.
- Calkins, T. E., Mosher, Z. A., Throckmorton, T. W., & Brolin, T. J. (2022). Safety and cost effectiveness of outpatient total shoulder arthroplasty: a systematic review. *JAAOS-Journal of the American Academy of Orthopaedic Surgeons*, 30(2), e233-e241.
- Cimino, A. M., Hawkins, J. K., McGwin, G., Brabston, E. W., Ponce, B. A., & Momaya, A. M. (2021). Is outpatient shoulder arthroplasty safe? A systematic review and meta-analysis. *Journal of Shoulder and Elbow Surgery*, 30(8), 1968-1976.
- Davies, A., Lloyd, T., Sabharwal, S., Liddle, A. D., & Reilly, P. (2023). Anatomical shoulder replacements in young patients: A systematic review and meta-analysis. *Shoulder & Elbow*, 15(1_suppl), 4-14.
- Davies, A., Selmi, H., Sabharwal, S., Vella-Baldacchino, M., Liddle, A. D., & Reilly, P. (2022). Revision shoulder hemiarthroplasty and total shoulder arthroplasty a systematic review and meta-analysis. *Journal of Shoulder and Elbow Arthroplasty*, 6, 24715492221095991.
- De Fine, M., Sartori, M., Giavaresi, G., De Filippis, R., Agrò, G., Cialdella, S., ... & Pignatti, G. (2022). The role of subscapularis repair following reverse shoulder arthroplasty: systematic review and meta-analysis. *Archives of Orthopaedic and Trauma Surgery*, 1-10.
- Hesseling, B., Prinsze, N., Jamaludin, F., Perry, S. I., Eygendaal, D., Mathijssen, N. M., & Snoeker, B. A. (2024). Patient-related prognostic factors for function and pain after shoulder arthroplasty: a systematic review. *Systematic Reviews*, 13(1), 286.
- Huddleston, H. P., Mehta, N., Polce, E. M., Williams, B. T., Fu, M. C., Yanke, A. B., & Verma, N. N. (2021). Complication rates and outcomes after outpatient shoulder arthroplasty: a systematic review. *JSES international*, 5(3), 413-423.
- Kostretzis, L., Konstantinou, P., Pinto, I., Shahin, M., Ditsios, K., & Papadopoulos, P. (2021). Stemless reverse total shoulder arthroplasty: a systematic review of contemporary literature. *Musculoskeletal Surgery*, 105(3), 209-224.
- Küffer, J., Taha, M. E., Hoffmeyer, P., & Cunningham, G. (2021). Return to sport after shoulder arthroplasty: a systematic review. *EFORT Open Reviews*, 6(9), 771-778.
- Leafblad, N., Asghar, E., & Tashjian, R. Z. (2022). Innovations in shoulder arthroplasty. *Journal of Clinical Medicine*, 11(10), 2799.
- Lu, Z., Nazari, G., Almeida, P. H., Pontes, T., & MacDermid, J. C. (2022). The clinical outcome of physiotherapy after reversed shoulder arthroplasty: a systematic review. *Disability and Rehabilitation*, 44(23), 6997-7008.
- Mirghaderi, P., Azarboo, A., Ghaseminejad-Raeini, A., Eshraghi, N., Vahedi, H., & Namdari, S. (2024). Shoulder arthroplasty after previous nonarthroplasty surgery: a systematic review and meta-analysis of clinical outcomes and complications. *JBJS reviews*, 12(3), e23.
- O'Donnell, E. A., Fury, M. S., Maier, S. P., Bernstein, D. N., Carrier, R. E., & Warner, J. J. (2021). Outpatient shoulder arthroplasty patient selection, patient experience, and cost analyses: a systematic review. *JBJS reviews*, 9(11), e20.

- Otworowski, M., Grzelecki, D., Starszak, K., Boszczyk, A., Piorunek, M., & Kordasiewicz, B. (2023). Periprosthetic fractures after shoulder arthroplasty: a systematic review. *EFORT Open Reviews*, 8(10), 748-758.
- Polascik, B. A., Chopra, A., Hurley, E. T., Levin, J. M., Rodriguez, K., Stauffer, T. P., ... & Klifto, C. S. (2023). Outcomes after bilateral shoulder arthroplasty: a systematic review. *Journal of Shoulder and Elbow Surgery*, 32(4), 861-871.
- Ravi, V., Murphy, R. J., Moverley, R., Derias, M., & Phadnis, J. (2021). Outcome and complications following revision shoulder arthroplasty: a systematic review and meta-analysis. *Bone & Joint Open*, 2(8), 618-630.
- Sandler, A. B., Scanaliato, J. P., Narimissaei, D., McDaniel, L. E., Dunn, J. C., & Parnes, N. (2022). The transition to outpatient shoulder arthroplasty: a systematic review. *Journal of shoulder and elbow surgery*, 31(7), e315-e331.
- Seok, H. G., Park, J. J., & Park, S. G. (2022). Risk factors for periprosthetic joint infection after shoulder arthroplasty: systematic review and meta-analysis. *Journal of Clinical Medicine*, 11(14), 4245.
- Su, F., Nuthalapati, P., Feeley, B. T., & Lansdown, D. A. (2023). Outcomes of anatomic and reverse total shoulder arthroplasty in patients over the age of 70: a systematic review. *JSES Reviews, Reports, and Techniques*, 3(2), 181-188.
- Syros, A., Perez, O. F., Luxenburg, D., Cohen, J. L., Swonger, R., & Huntley, S. (2022). The most influential studies concerning revision shoulder arthroplasty research. *Journal of Orthopaedics*, 34, 349
- Vajapey, S. P., Contreras, E. S., Neviaser, A. S., Bishop, J. Y., & Cvetanovich, G. L. (2021). Outpatient total shoulder arthroplasty: a systematic review evaluating outcomes and cost-effectiveness. *JBJS reviews*, 9(5), e20.
- Willems, J. I., Hoffmann, J., Sierevelt, I. N., van den Bekerom, M. P., Alta, T. D., & van Noort, A. (2021). Results of stemless shoulder arthroplasty: a systematic review and meta-analysis. *EFORT open reviews*, 6(1), 35-4